



Oculopharyngeal Muscular Dystrophy

Synonym: OPMD

Capucine Trollet, PhD,¹ Alexis Boulinguez, PhD,¹ Fanny Roth, PhD,¹ Tanya Stojkovic, MD,² Gillian Butler-Browne, PhD,¹ Teresinha Evangelista, MD,³ Jean Lacau St Guily, MD,¹ and Pascale Richard, PharmD, PhD⁴

Created: March 8, 2001; Updated: October 22, 2020.

Summary

Clinical characteristics

Oculopharyngeal muscular dystrophy (OPMD) is characterized by ptosis and dysphagia due to selective involvement of the muscles of the eyelids and pharynx, respectively. For the vast majority of individuals with typical OPMD, the mean age of onset of ptosis is usually 48 years and of dysphagia 50 years; in 5%-10% of individuals with severe OPMD, onset of ptosis and dysphagia occur before age 45 years and is associated with lower limb girdle weakness starting around age 60 years. Swallowing difficulties, which determine prognosis, increase the risk for potentially life-threatening aspiration pneumonia and poor nutrition. Other manifestations as the disease progresses can include limitation of upward gaze, tongue atrophy and weakness, chewing difficulties, wet voice, facial muscle weakness, axial muscle weakness, and proximal limb girdle weakness predominantly in lower limbs. Some individuals with severe involvement will eventually need a wheelchair. Neuropsychological tests have shown altered scores in executive functions in some.

Diagnosis/testing

The diagnosis of OPMD is established in a proband with a suggestive phenotype in whom either of the following genetic findings are identified: a heterozygous GCN trinucleotide repeat expansion of 11 to 18 repeats in the first exon of *PABPN1* (~90% of affected individuals) or biallelic GCN trinucleotide repeat expansions that are either compound heterozygous (GCN[11] with a second expanded allele) or homozygous (GCN[11]+[11], GCN[12]+[12], GCN[13]+[13], etc.) (~10% of affected individuals).

Author Affiliations: 1 INSERM, Sorbonne Université, Centre de Recherche en Myologie, Paris, France; Email: capucine.trollet@upmc.fr; Email: alexis.boulinguez@inserm.fr; Email: fanny.roth0106@gmail.com; Email: gillian.butler-browne@upmc.fr; Email: jean.lacau@aphp.fr. 2 APHP, Sorbonne Université, Institut de Myologie, Centre de référence des maladies neuromusculaires, Hôpital Pitié-Salpêtrière, Paris, France; Email: stojkovic.tanya@aphp.fr. 3 Unité de Morphologie Neuromusculaire, Institut de Myologie, Paris, France; Email: t.evangelista@institut-myologie.org. 4 APHP, Sorbonne Université, ICAN, Functional Unit of Molecular and Cellular Cardiogenetics and Myogenetics, Paris, France; Email: pascale.richard@aphp.fr.

Management

Treatment of manifestations: Treatment for ptosis may include blepharoplasty by either resection of the levator palpebrae aponeurosis or frontal suspension of the eyelids. The initial treatment for dysphagia is dietary modification; surgical intervention for dysphagia should be considered when symptomatic dysphagia has a significant impact on quality of life. Physical and occupational therapy are encouraged; assistive devices may be necessary to prevent falls and assist with walking and mobility. Neuropsychological support as needed.

Surveillance: Routine evaluation of: neuromuscular and oculomotor involvement; dysphagia including nutritional status and diet; respiratory function given the increased risk for both aspiration and nocturnal hypoventilation; and cognitive function including development of psychiatric symptoms.

Genetic counseling

OPMD is inherited in an autosomal dominant manner. The risk to sibs of a proband depends on the genetic status of the parents of the proband:

- If one parent of a proband is heterozygous for a GCN repeat expansion in *PABPN1* (GCN[11_18]+ [10]) and the other parent has two normal alleles (GCN[10]+[10]), the risk to the sibs of inheriting a GCN repeat expansion is 50%.
- If both parents of the proband are heterozygous for a GCN repeat expansion, sibs have a 25% risk of inheriting two GCN repeat expansions and a 50% risk of inheriting one GCN repeat expansion.
- If one parent of the proband has biallelic GCN repeat expansions and the other parent has two normal alleles, all sibs will inherit a GCN repeat expansion.
- If one parent of the proband has biallelic GCN repeat expansions and the other parent is heterozygous for a GCN repeat expansion, sibs of the proband have a 50% risk of inheriting biallelic GCN repeat expansions and 50% risk of inheriting one GCN repeat expansion.

Sibs who inherit either one or two GCN repeat expansions will be affected.

Diagnosis

Suggestive Findings

Oculopharyngeal muscular dystrophy (OPMD) **should be suspected** in individuals with a mean age of 48 years with the following clinical and neuroimaging findings. Younger age at onset (<30 years) is often observed in longer GCN expansion or in individuals who are compound heterozygous or homozygous for the GCN expansion.

Clinical findings

- **Ptosis**, defined as EITHER a vertical separation of at least one palpebral fissure that measures less than 8 mm at rest OR previous corrective surgery for ptosis
- **Dysphagia**, defined as an increased swallowing time (i.e., >7 seconds when drinking 80 mL of ice-cold water) [Tabor et al 2018, Waito et al 2018].

Note: Proximal muscle weakness (particularly involving pelvic girdle and scapular girdle) may appear later, usually five to ten years after the onset of ptosis.

Whole-body muscle MRI. Fatty involvement of the tongue, soleus, and adductor muscles is very suggestive of OPMD [Alonso-Jimenez et al 2019].

Establishing the Diagnosis

The diagnosis of OPMD is **established** in a proband with suggestive findings and **one of the following** identified by molecular genetic testing (see Table 1) [Jouan et al 2014, Richard et al 2015, Richard et al 2017]:

- A heterozygous GCN trinucleotide repeat expansion of 11 to 18 repeats in the first exon of *PABPN1* (~90% of affected individuals)
- Biallelic GCN trinucleotide repeat expansions that are either compound heterozygous (GCN[11] with a second expanded allele) or homozygous (GCN[11]+[11], GCN[12]+[12], or GCN[13]+[13]) (~10% of affected individuals)

Note: Penetrance of an expanded allele depends on both size and zygosity.

Allele sizes. The N in GCN represents any nucleotide (A/C/G/T). All four possible sequences have been observed in the *PABPN1* complex repeat.

- **Normal alleles** have ten GCN repeats: GCN[10].
- **Expanded alleles** have 11 to 18 GCN repeats: GCN[11_18].

Molecular genetic testing approaches can include a combination of **gene-targeted testing** (single gene testing, i.e., either sequence analysis of *PABPN1* or targeted analysis for *PABPN1* GCN trinucleotide repeats in exon 1, or a multigene panel) and **comprehensive genomic testing** (exome sequencing and genome sequencing).

Gene-targeted testing requires that the clinician determine which gene is likely involved, whereas comprehensive genomic testing does not. Individuals with the distinctive findings described in Suggestive Findings are likely to be diagnosed using gene-targeted testing (see Option 1), whereas those in whom the diagnosis of OPMD has not been considered are more likely to be diagnosed using comprehensive genomic testing (see Option 2).

Option 1

When the phenotypic findings suggest the diagnosis of OPMD, molecular genetic testing approaches can include **single-gene testing** or use of a **multigene panel**:

- **Single-gene testing** can characterize the number of GCN repeats in exon 1 of *PABPN1* either by sequence analysis of *PABPN1* exon 1 or targeted size analysis of exon 1.
- **A multigene panel** that includes *PABPN1* and other genes of interest (see Differential Diagnosis) is most likely to identify the genetic cause of the condition while limiting identification of variants of uncertain significance and pathogenic variants in genes that do not explain the underlying phenotype. Note: (1) The genes included in the panel and the diagnostic sensitivity of the testing used for each gene vary by laboratory and are likely to change over time. (2) Some multigene panels may include genes not associated with the condition discussed in this *GeneReview*. (3) In some laboratories, panel options may include a custom laboratory-designed panel and/or custom phenotype-focused exome analysis that include genes specified by the clinician. (4) Methods used in a panel may include sequence analysis, deletion/duplication analysis, and/or other non-sequencing-based tests.

Note: Due to the high GC content of *PABPN1* exon 1, the GCN repeat and surrounding region may have low coverage in assays based on next-generation sequencing; therefore, when OPMD is suspected, it is appropriate to confirm that the laboratory has determined the *PABPN1* GCN repeat number.

For an introduction to multigene panels click [here](#). More detailed information for clinicians ordering genetic tests can be found [here](#).

Option 2

When the diagnosis of OPMD has not been considered because an individual has atypical phenotypic features, **comprehensive genomic testing** can be the best option as it does not require the clinician to determine which gene is likely involved. **Exome sequencing** is most commonly used; **genome sequencing** is also possible; the short length of pathogenic expanded *PABPN1* alleles permits either methodology.

For an introduction to comprehensive genomic testing click [here](#). More detailed information for clinicians ordering genomic testing can be found [here](#).

Table 1. Molecular Genetic Testing Used in Oculopharyngeal Muscular Dystrophy

Gene ¹	Method	Pathogenic Variant ²	Proportion of Probands with a Pathogenic Variant Detectable by Method
<i>PABPN1</i>	Sequence analysis or targeted analysis for GCN repeat number in exon 1 ³	GCN[11_18] ⁴	>99% ⁵

1. See Table A. Genes and Databases for chromosome locus and protein.

2. See Molecular Genetics for information on variants detected in this gene.

3. Sanger sequencing is typically used to determine GCN repeat length and zygosity; however, due to the sequence and size of the repeat, next-generation sequencing (NGS) or fragment analysis can also be used. (Note that while Sanger sequencing is suitable to determine zygosity in individuals with monoallelic heterozygote expanded variants, when there are biallelic expanded variants, fragment size determination and/or NGS should be added to determine zygosity.)

4. Sanger sequencing or NGS can determine the sequence of the repeat; however, it is not necessary to determine the exact sequence of the repeat in order to establish the diagnosis of OPMD.

5. GCN repeat expansion is the only reported cause of OPMD [Brais et al 1998, Robinson et al 2005, Tondo et al 2012, Shan et al 2014, Goyal et al 2019]. The GCN repeat is complex, with N being either A, T, C, or G.

Muscle Biopsy

Intranuclear inclusions. Previously the diagnosis of OPMD was based on the detection of intranuclear inclusions (INI) on muscle biopsy by electron microscopy. INI are intranuclear tubular filaments with an outer diameter of 8.5 nm, an inner diameter of 3 nm, and a length of about 0.25 μ m; unbranched; and variably oriented. They only occur in muscle nuclei. In inclusion body myositis the inclusions have 15- to 18-nm filaments which can be seen in both nuclei and cytoplasm. Currently muscle biopsy is only warranted in individuals who have suggestive findings, two normal *PABPN1* alleles, and normal molecular genetic testing results for other neurologic disorders that could present similarly (see Differential Diagnosis). The technique routinely used now (based on KCl pretreatment followed by *PABPN1* immunostaining) is estimated to identify INI in 2% to 15% of myonuclei in muscle from an individual with OPMD [Gidaro et al 2013, Galimberti et al 2020].

Histopathology. In addition to INI, biopsies (in both clinically affected and clinically unaffected muscles) from individuals with molecularly confirmed OPMD show dystrophic changes: variation in the diameter of muscle fibers, atrophic angulated muscle fibers, ragged red fibers, and rimmed vacuoles [Tomé & Fardeau 1994, Gidaro et al 2013]. Although rimmed vacuoles may suggest the diagnosis of OPMD, they are not present in all OPMD muscle biopsies [Fukuhara et al 1980]. Likewise, rimmed vacuoles are not specific for OPMD as they have been consistently found in several other muscle diseases (e.g., inclusion body myositis [Askanas & Engel 1995], in which they are much more numerous than in OPMD [Leclerc et al 1993]).

Clinical Characteristics

Clinical Description

Oculopharyngeal muscular dystrophy (OPMD) is characterized by ptosis and dysphagia due to selective involvement of the muscles of the eyelids and pharynx, respectively. Early manifestations of dysphagia include increased time needed to consume a meal and an acquired avoidance of dry foods. The severity of dysphagia is the major determinant of prognosis, as it leads to potentially life-threatening aspiration pneumonia and poor nutrition. Other manifestations, observed as the disease progresses, are limitation of upward gaze, tongue atrophy and weakness, chewing difficulties, wet voice, facial muscle weakness, axial muscle weakness, proximal limb girdle weakness predominantly in lower limbs, and proximal upper extremity weakness (Table 2). Moreover, neuropsychological tests have shown altered scores in executive function compared to controls, which appears to correlate with the larger expansions of *PABPN1* [Dubbioso et al 2012] (see also Genotype-Phenotype Correlations).

In typical OPMD (i.e., 90%-95% of affected individuals), the mean age of onset of ptosis is usually 48 years and dysphagia 50 years. The mean age of onset of lower proximal weakness is 58 years [Brisson et al 2020]. In 333 individuals with a heterozygous (GCN)₁₃ expansion, the median latency before the onset of proximal weakness was seven years (range 0-21 years) after the onset of ptosis and seven years (0-25 years) after the onset of dysphagia [Brisson et al 2020].

Severe OPMD (5%-10% of affected individuals) is characterized by onset of ptosis and dysphagia before age 45 years and incapacitating proximal leg weakness that starts before age 60 years. Some individuals with severe involvement eventually need a wheelchair. See also Table 3.

Although OPMD does not appear to reduce life span, in individuals with heterozygous GCN repeat expansions, quality of life in later years is greatly diminished [Becher et al 2001]. In a report of 333 individuals with the (GCN)₁₃ expansion, the main cause of death was respiratory disease [Brisson et al 2020].

Table 2. Select Features of Oculopharyngeal Muscular Dystrophy

Feature	% of Persons w/Feature	Comment	
Oculomotor involvement	Ptosis	96%-100% ¹	Levator palpebrae muscle
	Limitation of upward gaze	61%	Superior rectus muscle
Dysphagia	96%-100% ¹		
Tongue weakness	82%		
Wet voice	67%	Due to pooling of saliva	
Dysphonia	50% ¹		
Facial muscle weakness	43%	Facial muscles: orbicularis oris, orbicularis oculi, nasalis, levator anguli muscle, masseter muscles	
Proximal lower-extremity weakness	71%-86% ¹	Predominantly hamstrings & glutei	
Proximal upper-extremity weakness	38%		
Fatigue	88% ¹		
Cognitive impairment	Rare, but probably underestimated due to a lack of systematic studies in these patients	<ul style="list-style-type: none"> Altered executive functions (in heterozygotes)² Uninhibited behavior & psychotic disorders in homozygotes for the (GCN)₁₃ expansion³ 	

Table 2. continued from previous page.

Feature	% of Persons w/Feature	Comment
Dropped head	Rare	1 report ⁴

1. Brisson et al [2020]
2. Dubbioso et al [2012]
3. Blumen et al [2009]
4. Garibaldi et al [2015]

Ptosis is always bilateral, but may be asymmetric, at least in the early stage of disease [Brais 2003]. Individuals with severe bilateral ptosis may compensate for visual field limitation with the "astrologist's posture" – retroflexion of the neck and downward gaze combined with contraction of the frontalis muscles [Rüegg et al 2005].

Extraocular muscles may become gradually affected but complete external ophthalmoplegia is rare [Tomé & Fardeau 1994].

Dropped head beginning at age 67 years and associated with dysphagia, hypernasal speech, ptosis, and proximal limb weakness was reported in a woman who was homozygous for the (GCN)11 expansion [Garibaldi et al 2015].

Dysphagia is detected first for solids and later also for liquids. The degenerative dystrophy and progressive onset of fibrosis of the pharyngeal muscles create difficulties in propelling the food bolus in the pharynx. This, together with a decreased relaxation of the cricopharyngeal muscle (the main muscle of the upper esophageal sphincter [UES] located between the pharynx and the esophagus) results in delay of the transfer of the bolus through the UES.

Of note, while in the past dysphagia resulted in poor nutrition usually causing death by starvation, recent progress (especially in the treatment of pharyngeal dysfunction) has improved the quality of life for persons with OPMD.

Chewing and speaking are also frequently affected [Kroon et al 2020].

Limb muscle involvement is symmetric and mainly concerns the pelvic and scapular girdle. Fatty degeneration of the muscles involves the soleus muscles, the hip adductors, and the hamstrings, especially at the onset the semi-membranous and biceps femoralis muscles.

At later stages, the fatty degeneration spreads to the vastus medialis and intermediate muscles, the gastrocnemius, and the peroneus muscles. The sartorius, gracilis, and tibialis muscles are usually conserved for a longer time [Fischmann et al 2011, Gloor et al 2011]. In the upper limbs, the serratus anterior, latissimus dorsi, and subscapularis muscles are the most affected.

MRI studies also show fatty infiltration of the paraspinal muscles in 76% of affected individuals [Alonso-Jimenez et al 2019].

Distal muscle weakness has been described in a Japanese family [Goto et al 1977, Satoyoshi & Kinoshita 1977] and in other ethnic groups [Jaspar et al 1977, Scrimgeour & Mastaglia 1984]. However, distal muscle involvement at onset has not been associated with typical OPMD [Schotland & Rowland 1964, Vita et al 1983]. In some severe forms, whole-body muscle MRI has shown distal involvement of the lower limbs in the late stages of disease [Alonso-Jimenez et al 2019].

Pain and fatigue. A questionnaire-based study of fatigue, pain, and functional impairment in 35 individuals with genetically confirmed OPMD showed that 54% experienced severe fatigue and pain leading to difficulties

with daily living activities and social participation [van der Sluijs et al 2016]. These findings were confirmed in 333 individuals with the (GCN)13 expansion [Brisson et al 2020].

Cognitive impairment. Some individuals have also shown central nervous system involvement [Linoli et al 1991]. Dubbioso et al [2012] described an individual with central nervous system involvement with impaired executive function. Ten persons, with homozygous *PAPBN1* (GCN)13-(GCN)13 expansions had cognitive decline, depression, and psychotic manifestations [Blumen et al 2009].

Other clinical findings

- Reduction in FEV1 (forced expiratory volume in one second) ranging from 23% to 59% of the expected values was observed in 13 individuals with OPMD, none of whom required noninvasive ventilation [Witting et al 2014].
- Sleep apnea, reported rarely, is probably underestimated [Dedrick & Brown 2004].
- Cardiomyopathy or rhythm abnormalities have not been associated with OPMD.
- Although OPMD is considered a primary muscle disorder, there are rare reports of findings suggestive of peripheral nerve involvement including severe depletion of myelinated fibers in endomysial nerve twigs of extraocular, pharyngeal, and lingual muscles [Probst et al 1982, Schober et al 2001] and reports of axonal sensorimotor neuropathies in some affected individuals.

Other laboratory findings

- **Electromyography (EMG)** usually reveals a myopathic pattern especially in weak muscles [Bouchard et al 1997].
- **Serum CK** concentrations elevated two to seven times above the normal value have been reported in individuals with OPMD with severe leg weakness [Barbeau 1996]; however, serum CK concentration is usually normal or up to twice the upper limit of normal [Richard et al 2017].

Genotype-Phenotype Correlations

Variability of age of onset and severity of weakness correlates with GCN repeat size [Brais et al 1998, Richard et al 2017] (see Table 3). The following generalizations can be made:

- In persons with heterozygous repeats, longer repeat length is associated with earlier age of onset.
- In persons with two expanded alleles (either homozygous or compound heterozygous) age of onset is earlier than in individuals with a single (heterozygous) expanded allele.
- The most severe disease is associated two expanded alleles.

Table 3. Oculopharyngeal Muscular Dystrophy: Genotype-Phenotype Correlations

Genotype	Allele Sizes ¹	# of Persons	Mean Age at Diagnosis \pm SD	Phenotype		
				Ptosis	Dysphagia	Proximal weakness
Heterozygous	10/11	6	72 \pm 11 yrs	\pm	+	Late
	10/12	33	73 \pm 10	\pm	+	Late
	10/13	176	64 \pm 10	+	+	Late
	10/14	55	61 \pm 8	+	+	Late
	10/15	56	60 \pm 10	+	+ /+++	Yes/wheelchair
	10/16	4	56 \pm 6	+	++	Yes
	10/17	2	53 \pm 4	++	+++	Yes
Compound heterozygous	11/12	9	58 \pm 11	+	+	Yes

Table 3. continued from previous page.

Genotype	Allele Sizes ¹	# of Persons	Mean Age at Diagnosis ±SD	Phenotype		
				Ptosis	Dysphagia	Proximal weakness
Homozygous	11/11	9	73±7	+	+	Yes
	12/12	2	49±1	++	++	Yes
	13/13	2	37±9	+++	++	Yes

Adapted from Richard et al [2017]

1. Allele sizes are abbreviated. For example, 10/11 = GCN[10]+[11]

Penetrance

Decade-specific cumulative penetrance for individuals with a heterozygous GCN[13] pathogenic variant is [Brais et al 1997, Richard et al 2017]:

- Age <40 years. 1%
- Age 40-49 years. 6%
- Age 50-59 years. 31%
- Age 60-69 years. 63%
- Age >69 years. 99%

Thus, OPMD resulting from GCN[13] heterozygosity is fully penetrant after age 70 years.

Anticipation

Anticipation is not observed. The *PABPN1* GCN repeat is mitotically and meiotically stable: expansion or contraction of the repeat in meiosis is rare. The estimated mutation (expansion/contraction) rate for a heterozygous ([GCN12_17]) allele is approximately 1:500 meiosis [Brais et al 1998].

Nomenclature

Historical numbering of the *PABPN1* repeat GCN expansion is described in Molecular Genetics (see ***PABPN1*-specific laboratory technical considerations**).

Prevalence

The prevalence of OPMD has been estimated at 1:100,000 in France, 1:1000 in the French-Canadian population of the province of Quebec, and 1:600 among Bukhara Jews living in Israel [Brais et al 1995, Blumen et al 1997, Brunet et al 1997]. A few French-Canadians and members of the genetically isolated population of Bukhara Jews living in Israel [Blumen et al 1999] are homozygous for the expanded alleles GCN[13].

In the United States, the majority of affected individuals are of French-Canadian extraction, though a large number are also of other backgrounds, including Ashkenazi Jewish [Victor et al 1962], and Spanish American in Texas [Becher et al 2001] and California [Grewal et al 1999].

OPMD has been identified in individuals from more than 30 countries.

The frequency of GCN[11] alleles is 1% to 2% of North American, European, and Japanese populations.

Genetically Related (Allelic) Disorders

No phenotypes other than those discussed in this *GeneReview* are known to be associated with heterozygous or biallelic variants in *PABPN1*.

Differential Diagnosis

The differential diagnosis of oculopharyngeal muscular dystrophy (OPMD) should include myasthenia gravis and other late-onset neuromuscular diseases characterized by swallowing difficulties and/or ptosis. Disorders in the differential diagnosis with a known genetic etiology are summarized in Table 4.

Table 4. Genes of Interest in the Differential Diagnosis of Oculopharyngeal Muscular Dystrophy

Gene(s)	Disorder	MOI	Swallowing Difficulties	Ptosis	Other Key Features / Comments
<i>CNBP</i>	Myotonic dystrophy type 2	AD	Gastrointestinal complications common; can incl dysphagia	Not present	Caused by a CCTG tetranucleotide repeat expansion
<i>DCTN1</i>	Distal hereditary motor neuropathy (See CMT Hereditary Neuropathy Overview.)	AD	Vocal cord palsy in children	Not present	Distal motor weakness in children
	ALS (See ALS Overview.)	AD AR	Bulbar involvement: swallowing difficulties, dysarthria	Not present	ALS variant (age at onset >46 yrs); arm, leg, & limb weakness, bulbar involvement
<i>DMPK</i>	Myotonic dystrophy type 1	AD	Smooth muscle involvement may produce dysphagia.	Present	Caused by a CTG trinucleotide repeat expansion
<i>FOXL2</i>	Blepharophimosis, ptosis, & epicanthus inversus	AD ¹	Not present	Usually congenital & always assoc w/ epicanthus inversus	
<i>KIF21A</i> <i>PHOX2A</i> <i>TUBB2B</i> <i>TUBB3</i>	Congenital fibrosis of the extraocular muscles	AD AR	Not present	Congenital	
<i>GIPC1</i> <i>LRP12</i>	Oculopharyngodistal myopathy ² (OMIM PS164310)	AD	Present	Present	<ul style="list-style-type: none"> • Distal weakness • Earlier onset (3rd decade) than in OPMD • Caused by a CGG trinucleotide repeat expansion³
<i>MATR3</i>	ALS (See ALS Overview.)	AD	Vocal cord & pharyngeal dysfunction	Not present	Distal myopathy
<i>POLG</i> <i>RRM2B</i> <i>SLC25A4</i> <i>TK2</i> <i>TWINK</i>	Mitochondrial DNA maintenance defects presenting w/ophthalmoplegia (See also Mitochondrial Disorders Overview.)	AD AR	Present	Present, ophthalmoplegia	Mild proximal myopathy
<i>SLC5A7</i>	Distal hereditary motor neuropathy type VII (OMIM 158580)	AD	Vocal cord & pharyngeal weakness	Not present	Distal hereditary motor neuropathy

Table 4. continued from previous page.

Gene(s)	Disorder	MOI	Swallowing Difficulties	Ptosis	Other Key Features / Comments
<i>TYMP</i>	Mitochondrial neurogastrointestinal encephalopathy disease	AR	Dysphagia	Present, bilateral	Demyelinating sensorimotor neuropathy assoc w/ leukodystrophy & pseudointestinal obstruction

AD = autosomal dominant; ALS = amyotrophic lateral sclerosis; AR = autosomal recessive; CMT = Charcot-Marie-Tooth; MOI = mode of inheritance; OPMD = oculopharyngeal muscular dystrophy

1. Blepharophimosis, ptosis, and epicanthus inversus syndrome is usually inherited in an autosomal dominant manner; autosomal recessive inheritance has been reported in one consanguineous family.

2. Deng et al [2020]

3. Ishiura et al [2019]

Acquired disorders and disorders of unknown genetic cause

- **Myasthenia gravis** (OMIM 254200). The absence of family history and the fluctuation of symptoms in myasthenia gravis usually distinguish the two conditions. Perform electromyography with repetitive nerve stimulation test at 3Hz. Neostigmine testing and antibodies to the acetylcholine receptor and MusK can help to confirm the diagnosis of myasthenia gravis.
- **Inclusion body myositis, polymyositis, and progressive bulbar palsy.** These conditions do not have ptosis. However, since some late-onset forms of OPMD may manifest with dysphagia and mild ptosis, differential diagnosis should be considered.

Management

Evaluations Following Initial Diagnosis

To establish the extent of disease and needs of an individual diagnosed with oculopharyngeal muscular dystrophy (OPMD), the evaluations summarized in Table 5 (if not performed as part of the evaluation that led to the diagnosis) are recommended.

Table 5. Recommended Evaluations Following Initial Diagnosis in Individuals with Oculopharyngeal Muscular Dystrophy

System/Concern	Evaluation	Comment
Neuromuscular involvement	Neuromuscular examination by neurologist	To determine: <ul style="list-style-type: none"> • Overall disease progression • Presence (& severity) of proximal weakness • Presence or absence of any other neurologic findings
	Refer to neuromuscular clinic (OT/PT/rehabilitation specialist).	To assess gross motor & fine motor skills, gait, ambulation, need for adaptive devices, PT, OT
Oculomotor involvement	Complete ophthalmologic examination	<ul style="list-style-type: none"> • Assess best corrected visual acuity • Determine presence (& severity) of ptosis & range of extraocular movement. • Surgery is an option when severe ptosis impairs vision.

Table 5. continued from previous page.

System/Concern	Evaluation	Comment
Respiratory function ¹	<ul style="list-style-type: none"> • Pulmonary function tests • Chest CT 	Perform in both symptomatic & asymptomatic persons as baseline.
	Nocturnal polysomnography	For those w/loud snoring, morning headaches, sleepiness, or other suggestive symptoms
Dysphagia	Swallowing assessment by otolaryngologist &/or speech therapist ²	<ul style="list-style-type: none"> • History of swallowing difficulties • The drink test³ • VESS⁴ or VFSS⁵ • Nutritional status & diet
Facial muscle weakness	Refer to neuromuscular clinic (OT/PT/ rehabilitation specialist).	<ul style="list-style-type: none"> • Assess psychological impact. • In some patients: refer to psychologist as needed.
Cognitive impairment	Assess for cognitive dysfunction.	Refer to psychiatrist, psychologist, neuropsychologist as needed.
Pain & fatigue	Perform evals recommended by van der Sluijs et al [2016].	Incl SIP-136, CIS, MPQ, SCL90, & BDI-PC
Genetic counseling	By genetics professionals ⁶	To inform patients & their families re nature, MOI, & implications of OPMD in order to facilitate medical & personal decision making
Family support/ resources	Assess: <ul style="list-style-type: none"> • Use of community or online resources; • Need for social work involvement for caregiver support. 	

BDI-PC = Beck's Depression Inventory of Primary Care; CIS = Checklist Individual Strength; MPQ = McGill's Pain Questionnaire; OT = occupational therapy; PT = physical therapy; SCL90 = Symptom Checklist 90; SIP-136 = Sickness Impact Profile; MOI = mode of inheritance; VESS = videoendoscopic swallowing study; VFSS = videofluoroscopic swallowing study

1. Shahrzaila et al [2006]

2. Questionnaires used to evaluate the degree of dysphagia and quality of life consequences include the DHI [Silbergleit et al 2012], McHorney score [McHorney et al 2002], the Salassa grade [Salassa 1999]. See also Patel et al [2017], Audag et al [2019], Kroon et al [2020].

3. The drink test, a global quantitative functional evaluation of swallowing, is abnormal when it takes longer than seven seconds to drink 80 mL of ice-cold water [Bouchard et al 1992, Brais et al 1995, Witting et al 2014, Tabor et al 2018, Waito et al 2018].

4. VESS gives indirect signs of upper esophageal sphincter (UES) dysfunction.

5. VFSS gives a direct evaluation of the UES using radiopaque barite in the tracheobronchial tree [Dodds et al 1990, Langmore et al 1991, St Guily et al 1995, Périé et al 1998].

6. Medical geneticist, certified genetic counselor, or certified advanced genetic nurse

Treatment of Manifestations

Ptosis. Surgery is recommended when ptosis interferes with vision or appears to cause cervical pain secondary to constant dorsiflexion of the neck. The two types of blepharoplasty used to correct the ptosis are resection of the levator palpebrae aponeurosis and frontal suspension of the eyelids [Codère 1993].

- Resection of the aponeurosis is easily done, but usually needs to be repeated once or twice [Rodrigue & Molgat 1997].
- Frontal suspension of the eyelids uses a thread of muscle fascia as a sling; the fascia is inserted through the tarsal plate of the upper eyelid and the ends are attached in the frontalis muscle, which is relatively

preserved in OPMD [Codère 1993]. The major advantage of frontal suspension of the eyelids is that it is permanent; however, the procedure requires general anesthesia.

Dysphagia

- Food should be cut into small pieces.
- Although no controlled trials have been performed [Hill et al 2004], surgical intervention for dysphagia should be considered when symptomatic dysphagia has a significant impact on quality of life [Duranceau et al 1983, St Guily et al 1995, Périé et al 1997, Coiffier et al 2006].
- Cricopharyngeal myotomy, consisting of extramucosal section of the cricopharyngeal muscle that improves swallowing through the upper esophageal sphincter [Montgomery & Lynch 1971, Duranceau et al 1980, St Guily et al 1994, St Guily et al 1995, Duranceau 1997, Gómez-Torres et al 2012], is easily performed through open approach and immediately improves symptoms in most cases [Duranceau et al 1983]; however, in a high proportion of patients progressive dysphagia may recur within a few years [Coiffier et al 2006]. An endoscopic approach may be an alternative approach to open surgery in cricopharyngeal myotomy, with better results than botox injection [Schneider et al 1994, Restivo et al 2000].
- Cricopharyngeal dilation is an alternative to cricopharyngeal myotomy [Mathieu et al 1997]. Repeated cricopharyngeal dilation is a safe, effective, well-tolerated, and long-lasting treatment for dysphagia in OPMD [Manjaly et al 2012].
- In social settings involving food consumption, affected individuals should either avoid eating or choose foods that are easy to swallow.

Limb muscle weakness. Physiotherapy and occupational therapy is encouraged in patients; Canes and walkers may be necessary in patients with walking difficulties to avoid falls. Severe forms of OPMD with advanced stages of lower limb weakness may require a wheelchair [Brisson et al 2020].

Cognitive impairment. A systematic neuropsychological evaluation may be proposed to patients with OPMD and is needed to obtain a better understanding of this issue. A multicentric neuropsychological and psychological evaluation may be considered.

Other. The major complications of OPMD are aspiration pneumonia, weight loss, and social withdrawal because of frequent choking while eating. To reduce the risk of these complications:

- Annual flu vaccination is recommended for elderly affected individuals;
- Consultation should be sought promptly for a productive cough because of the increased risk for lung abscesses;
- Dietary supplements should be added if weight loss is significant.

General anesthesia is not contraindicated, although individuals with OPMD may respond differently to certain anesthetics [Caron et al 2005].

Surveillance

Table 6. Recommended Surveillance for Individuals with Oculopharyngeal Muscular Dystrophy

System/Concern	Evaluation	Frequency
Neuromuscular involvement	Neurologic exam to determine overall disease progression & presence of new findings	Per treating neurologist
	Neuromuscular clinic (OT/PT/rehabilitation specialist) assessment of mobility/activities of daily living	Annually

Table 6. continued from previous page.

System/Concern	Evaluation	Frequency
Oculomotor involvement	Routine ophthalmologic eval to determine if ptosis interferes w/driving or is assoc w/neck pain, &/or if eyelids cover >50% of the pupil (findings that could prompt consideration of surgical intervention)	Annually
Respiratory function	Pulmonary function tests	<ul style="list-style-type: none"> • Patients w/known pulmonary disease: per treating pulmonologist • Patients w/o known pulmonary disease: annually
	Nocturnal oximetry or polysomnography sleep study	<ul style="list-style-type: none"> • Patients known to have nocturnal hypoventilation: per treating pulmonologist • Patients w/o known nocturnal hypoventilation: every 2 yrs
Dysphagia	Reevaluate: <ul style="list-style-type: none"> • For functional signs of dysphagia using VESS &/or VFSS; • Nutrition status & diet. 	Annually
Cognitive impairment	Evaluate mood, signs of psychosis, cognitive complaints to identify need for pharmacologic & psychotherapeutic interventions.	Per symptom progression & development of psychiatric symptoms
Social	Family support & resources	Assess need for: <ul style="list-style-type: none"> • Use of community or online resources such as patient advocacy groups; • Social work involvement for caregiver support.

OT = occupational therapist; PT = physical therapist; VESS = videoendoscopic swallowing study; VFSS = videofluoroscopic swallowing study

Evaluation of Relatives at Risk

See Genetic Counseling for issues related to testing of at-risk relatives for genetic counseling purposes.

Therapies Under Investigation

Several therapeutic strategies, developed and tested in OPMD models (mammalian cells, nematode, drosophila, mouse) are currently under investigation [Harish et al 2015]. The majority of them are pharmacologic approaches to reduce cell toxicity [Wang et al 2005, Abu-Baker et al 2013, Abu-Baker et al 2018] and/or reduce PABPN1 aggregation. Indeed, reducing PABPN1 aggregation (with drugs such as doxycycline or trehalose) with intrabodies or chaperone expression consistently enhanced cell survival in cell models of OPMD [Bao et al 2002, Bao et al 2004, Abu-Baker et al 2005, Verheesen et al 2006] and improved muscle weakness in both mouse and *Drosophila* OPMD models [Davies et al 2005, Davies et al 2006, Chartier et al 2009, Barbezier et al 2011, Malerba et al 2019b]. These studies suggest that therapeutic trials in persons with OPMD are possible given that some of the tested molecules have already been given to humans.

Gene replacement strategies (knockdown of mutated *PABPN1* and replacement with a functional *PABPN1*) have also been developed and tested in OPMD models using AAV vectors [Malerba et al 2017, Malerba et al 2019a] or RNA (hammerhead ribozymes/miRNA) [Abu-Baker et al 2019]. Benitec BioPharma received the orphan drug

designation for the AAV-based gene therapy product and is now conducting preclinical studies with the aim of a future clinical trial.

A few clinical trials on therapeutic strategies have already been performed on OPMD:

- An autologous cell transplantation clinical Phase I/IIa study ([NCT00773227](#)) has been conducted with safety and cell-dose efficacy results [Périé et al 2014]. Twelve individuals were initially included and published; 16 were subsequently added; their results have not yet been published.
- Trehalose has now been tested in a clinical setting in persons with OPMD (Bioblast Biopharma; HOPEMD; [NCT02015481](#)) with improvement in dysphagia and muscle function; the effect on the intranuclear inclusions observed in muscle biopsies have not yet been reported [Argov et al 2016].

Search [ClinicalTrials.gov](#) in the US and [EU Clinical Trials Register](#) in Europe for access to information on clinical studies for a wide range of diseases and conditions.

Genetic Counseling

Genetic counseling is the process of providing individuals and families with information on the nature, mode(s) of inheritance, and implications of genetic disorders to help them make informed medical and personal decisions. The following section deals with genetic risk assessment and the use of family history and genetic testing to clarify genetic status for family members; it is not meant to address all personal, cultural, or ethical issues that may arise or to substitute for consultation with a genetics professional. —ED.

Mode of Inheritance

Oculopharyngeal muscular dystrophy (OPMD) is inherited in an autosomal dominant manner. The risk to family members depends on whether OPMD in the family is caused by a heterozygous *PABPN1* GCN trinucleotide repeat expansion of 11 to 18 repeats or by biallelic *PABPN1* GCN repeat expansions.

Risk to Family Members – Proband with a Heterozygous GCN Repeat Expansion

Parents of a proband

- Most individuals with a heterozygous GCN repeat expansion in *PABPN1* have an affected parent.
- Molecular genetic testing is recommended for the parents of a proband, regardless of family history, in order to confirm their genetic status and to allow reliable recurrence risk counseling.

Note: A parent who is heterozygous for the GCN[11] repeat expansion may have been previously unrecognized, presenting only mild OPMD. See Table 3.

- If the GCN repeat expansion identified in the proband is not identified in either parent, the following possibilities should be considered:
 - The proband has a *de novo* GCN repeat expansion. Note: A pathogenic variant is reported as "*de novo*" if: (1) the pathogenic variant found in the proband is not detected in parental DNA; and (2) parental identity testing has confirmed biological maternity and paternity. If parental identity testing is not performed, the variant is reported as "assumed *de novo*" [Richards et al 2015].
 - The proband inherited a GCN repeat expansions from a parent with germline (or somatic and germline) mosaicism. Note: Testing of parental leukocyte DNA may not detect all instances of somatic mosaicism.

- Although most individuals with a heterozygous GCN repeat expansion have an affected parent, the family history may appear to be negative because of failure to recognize the disorder in family members, early death of the parent before the onset of symptoms, or late onset of the disease in the affected parent. Therefore, an apparently negative family history cannot be confirmed unless molecular genetic testing has demonstrated that neither parent has a GCN repeat expansion.

Sibs of a proband. The risk to the sibs of a proband depends on the genetic status of the proband's parents:

- If one parent of the proband is heterozygous for a GCN repeat expansion and the other parent has two normal (GCN[10]) alleles, the risk to the sibs of inheriting a GCN repeat expansion is 50%.
- If both parents of the proband are heterozygous for a GCN repeat expansion, sibs have a 25% risk of inheriting two GCN repeat expansions and a 50% risk of inheriting one GCN repeat expansion.
- If one parent of the proband has biallelic GCN repeat expansions and the other parent has two normal alleles, all sibs will inherit a GCN repeat expansion.
- Sibs who inherit either one or two GCN repeat expansions will be affected. Age of onset and severity of weakness correlate with GCN repeat length and zygosity (i.e., dosage of GCN repeat expansions). See Genotype-Phenotype Correlations and Penetrance.
- If the GCN repeat expansion identified in the proband cannot be detected in the leukocyte DNA of either parent, the recurrence risk to sibs is estimated to be 1% because of the theoretic possibility of parental germline mosaicism [Rahbari et al 2016].
- If the parents have not been tested for the GCN repeat expansion identified in the proband but are clinically unaffected, sibs are still presumed to be at increased risk for OPMD because of the possibility of late onset in a heterozygous parent or the theoretic possibility of parental germline mosaicism.

Offspring of a proband

- Unless an individual who is heterozygous for a GCN repeat expansion has children with an individual who has heterozygous or biallelic GCN repeat expansions, the individual's offspring have a 50% chance of inheriting the GCN repeat expansion.
- The likelihood that the reproductive partner of a proband also has heterozygous or biallelic GCN repeat expansions is higher in individuals of French-Canadian extraction and in Bukhara Jews living in Israel (see Prevalence).

Other family members. The risk to other family members depends on the genetic status of the proband's parents: if a parent has a heterozygous GCN repeat expansion, the parent's family members may be at risk.

Risk to Family Members – Proband with Biallelic GCN Repeat Expansions

Parents of a proband

- Both parents of an individual with biallelic GCN repeat expansions are typically heterozygous for a GCN repeat expansion. In rare instances, one parent is heterozygous and the other parent has biallelic GCN repeat expansions.
- The parents of an individual with biallelic GCN repeat expansions may or may not have manifestations of OPMD depending on the length of their respective GCN repeat expansions. Note: A parent who is heterozygous for the GCN[11] repeat expansion may have been previously unrecognized, presenting only mild OPMD (see Table 3 and Penetrance).
- Molecular genetic testing is recommended for the parents of a proband to confirm the genetic status of each parent and to allow reliable recurrence risk assessment.

Sibs of a proband

- If both parents of the proband are heterozygous for a GCN repeat expansion, sibs of the proband have a 25% risk of inheriting two GCN repeat expansions and a 50% risk of inheriting one GCN repeat expansion.
- If one parent of the proband has biallelic GCN repeat expansions and the other parent is heterozygous for a GCN repeat expansion, sibs of the proband have a 50% risk of inheriting biallelic GCN repeat expansions and 50% risk of inheriting one GCN repeat expansion.
- Sibs of the proband who inherit either one or two GCN repeat expansions will be affected. Age of onset and severity of weakness correlate with GCN repeat length and zygosity (i.e., dosage of GCN repeat expansions). See Table 3 and Penetrance.

Offspring of a proband. Unless an individual with biallelic GCN repeat expansions has children with an individual who has heterozygous or biallelic GCN repeat expansions, the individual's offspring will be heterozygous for a GCN repeat expansion.

Other family members. The risk to other family members depends on the genetic status of the proband's parents: if a parent of the proband has a GCN repeat expansion, the parent's family members may be at risk.

Related Genetic Counseling Issues

Family planning

- The optimal time for determination of genetic risk and discussion of the availability of prenatal/preimplantation genetic testing is before pregnancy.
- It is appropriate to offer genetic counseling (including discussion of potential risks to offspring and reproductive options) to young adults who are affected or at risk.

Predictive testing (i.e., testing of asymptomatic at-risk individuals)

- Predictive testing for at-risk relatives is possible once the GCN repeat expansion(s) have been identified in an affected family member.
- Potential consequences of such testing (including, but not limited to, socioeconomic changes and the need for long-term follow up and evaluation arrangements for individuals with a positive test result) as well as the capabilities and limitations of predictive testing should be discussed in the context of formal genetic counseling prior to testing.

Predictive testing in minors (i.e., testing of asymptomatic at-risk individuals younger than age 18 years)

- For asymptomatic minors at risk for adult-onset conditions for which early treatment would have no beneficial effect on disease morbidity and mortality, predictive genetic testing is considered inappropriate, primarily because it negates the autonomy of the child with no compelling benefit. Further, concern exists regarding the potential unhealthy adverse effects that such information may have on family dynamics, the risk of discrimination and stigmatization in the future, and the anxiety that such information may cause.
- For more information, see the National Society of Genetic Counselors [position statement](#) on genetic testing of minors for adult-onset conditions and the American Academy of Pediatrics and American College of Medical Genetics and Genomics [policy statement](#): ethical and policy issues in genetic testing and screening of children.

In a family with an established diagnosis of OPMD, it is appropriate to consider testing of symptomatic individuals regardless of age.

Prenatal Testing and Preimplantation Genetic Testing

Differences in perspective may exist among medical professionals and within families regarding the use of prenatal testing and preimplantation genetic testing. The [National Society of Genetic Counselors \(NSGC\)](#) does not recommend prenatal genetic testing for known adult-onset conditions if pregnancy or childhood management will not be affected. Due to potential medical and ethical complexities, NSGC recommends that prior to undergoing testing, prospective parents meet with a genetic counselor or other healthcare specialists with genetics expertise to discuss the implications of prenatal testing for adult-onset conditions. Pre-test counseling should include a discussion of the natural history of the condition, availability of treatments or interventions, concerns that prenatal testing for adult-onset conditions may deny a child's future autonomy, and potential for genetic discrimination.

Resources

GeneReviews staff has selected the following disease-specific and/or umbrella support organizations and/or registries for the benefit of individuals with this disorder and their families. GeneReviews is not responsible for the information provided by other organizations. For information on selection criteria, click [here](#).

- **Association Francaise contre les Myopathies (AFM)**
1 Rue de l'International
BP59
Evry cedex 91002
France
Phone: +33 01 69 47 28 28
Email: dmc@afm.genethon.fr
www.afm-telethon.fr
- **Muscular Dystrophy Association (MDA) - USA**
Phone: 833-275-6321
www.mda.org
- **Muscular Dystrophy Canada**
Canada
Phone: 800-567-2873
Email: info@muscle.ca
www.muscle.ca
- **Muscular Dystrophy UK**
United Kingdom
Phone: 0800 652 6352
www.musculardystrophyuk.org
- **Oculopharyngeal Muscular Dystrophy (OPMD) National Registry**
Email: hsc-opmd@salud.unm.edu
[National OPMD Registry](#)

Molecular Genetics

Information in the Molecular Genetics and OMIM tables may differ from that elsewhere in the GeneReview: tables may contain more recent information. —ED.

Table A. Oculopharyngeal Muscular Dystrophy: Genes and Databases

Gene	Chromosome Locus	Protein	Locus-Specific Databases	HGMD	ClinVar
<i>PABPN1</i>	14q11.2	Polyadenylate-binding protein 2	PABPN1 homepage - Leiden Muscular Dystrophy pages	PABPN1	PABPN1

Data are compiled from the following standard references: gene from [HGNC](#); chromosome locus from [OMIM](#); protein from [UniProt](#). For a description of databases (Locus Specific, HGMD, ClinVar) to which links are provided, click [here](#).

Table B. OMIM Entries for Oculopharyngeal Muscular Dystrophy ([View All in OMIM](#))

164300	OCULOPHARYNGEAL MUSCULAR DYSTROPHY 1; OPMD1
602279	POLYADENYLATE-BINDING PROTEIN, NUCLEAR, 1; PABPN1

Molecular Pathogenesis

PABPN1 encodes PABPN1, an abundant nuclear protein that shuttles between nucleus and cytoplasm [Calado et al 2000]. PABPN1 associates with RNA polymerase II during transcription; binding to the poly(A) RNAs, it accompanies the released transcripts through the nuclear pore [Bear et al 2003, Kerwitz et al 2003].

PABPN1 is ubiquitously expressed at a very low level in skeletal muscle [Apponi et al 2010] and is mostly localized in the nucleus with enrichment in nuclear speckles (the pre-mRNA processing subnuclear area) [Banerjee et al 2013]. PABPN1 specifically binds the poly(A) sequences of mRNAs and is implicated in mRNA polyadenylation activity.

Other roles of PABPN1:

- Splicing regulation [Bergeron et al 2015]
- Nuclear surveillance via hyperadenylation and decay of RNA [Bresson & Conrad 2013]
- Regulation of noncoding RNA (lncRNA) [Beaulieu et al 2012]
- Regulation of small nucleolar RNA (snoRNA) processing [Lemay et al 2010]
- Regulation of nuclear-encoded mitochondrial RNA [Chartier et al 2015, Vest et al 2017]

PABPN1 nuclear aggregates are a pathologic hallmark of the disease; aggregates are found in 5%-15% of myofiber nuclei in affected and unaffected muscle sections of persons with OPMD [Tomé & Fardeau 1980, Tomé et al 1997, Calado et al 2000, Gidaro et al 2013]. PABPN1 depletion leads to abnormal organization of the nuclear speckle and alteration of RNA editing (adenosine to inosine) [Banerjee et al 2017].

Mechanism of disease causation. OPMD pathogenesis likely occurs through a polyalanine toxicity gain-of-function mechanism, such as abnormal aggregation and inefficient protein degradation [Brais et al 1998, Brais et al 1999, Banerjee et al 2013]. Inclusion formation and PABPN1 inclusions have a broad and significant effect on the expression of genes involved in mRNA processing [Corbeil-Girard et al 2005] and on RNA splicing [Klein et al 2016].

Another emerging hypothesis in OPMD is a PABPN1 loss of function in cells, either directly via mutation of *PABPN1* or indirectly via PABPN1 sequestration in aggregates [Banerjee et al 2013, Vest et al 2017].

***PABPN1*-specific laboratory technical considerations.** The *PABPN1* repeat causing OPMD is designated GCN, where N represents any A/C/G/T nucleotide, due to normal variation in the sequence. All four possible codons encode alanine. Of note, both Sanger sequencing and next-generation sequencing can be used to determine the repeat size and sequence.

The GCN repeat expansion has been described in various ways. Repeat expansions were first described as pure (GCG) expansions of a (GCG)₆ stretch coding for six alanines in the first exon [Brais et al 1998].

- The normal GCN[10] allele was referred to as (GCN)₆.
- The pathogenic GCN[11_18] alleles were referred to as (GCN)₇₋₁₄.

When available, the full sequence of normal and pathogenic (expanded) alleles should be reported; for example, an Ala13 allele may have a sequence of GCG[10]GCA[1]GCG[2] (previously reported as (GCG)₁₀(GCA)₁(GCG)₂).

A European Neuromuscular Center (ENMC) workshop on OPMD [Raz et al 2013] suggested the following variant nomenclature for the number of *PABPN1* triplet repeats / number of alanines:

- **Normal allele.** (GCN)₁₀ / Ala₁₀ (See Figure 1.)
- **Pathogenic alleles.** (GCN)₁₁₋₁₈ and Ala₁₁₋₁₈, where the range of triplet repeats/alanines is 11-18

The nomenclature of the Human Genome Variation Society (HGVS) for these alleles is given in Table 7.

Table 7. Notable *PABPN1* Pathogenic Variants

Reference Sequences	DNA Nucleotide Change	Predicted Protein Change	Comment [Reference]
NM_004643.3	c.4_6GCN[10]	p.2Ala[10]	Normal allele
NP_004634.1	c.4_6GCN[11_18]	p.2Ala[11_18]	Expanded allele range assoc w/OPMD

Variants listed in the table have been provided by the authors. *GeneReviews* staff have not independently verified the classification of variants.

GeneReviews follows the standard naming conventions of the Human Genome Variation Society (varnomen.hgvs.org). See [Quick Reference](#) for an explanation of nomenclature.

Chapter Notes

Author Notes

Alexis Boulinguez, PhD

Myology Centre for Research UMR974
INSERM, Sorbonne Université
Institut de Myologie, Paris

Gillian Butler-Browne, PhD

Myology Centre for Research UMR974
INSERM, Sorbonne Université
Institut de Myologie, Paris

Teresinha Evangelista, MD

Neuromuscular Morphology Unit
Myology Institute
GHU Pitié-Salpêtrière
Sorbonne Université, Paris

Jean Lacau St Guily, MD

Myology Centre for Research UMR974

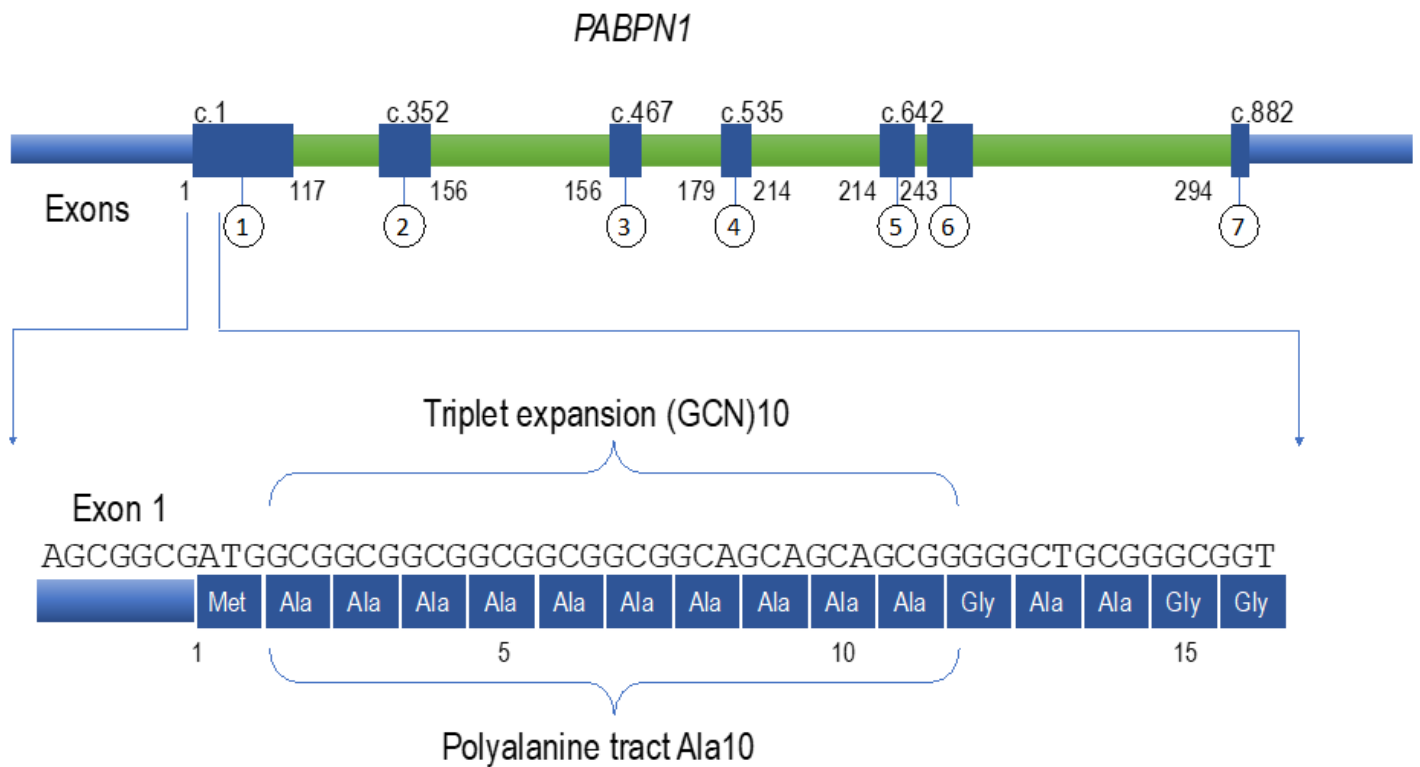


Figure 1. Upper figure: schematic representation of *PABPN1*

Lower figure: portion of exon 1 containing the triplet repeat (GCN)₁₀, with the corresponding polyaniline tract in the protein sequence below

INSERM, Sorbonne Université
Institut de Myologie, Paris

Pascale Richard, PharmD, PhD

APHP, Unité Fonctionnelle de Cardiogénétique et Myogénétique Moléculaire
Hôpitaux Universitaires Pitié Salpêtrière-Charles Foix, Paris

Fanny Roth, PhD

Myology Centre for Research UMR974
INSERM, Sorbonne Université
Institut de Myologie, Paris

Tanya Stojkovic, MD

APHP, Centre de Référence des Maladies Neuromusculaire
Institut de Myologie
Hôpitaux Universitaires Pitié Salpêtrière-Charles Foix, Paris

Capucine Trollet, PhD

Myology Centre for Research UMR974
INSERM, Sorbonne Université
Institut de Myologie, Paris

<https://www.afm-telathon.fr/fr/fiches-maladies/dystrophie-musculaire-oculopharyngee-recherche-myologie.fr/research/labs/trollet-mouly-lab/?lang=en>

www.institut-myologie.org/en

Author History

Alexis Boulinguez, PhD (2020-present)

Bernard Brais, MD, MPhil, PhD; Hôpital Notre-Dame-CHUM, Montréal (2001-2014)

Gillian Butler-Browne, PhD (2014-present)

Teresinha Evangelista, MD (2020-present)

Teresa Gidaro, MD, PhD; Institut de Myologie, Paris (2014-2020)

Pierre Klein, PhD; Institut de Myologie, Paris (2014-2020)

Jean Lacau St Guily, MD (2014-present)

Sophie Périé, MD, PhD; Université Pierre et Marie Curie, Paris (2014-2020)

Pascale Richard, PharmD, PhD (2020-present)

Fanny Roth, PhD (2020-present)

Guy A Rouleau, MD, PhD; Hôpital Notre-Dame-CHUM, Montreal (2001-2014)

Capucine Trollet, PhD (2014-present)

Tanya Stojkovic, MD (2020-present)

Revision History

- 22 October 2020 (bp) Comprehensive update posted live
- 20 February 2014 (me) Comprehensive update posted live
- 22 June 2006 (ca) Comprehensive update posted live
- 3 December 2003 (me) Comprehensive update posted live
- 8 March 2001 (me) Review posted live
- December 2000 (bb) Original submission

References

Published Guidelines / Consensus Statements

Association française contre les myopathies. Zoom sur la Dystrophie Musculaire Oculopharyngée. Evry, France: Monographies Myoline. Available [online](#). 2018. Accessed 4-4-23.

Committee on Bioethics, Committee on Genetics, and American College of Medical Genetics and Genomics Social, Ethical, Legal Issues Committee. Ethical and policy issues in genetic testing and screening of children. Available [online](#). 2013. Accessed 4-4-23.

National Society of Genetic Counselors. Position statement on genetic testing of minors for adult-onset conditions. Available [online](#). 2018. Accessed 4-4-23.

Literature Cited

Abu-Baker A, Kharma N, Perreault J, Grant A, Shekarabi M, Maios C, Dona M, Neri C, Dion PA, Parker A, Varin L, Rouleau GA. RNA-based therapy utilizing oculopharyngeal muscular dystrophy transcript knockdown and replacement. *Mol Ther Nucleic Acids*. 2019;15:12–25. PubMed PMID: 30831428.

Abu-Baker A, Laganier S, Fan X, Laganier J, Brais B, Rouleau GA. Cytoplasmic targeting of mutant poly(A)-binding protein nuclear 1 suppresses protein aggregation and toxicity in oculopharyngeal muscular dystrophy. *Traffic*. 2005;6:766–79. PubMed PMID: 16101680.

- Abu-Baker A, Laganriere J, Gaudet R, Rochefort D, Brais B, Neri C, Dion PA, Rouleau GA. Lithium chloride attenuates cell death in oculopharyngeal muscular dystrophy by perturbing Wnt/ β -catenin pathway. *Cell Death Dis.* 2013;4:e821. PubMed PMID: 24091664.
- Abu-Baker A, Parker A, Ramalingam S, Laganriere J, Brais B, Neri C, Dion P, Rouleau G. Valproic acid is protective in cellular and worm models of oculopharyngeal muscular dystrophy. *Neurology.* 2018;91:e551–e561. PubMed PMID: 30006409.
- Alonso-Jimenez A, Kroon RHMJM, Alejaldre-Monforte A, Nuñez-Peralta C, Horlings CGC, van Engelen BGM, Olivé M, González L, Verges-Gil E, Paradas C, Márquez C, Garibaldi M, Gallano P, Rodriguez MJ, Gonzalez-Quereda L, Dominguez Gonzalez C, Vissing J, Fornander F, Eisum AV, García-Sobrino T, Pardo J, García-Figueiras R, Muelas N, Vilchez JJ, Kapetanovic S, Tasca G, Monforte M, Ricci E, Gomez MT, Bevilacqua JA, Diaz-Jara J, Zamorano II, Carlier RY, Laforet P, Pelayo-Negro A, Ramos-Fransi A, Martínez A, Marini-Bettolo C, Straub V, Gutiérrez G, Stojkovic T, Martín MA, Morís G, Fernández-Torrón R, Lopez De Munaín A, Cortes-Vicente E, Querol L, Rojas-García R, Illa I, Diaz-Manera J. Muscle MRI in a large cohort of patients with oculopharyngeal muscular dystrophy. *J Neurol Neurosurg Psychiatry.* 2019;90:576–85. PubMed PMID: 30530568.
- Apponi LH, Leung SW, Williams KR, Valentini SR, Corbett AH, Pavlath GK. Loss of nuclear poly(A)-binding protein 1 causes defects in myogenesis and mRNA biogenesis. *Hum Mol Genet.* 2010;19:1058–65. PubMed PMID: 20035013.
- Argov Z, Gliko-Kabir I, Brais B, Caraco Y, Megiddo D. Intravenous trehalose improves dysphagia and muscle function in oculopharyngeal muscular dystrophy (OPMD): preliminary results of 24 weeks open label Phase 2 trial (S28.004). *Neurology.* 2016.:86.
- Askanas V, Engel WK. New advances in the understanding of sporadic inclusion-body myositis and hereditary inclusion-body myopathies. *Curr Opin Rheumatol.* 1995;7:486–96. PubMed PMID: 8579968.
- Audag N, Goubau C, Toussaint M, Reyhler G. Screening and evaluation tools of dysphagia in adults with neuromuscular diseases: a systematic review. *Ther Adv Chronic Dis.* 2019;10:2040622318821622. PubMed PMID: 30728931.
- Banerjee A, Apponi LH, Pavlath GK, Corbett AH. PABPN1: molecular function and muscle disease. *FEBS J.* 2013;280:4230–50. PubMed PMID: 23601051.
- Banerjee A, Vest KE, Pavlath GK, Corbett AH. Nuclear poly(A) binding protein 1 (PABPN1) and Matrin3 interact in muscle cells and regulate RNA processing. *Nucleic Acids Res.* 2017;45:10706–25. PubMed PMID: 28977530.
- Bao YP, Cook LJ, O'Donovan D, Uyama E, Rubinsztein DC. Mammalian, yeast, bacterial, and chemical chaperones reduce aggregate formation and death in a cell model of oculopharyngeal muscular dystrophy. *J Biol Chem.* 2002;277:12263–9. PubMed PMID: 11796717.
- Bao YP, Sarkar S, Uyama E, Rubinsztein DC. Congo red, doxycycline, and HSP70 overexpression reduce aggregate formation and cell death in cell models of oculopharyngeal muscular dystrophy. *J Med Genet.* 2004;41:47–51. PubMed PMID: 14729833.
- Barbeau A. The syndrome of hereditary late-onset ptosis and dysphagia in French Canada. In: Kühn E, ed. *Symposium über Progressive Muskeldystrophie.* Berlin, Germany: Springer-Verlag; 1996:102-9.
- Barbezier N, Chartier A, Bidet Y, Buttstedt A, Voisset C, Galons H, Blondel M, Schwarz E, Simonelig M. Antiprion drugs 6-aminophenanthridine and guanabenz reduce PABPN1 toxicity and aggregation in oculopharyngeal muscular dystrophy. *EMBO Mol Med.* 2011;3:35–49. PubMed PMID: 21204267.
- Bear DG, Fomproix N, Soop T, Bjorkroth B, Masich S, Daneholt B. Nuclear poly(A)-binding protein PABPN1 is associated with RNA polymerase II during transcription and accompanies the released transcript to the nuclear pore. *Exp Cell Res.* 2003;286:332–44. PubMed PMID: 12749861.

- Beaulieu YB, Kleinman CL, Landry-Voyer AM, Majewski J, Bachand F. Polyadenylation-dependent control of long noncoding RNA expression by the poly(A)-binding protein nuclear 1. *PLoS Genet.* 2012;8:e1003078. PubMed PMID: 23166521.
- Becher MW, Morrison L, Davis LE, Maki WC, King MK, Bicknell JM, Reinert BL, Bartolo C, Bear DG. Oculopharyngeal muscular dystrophy in Hispanic New Mexicans. *JAMA.* 2001;286:2437–40. PubMed PMID: 11712939.
- Bergeron D, Pal G, Beaulieu YB, Chabot B, Bachand F. Regulated intron retention and nuclear pre-mRNA decay contribute to PABPN1 autoregulation. *Mol Cell Biol.* 2015;35:2503–17. PubMed PMID: 25963658.
- Blumen SC, Bouchard JP, Brais B, Carasso RL, Paleacu D, Drory VE, Chantal S, Blumen N, Braverman I. Cognitive impairment and reduced life span of oculopharyngeal muscular dystrophy homozygotes. *Neurology.* 2009;73:596–601. PubMed PMID: 19704078.
- Blumen SC, Brais B, Korczyn AD, Medinsky S, Chapman J, Asherov A, Nisipeanu P, Codère F, Bouchard JP, Fardeau M, Tome FM, Rouleau GA. Homozygotes for oculopharyngeal muscular dystrophy have a severe form of the disease. *Ann Neurol.* 1999;46:115–8. PubMed PMID: 10401788.
- Blumen SC, Nisipeanu P, Sadeh M, Asherov A, Blumen N, Wirguin Y, Khilkevich O, Carasso RL, Korczyn AD. Epidemiology and inheritance of oculopharyngeal muscular dystrophy in Israel. *Neuromuscul Disord.* 1997;7:S38–40. PubMed PMID: 9392014.
- Bouchard JP, Brais B, Brunet D, Gould PV, Rouleau GA. Recent studies on oculopharyngeal muscular dystrophy in Quebec. *Neuromuscul Disord.* 1997;7:S22–9. PubMed PMID: 9392011.
- Bouchard JP, Marcoux S, Gosselin F, Pineault D, Rouleau GA. A simple test for the detection of the dysphagia in members of families with oculopharyngeal muscular dystrophy (OPMD). *Can J Neurol Sci.* 1992;19:296–7.
- Brais B. Oculopharyngeal muscular dystrophy: a late-onset polyalanine disease. *Cytogenet Genome Res.* 2003;100:252–60. PubMed PMID: 14526187.
- Brais B, Bouchard JP, Gosselin F, Xie YG, Fardeau M, Tome FM, Rouleau GA. Using the full power of linkage analysis in 11 French Canadian families to fine map the oculopharyngeal muscular dystrophy gene. *Neuromuscul Disord.* 1997;7:S70–4. PubMed PMID: 9392020.
- Brais B, Bouchard JP, Xie YG, Rochefort DL, Chretien N, Tome FM, Lafreniere RG, Rommens JM, Uyama E, Nohira O, Blumen S, Korczyn AD, Heutink P, Mathieu J, Duranceau A, Codère F, Fardeau M, Rouleau GA, Korczyn AD. Short GCG expansions in the PABP2 gene cause oculopharyngeal muscular dystrophy. *Nat Genet.* 1998;18:164–7. PubMed PMID: 9462747.
- Brais B, Rouleau GA, Bouchard JP, Fardeau M, Tome FM. Oculopharyngeal muscular dystrophy. *Semin Neurol.* 1999;19:59–66.
- Brais B, Xie YG, Sanson M, Morgan K, Weissenbach J, Korczyn AD, Blumen SC, Fardeau M, Tomé FM, Bouchard JP, Rouleau GA. The oculopharyngeal muscular dystrophy locus maps to the region of the cardiac alpha and beta myosin heavy chain genes on chromosome 14q11.2-q13. *Hum Mol Genet.* 1995;4:429–34. PubMed PMID: 7795598.
- Bresson SM, Conrad NK. The human nuclear poly(a)-binding protein promotes RNA hyperadenylation and decay. *PLoS Genet.* 2013;9:e1003893. PubMed PMID: 24146636.
- Brisson JD, Gagnon C, Brais B, Côté I, Mathieu J. A study of impairments in oculopharyngeal muscular dystrophy. *Muscle Nerve.* 2020;62:201–7. PubMed PMID: 32270505.
- Brunet G, Tome FM, Eymard B, Robert JM, Fardeau M. Genealogical study of oculopharyngeal muscular dystrophy in France. *Neuromuscul Disord.* 1997;7:S34–7. PubMed PMID: 9392013.
- Calado A, Tome FM, Brais B, Rouleau GA, Kühn U, Wahle E, Carmo-Fonseca M. Nuclear inclusions in oculopharyngeal muscular dystrophy consist of poly(A) binding protein 2 aggregates which sequester poly(A) RNA. *Hum Mol Genet.* 2000;9:2321–8. PubMed PMID: 11001936.

- Caron MJ, Girard F, Girard DC, Boudreault D, Brais B, Nassif E, Chouinard P, Ruel M, Duranceau A. Cisatracurium pharmacodynamics in patients with oculopharyngeal muscular dystrophy. *Anesth Analg*. 2005;100:393–7. PubMed PMID: 15673864.
- Chartier A, Klein P, Pierson S, Barbezier N, Gidaro T, Casas F, Carberry S, Dowling P, Maynadier L, Bellec M, Oloko M, Jardel C, Moritz B, Dickson G, Mouly V, Ohlendieck K, Butler-Browne G, Trollet C, Simonelig M. Mitochondrial dysfunction reveals the role of mRNA poly(A) tail regulation in oculopharyngeal muscular dystrophy pathogenesis. *PLoS Genet*. 2015;11:e1005092. PubMed PMID: 25816335.
- Chartier A, Raz V, Sterrenburg E, Verrips CT, van der Maarel SM, Simonelig M. Prevention of oculopharyngeal muscular dystrophy by muscular expression of Llama single-chain intrabodies in vivo. *Hum Mol Genet*. 2009;18:1849–59. PubMed PMID: 19258344.
- Codère F. Oculopharyngeal muscular dystrophy. *Can J Ophthalmol*. 1993;28:1–2. PubMed PMID: 8439856.
- Coiffier L, Périé S, Laforêt P, Eymard B, St Guily JL. Long-term results of cricopharyngeal myotomy in oculopharyngeal muscular dystrophy. *Otolaryngol Head Neck Surg*. 2006;135:218–22. PubMed PMID: 16890071.
- Corbeil-Girard LP, Klein AF, Sasseville AM, Lavoie H, Dicaire MJ, Saint-Denis A, Page M, Duranceau A, Codère F, Bouchard JP, Karpati G, Rouleau GA, Massie B, Langelier Y, Brais B. PABPN1 overexpression leads to upregulation of genes encoding nuclear proteins that are sequestered in oculopharyngeal muscular dystrophy nuclear inclusions. *Neurobiol Dis*. 2005;18:551–67. PubMed PMID: 15755682.
- Davies JE, Sarkar S, Rubinsztein DC. Trehalose reduces aggregate formation and delays pathology in a transgenic mouse model of oculopharyngeal muscular dystrophy. *Hum Mol Genet*. 2006;15:23–31. PubMed PMID: 16311254.
- Davies JE, Wang L, Garcia-Oroz L, Cook LJ, Vacher C, O'Donovan DG, Rubinsztein DC. Doxycycline attenuates and delays toxicity of the oculopharyngeal muscular dystrophy mutation in transgenic mice. *Nat Med*. 2005;11:672–7. PubMed PMID: 15864313.
- Dedrick DL, Brown LK. Obstructive sleep apnea syndrome complicating oculopharyngeal muscular dystrophy. *Chest*. 2004;125:334–6. PubMed PMID: 14718463.
- Deng J, Yu J, Li P, Luan X, Cao L, Zhao J, Yu M, Zhang W, Lv H, Xie Z, Meng L, Zheng Y, Zhao Y, Gang Q, Wang Q, Liu J, Zhu M, Guo X, Su Y, Liang Y, Liang F, Hayashi T, Maeda MH, Sato T, Ura S, Oya Y, Ogasawara M, Iida A, Nishino I, Zhou C, Yan C, Yuan Y, Hong D, Wang Z. Expansion of GGC repeat in GIPC1 is associated with oculopharyngodistal myopathy. *Am J Hum Genet*. 2020;106:793–804. PubMed PMID: 32413282.
- Dodds WJ, Logemann JA, Stewart ET. Radiologic assessment of abnormal oral and pharyngeal phases of swallowing. *AJR Am J Roentgenol*. 1990;154:965–74. PubMed PMID: 2108570.
- Dubbioso R, Moretta P, Manganelli F, Fiorillo C, Iodice R, Trojano L, Santoro L. Executive functions are impaired in heterozygote patients with oculopharyngeal muscular dystrophy. *J Neurol*. 2012;259:833–7. PubMed PMID: 21956377.
- Duranceau A. Cricopharyngeal myotomy in the management of neurogenic and muscular dysphagia. *Neuromuscul Disord*. 1997;7:S85–9. PubMed PMID: 9392023.
- Duranceau A, Forand MD, Fauteux JP. Surgery in oculopharyngeal muscular dystrophy. *Am J Surg*. 1980;139:33–9. PubMed PMID: 7350844.
- Duranceau AC, Beauchamp G, Jamieson GG, Barbeau A. Oropharyngeal dysphagia and oculopharyngeal muscular dystrophy. *Surg Clin North Am*. 1983;63:825–32. PubMed PMID: 6351296.
- Fischmann A, Gloor M, Fasler S, Haas T, Rodoni Wetzels R, Bieri O, et al. Muscular involvement assessed by MRI correlates to motor function measurement values in oculopharyngeal muscular dystrophy. *J Neurol*. 2011;258:1333–40. PubMed PMID: 21340522.

- Fukuhara N, Kumamoto T, Tsubaki T. Rimmed vacuoles. *Acta Neuropathol.* 1980;51:229–35. PubMed PMID: 7445977.
- Galimberti V, Tironi R, Lerario A, Scali M, Del Bo R, Rodolico C, Brizzi T, Gibertini S, Maggi L, Mora M, Toscano A, Comi GP, Sciacco M, Moggio M, Peverelli L. Value of insoluble PABPN1 accumulation in the diagnosis of oculopharyngeal muscular dystrophy. *Eur J Neurol.* 2020;27:709–15. PubMed PMID: 31769567.
- Garibaldi M, Pennisi EM, Bruttini M, Bizzarri V, Bucci E, Morino S, Talerico C, Stoppacciaro A, Renieri A, Antonini G. Dropped-head in recessive oculopharyngeal muscular dystrophy. *Neuromuscul Disord.* 2015;25:869–72. PubMed PMID: 26494409.
- Gidaro T, Negroni E, Périé S, Mirabella M, Lainé J, Lacau St Guily J, Butler-Browne G, Mouly V, Trollet C. Atrophy, fibrosis, and increased PAX7-positive cells in pharyngeal muscles of oculopharyngeal muscular dystrophy patients. *J Neuropathol Exp Neurol.* 2013;72:234–43. PubMed PMID: 23399899.
- Gloor M, Fasler S, Fischmann A, Haas T, Bieri O, Heinimann K, et al. Quantification of fat infiltration in oculopharyngeal muscular dystrophy: comparison of three MR imaging methods. *J Magn Reson Imaging.* 2011;33:203–10. PubMed PMID: 21182140.
- Gómez-Torres A, Abrante Jiménez A, Rivas Infante E, Menoyo Bueno A, Tirado Zamora I, Esteban Ortega F. Cricopharyngeal myotomy in the treatment of oculopharyngeal muscular dystrophy. *Acta Otorrinolaringol Esp.* 2012;63:465–9. PubMed PMID: 22898142.
- Goto I, Kanazawa Y, Kobayashi T, Murai Y, Kuroiwa Y. Oculopharyngeal myopathy with distal and cardiomyopathy. *J Neurol Neurosurg Psychiatry.* 1977;40:600–7. PubMed PMID: 903774.
- Goyal NA, Mozaffar T, Chui LA. Oculopharyngeal muscular dystrophy, an often misdiagnosed neuromuscular disorder: a Southern California experience. *J Clin Neuromuscul Dis.* 2019;21:61–8. PubMed PMID: 31743248.
- Grewal RP, Karkera JD, Grewal RK, Detera-Wadleigh SD. Mutation analysis of oculopharyngeal muscular dystrophy in Hispanic American families. *Arch Neurol.* 1999;56:1378–81. PubMed PMID: 10555658.
- Harish P, Malerba A, Dickson G, Bachtarzi H. Progress on gene therapy, cell therapy, and pharmacological strategies toward the treatment of oculopharyngeal muscular dystrophy. *Hum Gene Ther.* 2015;26:286–92. PubMed PMID: 25860803.
- Hill M, Hughes T, Milford C. Treatment for swallowing difficulties (dysphagia) in chronic muscle disease. *Cochrane Database Syst Rev.* 2004;2:CD004303.
- Ishiura H, Shibata S, Yoshimura J, Suzuki Y, Qu W, Doi K, Almansour MA, Kikuchi JK, Taira M, Mitsui J, Takahashi Y, Ichikawa Y, et al. Noncoding CGG repeat expansions in neuronal intranuclear inclusion disease, oculopharyngodistal myopathy and an overlapping disease. *Nature Genet.* 2019;51:1222–32. PubMed PMID: 31332380.
- Jaspar HH, Bastiaensen LA, ter Laak HJ, Joosten EM, Horstink MW, Stadhouders AM. Oculopharyngodistal myopathy with early onset and neurogenic features. *Clin Neurol Neurosurg.* 1977;80:272–82. PubMed PMID: 216518.
- Jouan L, Rocheford D, Szuto A, Carney E, David K, Dion PA, Rouleau GA. An 18 alanine repeat in a severe form of oculopharyngeal muscular dystrophy. *Can J Neurol Sci.* 2014;41:508–11. PubMed PMID: 24878479.
- Kerwitz Y, Kühn U, Lilie H, Knoth A, Scheuermann T, Friedrich H, Schwarz E, Wahle E. Stimulation of poly(A) polymerase through a direct interaction with the nuclear poly(A) binding protein allosterically regulated by RNA. *EMBO J.* 2003;22:3705–14. PubMed PMID: 12853485.
- Klein P, Oloko M, Roth F, Montel V, Malerba A, Jarmin S, Gidaro T, Popplewell L, Perie S, Lacau St Guily J, de la Grange P, Antoniou MN, Dickson G, Butler-Browne G, Bastide B, Mouly V, Trollet C. Nuclear poly(A)-binding protein aggregates misplace a pre-mRNA outside of SC35 speckle causing its abnormal splicing. *Nucleic Acids Res.* 2016;44:10929–45. PubMed PMID: 27507886.

- Kroon RHMJM, Horlings CGC, de Swart BJM, van Engelen BGM, Kalf JG. Swallowing, chewing and speaking: frequently impaired in oculopharyngeal muscular dystrophy. *J Neuromuscul Dis*. 2020;7:483–94. PubMed PMID: 32804098.
- Langmore SE, Schatz K, Olson N. Endoscopic and videofluoroscopic evaluations of swallowing and aspiration. *Ann Otol Rhinol Laryngol*. 1991;100:678–81. PubMed PMID: 1872520.
- Leclerc A, Tomé FM, Fardeau M. Ubiquitin and beta-amyloid-protein in inclusion body myositis (IBM), familial IBM-like disorder and oculopharyngeal muscular dystrophy: an immunocytochemical study. *Neuromuscul Disord*. 1993;3:283–91. PubMed PMID: 8268725.
- Lemay JF, D'Amours A, Lemieux C, Lackner DH, St-Sauveur VG, Bähler J, Bachand F. The nuclear poly(A)-binding protein interacts with the exosome to promote synthesis of noncoding small nucleolar RNAs. *Mol Cell*. 2010;37:34–45. PubMed PMID: 20129053.
- Linoli G, Tomelleri G, Ghezzi M. Oculopharyngeal muscular dystrophy. Description of a case with involvement of the central nervous system. *Pathologica*. 1991;83:325–34. PubMed PMID: 1923632.
- Malerba A, Klein P, Bachtarzi H, Jarmin SA, Cordova G, Ferry A, Strings V, Espinoza MP, Mamchaoui K, Blumen SC, St Guily JL, Mouly V, Graham M, Butler-Browne G, Suhy DA, Trollet C, Dickson G. PABPN1 gene therapy for oculopharyngeal muscular dystrophy. *Nat Commun*. 2017;8:14848. PubMed PMID: 28361972.
- Malerba A, Klein P, Lu-Nguyen N, Cappellari O, Strings-Ufombah V, Harbaran S, Roelvink P, Suhy D, Trollet C, Dickson G. Established PABPN1 intranuclear inclusions in OPMD muscle can be efficiently reversed by AAV-mediated knockdown and replacement of mutant expanded PABPN1. *Hum Mol Genet*. 2019a;28:3301–8. PubMed PMID: 31294444.
- Malerba A, Roth F, Harish P, Dhiab J, Lu-Nguyen N, Cappellari O, Jarmin S, Mahoudeau A, Ythier V, Lainé J, Negroni E, Abgueguen E, Simonelig M, Guedat P, Mouly V, Butler-Browne G, Voisset C, Dickson G, Trollet C. Pharmacological modulation of the ER stress response ameliorates oculopharyngeal muscular dystrophy. *Hum Mol Genet*. 2019b;28:1694–708. PubMed PMID: 30649389.
- Manjaly JG, Vaughan-Shaw PG, Dale OT, Tyler S, Corlett JC, Frost RA. Cricopharyngeal dilatation for the long-term treatment of dysphagia in oculopharyngeal muscular dystrophy. *Dysphagia*. 2012;27:216–20. PubMed PMID: 21805106.
- Mathieu J, Lapointe G, Brassard A, Tremblay C, Brais B, Rouleau GA, Bouchard JP. A pilot study on upper oesophageal sphincter dilatation for the treatment of dysphagia in patients with oculopharyngeal muscular dystrophy. *Neuromuscul Disord*. 1997;7:S100–4. PubMed PMID: 9392026.
- McHorney CA, Robbins J, Lomax K, Rosenbek JC, Chignell K, Kramer AE, Bricker DE. The SWAL-QOL and SWAL-CARE outcomes tool for oropharyngeal dysphagia in adults: III. Documentation of reliability and validity. *Dysphagia*. 2002;17:97–114. PubMed PMID: 11956835.
- Montgomery WW, Lynch JP. Oculopharyngeal muscular dystrophy treated by inferior constrictor myotomy. *Trans Am Acad Ophthalmol Otolaryngol*. 1971;75:986–93. PubMed PMID: 5097831.
- Patel DA, Sharda R, Hovis KL, Nichols EE, Sathe N, Penson DF, Feurer ID, McPheeters ML, Vaezi MF, Francis DO. Patient-reported outcome measures in dysphagia: a systematic review of instrument development and validation. *Dis Esophagus*. 2017;30:1–23.
- Périé S, Eymard B, Laccourreye L, Chaussade S, Fardeau M, Lacau St Guily J. Dysphagia in oculopharyngeal muscular dystrophy: a series of 22 French cases. *Neuromuscul Disord*. 1997;7 Suppl 1:S96–9. PubMed PMID: 9392025.
- Périé S, Laccourreye L, Flahault A, Hazebroucq V, Chaussade S, St Guily JL. Role of videoendoscopy in assessment of pharyngeal function in oropharyngeal dysphagia: comparison with videofluoroscopy and manometry. *Laryngoscope*. 1998;108:1712–6. PubMed PMID: 9818831.

- Périé S, Trollet C, Mouly V, Vanneaux V, Mamchaoui K, Bouazza B, Marolleau JP, Laforêt P, Chapon F, Eymard B, Butler-Browne G, Larghero J, St Guily JL. Autologous myoblast transplantation for oculopharyngeal muscular dystrophy: a phase I/IIa clinical study. *Mol Ther*. 2014;22:219–25. PubMed PMID: 23831596.
- Probst A, Tackmann W, Stoeckli HR, Jerusalem F, Ulrich J. Evidence for a chronic axonal atrophy in oculopharyngeal "muscular dystrophy". *Acta Neuropathol*. 1982;57:209–16. PubMed PMID: 7124348.
- Rahbari R, Wuster A, Lindsay SJ, Hardwick RJ, Alexandrov LB, Turki SA, Dominiczak A, Morris A, Porteous D, Smith B, Stratton MR, Hurles ME, et al. Timing, rates and spectra of human germline mutation. *Nat Genet*. 2016;48:126–33. PubMed PMID: 26656846.
- Raz V, Butler-Browne G, van Engelen B, Brais B. 191st ENMC international workshop: recent advances in oculopharyngeal muscular dystrophy research: from bench to bedside 8-10 June 2012, Naarden, The Netherlands. *Neuromuscul Disord*. 2013;23:516–23. PubMed PMID: 23578714.
- Restivo DA, Marchese RR, Staffieri A, de Grandis D. Successful botulinum toxin treatment of dysphagia in oculopharyngeal muscular dystrophy. *Gastroenterology*. 2000;119:1416.
- Richard P, Trollet C, Gidaro T, Demay L, Brochier G, Malfatti E, Tom FM, Fardeau M, Lafor P, Romero N, Martin-N ML, Sol G, Ferrer-Monasterio X, Saint-Guily JL, Eymard B. PABPN1 (GCN)11 as a dominant allele in oculopharyngeal muscular dystrophy -consequences in clinical diagnosis and genetic counselling. *J Neuromuscul Dis*. 2015;2:175–80. PubMed PMID: 27858728.
- Richard P, Trollet C, Stojkovic T, de Becdelievre A, Perie S, Pouget J, Eymard B, et al. Correlation between PABPN1 genotype and disease severity in oculopharyngeal muscular dystrophy. *Neurology*. 2017;88:359–65. PubMed PMID: 28011929.
- Richards S, Aziz N, Bale S, Bick D, Das S, Gastier-Foster J, Grody WW, Hegde M, Lyon E, Spector E, Voelkerding K, Rehm HL; ACMG Laboratory Quality Assurance Committee. Standards and guidelines for the interpretation of sequence variants: a joint consensus recommendation of the American College of Medical Genetics and Genomics and the Association for Molecular Pathology. *Genet Med*. 2015;17:405–24. PubMed PMID: 25741868.
- Robinson DO, Hammans SR, Read SP, Sillibourne J. Oculopharyngeal muscular dystrophy (OPMD): analysis of the PABPN1 gene expansion sequence in 86 patients reveals 13 different expansion types and further evidence for unequal recombination as the mutational mechanism. *Hum Genet*. 2005;116:267–71. PubMed PMID: 15645184.
- Rodrigue D, Molgat YM. Surgical correction of blepharoptosis in oculopharyngeal muscular dystrophy. *Neuromuscul Disord*. 1997;7:S82–4. PubMed PMID: 9392022.
- Rüegg S, Lehky Hagen M, Hohl U, Kappos L, Fuhr P, Plasilov M, Müller H, Heinimann K. Oculopharyngeal muscular dystrophy - an under-diagnosed disorder? *Swiss Med Wkly*. 2005;135:574–86. PubMed PMID: 16333769.
- Salassa JR. A functional outcome swallowing scale for staging oropharyngeal dysphagia. *Dig Dis*. 1999;17:230–4. PubMed PMID: 10754363.
- Satoyoshi E, Kinoshita M. Oculopharyngodistal myopathy. *Arch Neurol*. 1977;34:89–92. PubMed PMID: 836191.
- Schneider I, Thumfart WF, Pototschnig C, Eckel HE. Treatment of dysfunction of the cricopharyngeal muscle with botulinum A toxin: introduction of a new, noninvasive method. *Ann Otol Rhinol Laryngol*. 1994;103:31–5. PubMed PMID: 8291857.
- Schober R, Kress W, Grahmann F, Kellermann S, Baum P, Günzel S, Wagner A. Unusual triplet expansion associated with neurogenic changes in a family with oculopharyngeal muscular dystrophy. *Neuropathology*. 2001;21:45–52. PubMed PMID: 11304042.

- Schotland DL, Rowland LP. Muscular dystrophy. Features of ocular myopathy, distal myopathy, and myotonic dystrophy. *Arch Neurol.* 1964;10:433–45. PubMed PMID: 14120634.
- Scrimgeour EM, Mastaglia FL. Oculopharyngeal and distal myopathy: a case study from Papua New Guinea. *Am J Med Genet.* 1984;17:763–71. PubMed PMID: 6720743.
- Shahrizaila N, Kinnear WJ, Wills AJ. Respiratory involvement in inherited primary muscle conditions. *J Neurol Neurosurg Psychiatry.* 2006;77:1108–15. PubMed PMID: 16980655.
- Shan J, Chen B, Lin P, Li D, Luo Y, Ji K, Zheng J, Yuan Y, Yan C. Oculopharyngeal muscular dystrophy: phenotypic and genotypic studies in a Chinese population. *Neuromolecular Med.* 2014;16:782–6. PubMed PMID: 25283883.
- Silbergleit AK, Schultz L, Jacobson BH, Beardsley T, Johnson AF. The dysphagia handicap index: development and validation. *Dysphagia.* 2012;27:46–52. PubMed PMID: 21424584.
- St Guily JL, Moine A, Périé S, Bokowy C, Angelard B, Chaussade S. Role of pharyngeal propulsion as an indicator for upper esophageal sphincter myotomy. *Laryngoscope.* 1995;105:723–7. PubMed PMID: 7603277.
- St Guily JL, Périé S, Willig TN, Chaussade S, Eymard B, Angelard B. Swallowing disorders in muscular diseases: functional assessment and indications of cricopharyngeal myotomy. *Ear Nose Throat J.* 1994;73:34–40. PubMed PMID: 8162870.
- Tabor LC, Plowman EK, Romero-Clark C, Youssof S. Oropharyngeal dysphagia profiles in individuals with oculopharyngeal muscular dystrophy. *Neurogastroenterol Motil.* 2018;30:e13251. PubMed PMID: 29144056.
- Tomé F, Fardeau M. Oculopharyngeal muscular dystrophy. In: *Myology*. New York, NY: McGraw-Hill; 1994:1233–45.
- Tomé FM, Chateau D, Helbling-Leclerc A, Fardeau M. Morphological changes in muscle fibers in oculopharyngeal muscular dystrophy. *Neuromuscul Disord.* 1997;7:S63–9. PubMed PMID: 9392019.
- Tomé FM, Fardeau M. Nuclear inclusions in oculopharyngeal dystrophy. *Acta Neuropathol (Berl).* 1980;49:85–7. PubMed PMID: 6243839.
- Tondo M, Gámez J, Gutiérrez-Rivas E, Medel-Jiménez R, Martorell L. Genotype and phenotype study of 34 Spanish patients diagnosed with oculopharyngeal muscular dystrophy. *J Neurol.* 2012;259:1546–52. PubMed PMID: 22231868.
- van der Sluijs BM, Knoop H, Bleijenberg G, van Engelen BG, Voermans NC. The Dutch patients' perspective on oculopharyngeal muscular dystrophy: A questionnaire study on fatigue, pain and impairments. *Neuromuscul Disord.* 2016;26:221–6. PubMed PMID: 26948710.
- Verheesen P, de Kluijver A, van Koningsbruggen S, de Brij M, de Haard HJ, van Ommen GJ, van der Maarel SM, Verrrips CT. Prevention of oculopharyngeal muscular dystrophy-associated aggregation of nuclear polyA-binding protein with a single-domain intracellular antibody. *Hum Mol Genet.* 2006;15:105–11. PubMed PMID: 16319127.
- Vest KE, Phillips BL, Banerjee A, Apponi LH, Dammer EB, Xu W, Zheng D, Yu J, Tian B, Pavlath GK, Corbett AH. Novel mouse models of oculopharyngeal muscular dystrophy (OPMD) reveal early onset mitochondrial defects and suggest loss of PABPN1 may contribute to pathology. *Hum Mol Genet.* 2017;26:3235–52. PubMed PMID: 28575395.
- Victor M, Hayes R, Adams RD. Oculopharyngeal muscular dystrophy. A familial disease of late life characterized by dysphagia and progressive ptosis of the eyelids. *N Engl J Med.* 1962;267:1267–72. PubMed PMID: 13997067.
- Vita G, Dattola R, Santoro M, Messina C. Familial oculopharyngeal muscular dystrophy with distal spread. *J Neurol.* 1983;230:57–64. PubMed PMID: 6194273.

- Waito AA, Steele CM, Peladeau-Pigeon M, Genge A, Argov Z. A Preliminary videofluoroscopic investigation of swallowing physiology and function in individuals with oculopharyngeal muscular dystrophy (OPMD). *Dysphagia*. 2018;33:789–802. PubMed PMID: 29725764.
- Wang Q, Mosser DD, Bag J. Induction of HSP70 expression and recruitment of HSC70 and HSP70 in the nucleus reduce aggregation of a polyalanine expansion mutant of PABPN1 in HeLa cells. *Hum Mol Genet*. 2005;14:3673–84. PubMed PMID: 16239242.
- Witting N, Mensah A, Kober L, Bundgaard H, Petri H, Duno M, et al. Ocular, bulbar, limb, and cardiopulmonary involvement in oculopharyngeal muscular dystrophy. *Acta Neurol Scand*. 2014;130:125–30. PubMed PMID: 24611576.

License

GeneReviews® chapters are owned by the University of Washington. Permission is hereby granted to reproduce, distribute, and translate copies of content materials for noncommercial research purposes only, provided that (i) credit for source (<http://www.genereviews.org/>) and copyright (© 1993-2024 University of Washington) are included with each copy; (ii) a link to the original material is provided whenever the material is published elsewhere on the Web; and (iii) reproducers, distributors, and/or translators comply with the [GeneReviews® Copyright Notice and Usage Disclaimer](#). No further modifications are allowed. For clarity, excerpts of GeneReviews chapters for use in lab reports and clinic notes are a permitted use.

For more information, see the [GeneReviews® Copyright Notice and Usage Disclaimer](#).

For questions regarding permissions or whether a specified use is allowed, contact: admasst@uw.edu.