U.S. National Library of Medicine
National Center for Biotechnology Information

NLM Citation: Hehr U, Uyanik G, Aigner L, et al. *DCX*-Related Disorders. 2007 Oct 19 [Updated 2019 Feb 7]. In: Adam MP, Feldman J, Mirzaa GM, et al., editors. GeneReviews® [Internet]. Seattle (WA): University of Washington, Seattle; 1993-2024.
Bookshelf URL: https://www.ncbi.nlm.nih.gov/books/

DCX-Related Disorders

Ute Hehr, MD,[1] Gökhan Uyanik, MD,[2] Ludwig Aigner, PhD,[3] Sebastien Couillard-Despres, PhD,[3] and Jürgen Winkler, MD[4]

Created: October 19, 2007; Updated: February 7, 2019.

Summary

Clinical characteristics

DCX-related disorders include the neuronal migration disorders:

- Classic thick lissencephaly (more severe anteriorly), usually in males
- Subcortical band heterotopia (SBH), primarily in females

Males with classic *DCX*-related lissencephaly typically have early and profound cognitive and language impairment, cerebral palsy, and epileptic seizures. The clinical phenotype in females with SBH varies widely with cognitive abilities that range from average or mild cognitive impairment to severe intellectual disability and language impairment. Seizures, which frequently are refractory to anti-seizure medication, may be either focal or generalized and behavioral problems may also be observed.

In *DCX*-related lissencephaly and SBH the severity of the clinical manifestation correlates roughly with the degree of the underlying brain malformation as observed in cerebral imaging.

Diagnosis/testing

The diagnosis of a *DCX*-related disorder is established in a proband by identification of a *DCX* pathogenic variant on molecular genetic testing.

Management

Treatment of manifestations: Anti-seizure medication for epileptic seizures; deep brain stimulation may improve the seizure disorder in individuals with SBH; special feeding strategies in newborns with poor suck; physical therapy to promote mobility and prevent contractures; special adaptive chairs or positioners as needed;

Author Affiliations: 1 Center for Human Genetics, Regensburg, Germany; Email: ute.hehr@klinik.uni-regensburg.de. 2 Center for Medical Genetics, Hanusch Hospital, Medical Faculty, Sigmund Freud Private University, Vienna, Austria; Email: goekhan.uyanik@wgkk.at; goekhan.uyanik@med.sfu.ac.at. 3 Institute of Molecular Regenerative Medicine, Paracelsus Medical University Salzburg, Salzburg, Austria; Email: ludwig.aigner@pmu.ac.at; Email: s.couillard-despres@pmu.ac.at. 4 Division of Molecular Neurology, University Hospital Erlangen, Erlangen, Germany; Email: juergen.winkler@uk-erlangen.de.

Copyright © 1993-2024, University of Washington, Seattle. GeneReviews is a registered trademark of the University of Washington, Seattle. All rights reserved.

occupational therapy to improve fine motor skills and oral-motor control; participation in speech therapy, educational training, and enrichment programs.

Surveillance: Regular neurologic examination and monitoring of seizure activity, EEG, and anti-seizure drug levels; regular measurement of height, weight, and head circumference; evaluation of feeding and nutrition status; assessment of psychomotor, speech, and cognitive development; prompt consultation in the event of novel neurologic findings or deterioration, aspiration, or infections; monitoring for orthopedic complications such as foot deformity or scoliosis.

Genetic counseling

DCX-related disorders are inherited in an X-linked manner. Up to10% of unaffected mothers of children with a *DCX* pathogenic variant are presumed to have germline mosaicism with or without somatic mosaicism. A woman who is heterozygous for a *DCX* pathogenic variant has a 50% chance of transmitting the pathogenic variant in each pregnancy. Hemizygous male offspring usually manifest *DCX*-related classic lissencephaly, while heterozygous female offspring may be asymptomatic or more frequently manifest a wide phenotypic spectrum of SBH. If the pathogenic variant has been identified in the family, testing to determine the genetic status of at-risk family members and prenatal testing for pregnancies at increased risk are possible.

GeneReview Scope

DCX-Related Disorders: Included Phenotypes [1]
• Lissencephaly • Subcortical band heterotopia

For synonyms and outdated names see Nomenclature.
1. For other genetic causes of these phenotypes, see Differential Diagnosis.

Diagnosis

DCX-related disorders are X-linked conditions involving abnormal neuronal migration; they include:

- Classic lissencephaly, usually in males
- Subcortical band heterotopia (SBH), primarily in females

Suggestive Findings

A *DCX*-related disorder **should be suspected** in individuals with characteristic findings in brain magnetic resonance imaging (MRI) in combination with epileptic seizures and/or developmental delay or behavioral problems. A family history consistent with X-linked inheritance is an additional supportive finding.

Brain MRI Findings

Classic thick lissencephaly, usually in males:

- Is typically characterized by agyria (sulci >30 mm apart) or pachygyria (abnormally wide gyri with sulci 15-30 mm apart) with thickened cortex of ~10-20 mm (normal: ~4 mm) (Figure 1B-C) [Mutch et al 2016, Di Donato et al 2017];
- Is more severe anteriorly, referred to as an anterior-to-posterior (A>P) gradient;
- May be accompanied by:
  - Prominent perivascular (Virchow-Robin) spaces
  - Delayed myelination
  - Enlarged ventricles particularly affecting the anterior horns of the lateral ventricles

- Normal or diffusely thin corpus callosum
- No obvious cerebellar or brain stem abnormalities
- Enlarged caudate head
- Mildly to moderately diminished cerebral white matter.

Subcortical band heterotopia (SBH), usually in females, is characterized by one or more of the following:

- Symmetric, usually bilateral bands of gray matter within the white matter between and parallel to the cortex and the lateral ventricles appearing as an isointense second cortical structure beneath the cortex (double cortex) and separated from the cortex by a thin layer of normal-appearing white matter. The heterotopic band is more often thick (~70%) than thin (1-7 mm) (Figure 1A) [Bahi-Buisson et al 2013, Di Donato et al 2017].
- Normal-appearing and/or thickened cerebral cortex with or without simplified gyration
- Predominant location in the frontoparietal lobe region

Clinical Features

Findings may include:

- Intellectual disability
- Language impairment
- Psychomotor delay
- Behavioral disturbances
- Seizures
- Microcephaly

Family History

Evidence for X-linked inheritance may be obtained from a detailed family history. Special attention should be paid to epilepsy, miscarriages, stillbirths, children, who died at a young age without conclusive diagnosis, and cognitive impairment or developmental delay.

Establishing the Diagnosis

The diagnosis of a *DCX*-related disorder **is established** in a proband by identification of one of the following on molecular genetic testing (see Table 1):

- A hemizygous *DCX* pathogenic (or likely pathogenic) variant in a male proband
- A heterozygous *DCX* pathogenic (or likely pathogenic) variant in a female proband

Note: (1) Per ACMG/AMP variant interpretation guidelines, the terms "pathogenic variant" and "likely pathogenic variant" are synonymous in a clinical setting, meaning that both are considered diagnostic and can be used for clinical decision making [Richards et al 2015]. Reference to "pathogenic variants" in this *GeneReview* is understood to include likely pathogenic variants. (2) Identification of a hemizygous or heterozygous *DCX* variant of uncertain significance does not establish or rule out the diagnosis.

Molecular genetic testing approaches can include a combination of **gene-targeted testing** (single-gene testing, multigene panel) and **comprehensive genomic testing** (exome sequencing, exome array, genome sequencing) depending on the phenotype.

Gene-targeted testing requires that the clinician determine which gene(s) are likely involved, whereas genomic testing does not. Because the phenotype of *DCX*-related disorders is broad, individuals with the distinctive brain MRI findings described in Suggestive Findings are likely to be diagnosed using gene-targeted testing (see Option

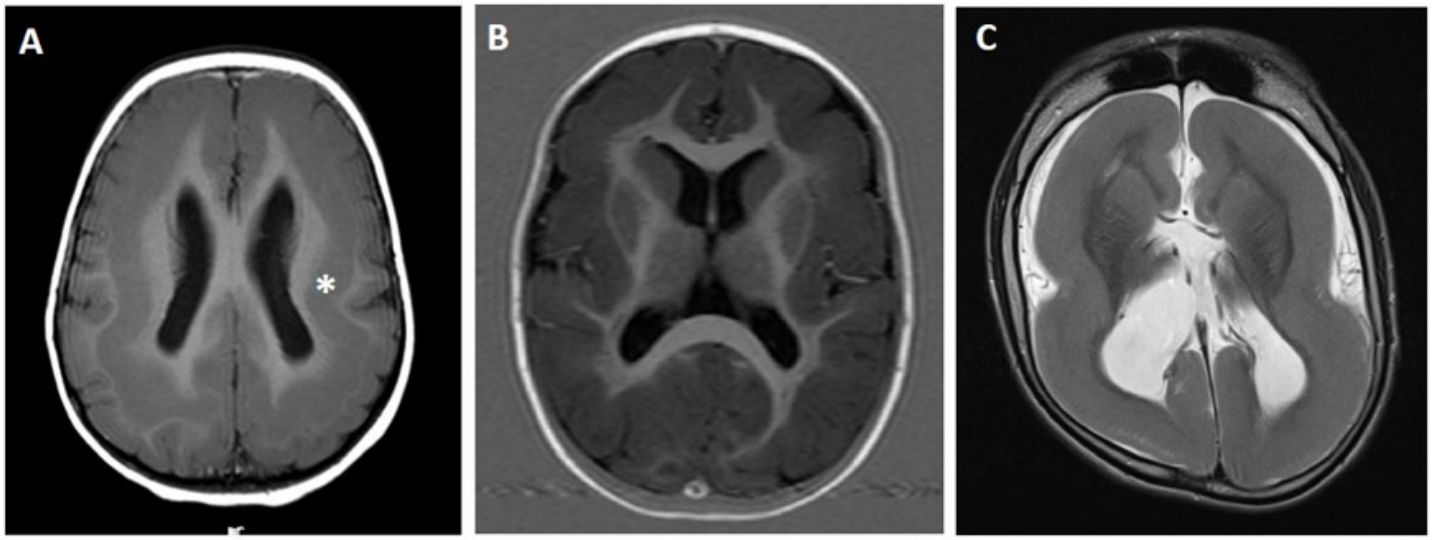

Figure 1. Cerebral MRI of three individuals with *DCX*-related disorders

A. Characteristic bilateral subcortical band heterotopia (*) in a female with heterozygous *DCX* exon deletion

B-C. Classic thick lissencephaly in two males with hemizygous *DCX* missense variants: (B) anterior predominant pachygyria (A>P gradient); (C) agyria

1), whereas those with insufficient clinical and imaging data in whom the diagnosis of a *DCX*-related disorder has not been considered are more likely to be diagnosed using genomic testing (see Option 2).

Option 1

When the phenotypic and laboratory findings suggest the diagnosis of a *DCX*-related disorder molecular genetic testing approaches can include **single-gene testing** or use of a **multigene panel**:

- **Single-gene testing.** Sequence analysis of *DCX* detects missense, nonsense, and splice site variants and small intragenic deletions/insertions. Typically exon or whole-gene deletions/duplications in females are not detected; however, a deletion may result in PCR failure in a male. Perform sequence analysis first. If no pathogenic variant is found perform gene-targeted deletion/duplication analysis to detect intragenic deletions or duplications.
- **A multigene panel** that includes *DCX* and other genes of interest (see Differential Diagnosis) is most likely to identify the genetic cause of the condition while limiting identification of variants of uncertain significance and pathogenic variants in genes that do not explain the underlying phenotype. Note: (1) The genes included in the panel and the diagnostic sensitivity of the testing used for each gene vary by laboratory and are likely to change over time. (2) Some multigene panels may include genes not associated with the condition discussed in this *GeneReview*. (3) In some laboratories, panel options may include a custom laboratory-designed panel and/or custom phenotype-focused exome analysis that includes genes specified by the clinician. (4) Methods used in a panel may include sequence analysis, deletion/duplication analysis, and/or other non-sequencing-based tests.
- For this disorder a multigene panel that also includes deletion/duplication analysis is recommended (see Table 1).

  For an introduction to multigene panels click here. More detailed information for clinicians ordering genetic tests can be found here.

Option 2

Due to phenotypic overlap with other inherited neuronal migration disorders, **comprehensive genomic testing** (which does not require the clinician to determine which gene[s] are likely involved) is the best option especially in the absence of sufficient clinical and imaging data. **Exome sequencing** is most commonly used; **genome sequencing** is also possible.

Exome array (when clinically available) may be considered if exome sequencing is not diagnostic.

For an introduction to comprehensive genomic testing click here. More detailed information for clinicians ordering genomic testing can be found here.

Note: Somatic mosaicism is a common finding in *DCX*-related disorders [D'Agostino et al 2002, Aigner et al 2003, Quélin et al 2012, Jamuar et al 2014, Tsai et al 2016, González-Morón et al 2017]. Sequence analysis methods, such as Sanger or next-generation sequencing, vary in their ability to detect mosaicism and should be evaluated for their detection rate. Due to assay sensitivity, the proportion of somatic mosaicism in both affected individuals and parents may be underestimated. Analysis of DNA from different tissues (e.g., hair roots, buccal swabs) can be useful in the detection or confirmation of somatic mosaicism.

Table 1. Molecular Genetic Testing Used in *DCX*-Related Disorders

Gene [1]	Method	Proportion of Pathogenic Variants [2] Identified by Method
DCX	Sequence analysis [3]	96% [4]
	Gene-targeted deletion/duplication analysis [5]	4% [4]
	Karyotype	Single case [6]

1. See Table A. Genes and Databases for chromosome locus and protein.
2. See Molecular Genetics for information on variants detected in this gene.
3. Sequence analysis detects variants that are benign, likely benign, of uncertain significance, likely pathogenic, or pathogenic. Variants may include missense, nonsense, and splice site variants and small intragenic deletions/insertions; typically, exon or whole-gene deletions/duplications are not detected. For issues to consider in interpretation of sequence analysis results, click here.
4. Matsumoto et al [2001]; Hoischen et al [2009]; Bahi-Buisson et al [2013]; Authors, unpublished data
5. Gene-targeted deletion/duplication analysis detects intragenic deletions or duplications. Methods used may include a range of techniques such as quantitative PCR, long-range PCR, multiplex ligation-dependent probe amplification (MLPA), and a gene-targeted microarray designed to detect single-exon deletions or duplications.
6. Gleeson et al [1998] reported a balanced X:2 translocation in a female which disrupted DCX between the first two coding exons.

Clinical Characteristics

Clinical Description

An individual with a *DCX*-related disorder usually presents with epileptic seizures and/or developmental delay and behavioral disturbances [Matsumoto et al 2001, Bahi-Buisson et al 2013] and with the characteristic findings on brain MRI noted during clinical evaluation.

Males

DCX-related classic lissencephaly usually manifests with early and profound cognitive and language impairment, cerebral palsy, and epileptic seizures.

Development. Severity of symptoms usually correlates with the degree of the underlying brain malformation observed in cerebral imaging.

Motor development is compromised, but overall better than in patients with *PAFAH1B1*-associated classic lissencephaly.

Leger et al [2008] reported on the development of 33 males with *DCX*-related lissencephaly:

- At a median age of 7.5 years (range 1.5-37 years) almost half were reported to walk independently, the remaining individuals showed moderate to severe motor impairment.
- Almost half of the individuals in the study did not develop any speech.

Behavioral disturbances may include agitation and irritability or autistic features.

Epileptic seizures occur in more than 80% of affected males and commonly start within the first year. The observed seizure pattern may include multiple seizure types, frequently with infantile spasms with or without characteristic hypsarrhythmia [Leger et al 2008, Dobyns 2010]. Seizure control remains insufficient in more than half of the affected individuals [Bahi-Buisson et al 2013].

Other findings

- Disturbed muscle tone and immobility may result in contractures and scoliosis.
- More severe clinical manifestations may also affect feeding and swallowing, thus resulting in insufficient nutrition or aspiration.
- Head circumference may decline postnatally and result in postnatal microcephaly.

Life span. Individuals with severe classic lissencephaly may survive into adulthood. However, life span overall is shortened due to complications either directly related to the seizure disorder (including sudden unexplained death in epilepsy or in the course of a developing epileptic encephalopathy), or resulting from disturbed cerebral regulation of vital functions (e.g., breathing abnormalities) or aspiration during respiratory infections or associated with food intake.

The rare male with the milder cerebral manifestation of subcortical band heterotopia (SBH) has findings similar to those in females with SBH [D'Agostino et al 2002, Aigner et al 2003].

Females

The SBH clinical phenotype in heterozygous females is markedly milder than the classic lissencephaly clinical phenotype in males, very variable, and roughly correlated with the extent and thickness of the subcortical band as observed in cerebral imaging.

Bahi-Buisson et al [2013] proposed two distinct subgroups among females with *DCX* pathogenic variants: a more severe clinical phenotype usually observed in sporadic cases and a milder phenotype mainly observed in heterozygous asymptomatic females with normal cerebral MRI or only thin frontal subcortical bands.

Severe phenotype associated with thicker SBH typically includes:

- Developmental delay
- Moderate-to-severe intellectual disability
- Severe language impairment
- Behavioral problems
- Seizures (frequently refractory to anti-seizure medication) that may be either focal or generalized (~50% each) and in more severe cases eventually progress to Lennox-Gastaut syndrome [Dobyns 2010]

Mild phenotype associated with thin frontal band heterotopia or normal-appearing cerebral MRI may include:

- Average or mildly impaired cognitive skills [Guerrini et al 2003]
- No additional symptoms

- Recognition only after prenatal or postnatal diagnosis of a *DCX*-related disorder in an offspring or other family member

As in other X-linked disorders, X-chromosome inactivation has been postulated to contribute to inter- and intrafamilial phenotypic variability in females heterozygous for a *DCX* pathogenic variant. As an example, such variability has been observed in monozygous female twins heterozygous for a recurrent *DCX* nonsense variant [Martin et al 2004]. Both twins had thick generalized SBH, clearly delineated from the cortex by a small band of white matter. However, one twin had a broader heterotopic band than the other including frontal pachygyria associated with more profound cognitive and psychomotor impairment and a more abnormal EEG than observed in her twin sister.

Somatic Mosaicism

Somatic mosaicism for *DCX* pathogenic variants has been repeatedly documented in both females and males with milder manifestations [D'Agostino et al 2002, Aigner et al 2003, Bahi-Buisson et al 2013, Jamuar et al 2014].

Pathophysiology

In hemizygous males all neurons express the pathogenic variant and are disturbed in their migratory properties, leading to the smoothened and disorganized thickened cortex observed in classic lissencephaly.

In females heterozygous for a *DCX* pathogenic variant, inactivation of one of the two X chromosomes in neural/somatic cells is thought to result in two neuronal populations [Forman et al 2005, Marcorelles et al 2010, Wynshaw-Boris et al 2010]:

- Cells expressing the wild type allele that continue and complete their migratory process to form the normal cortex
- Cells expressing the pathogenic variant that accumulate in the white matter between the cortex and lateral ventricles as a heterotopic band of neurons

Genotype-Phenotype Correlations

About one third of all *DCX* pathogenic variants are recurrent, resulting in rather similar pathogenic variant-specific cortical phenotypes in and between families [Bahi-Buisson et al 2013].

A slight effect of the type and location of the *DCX* pathogenic variant on the resulting severity of the brain malformation for both SBH and classic lissencephaly has been suggested [Leventer 2005, Bahi-Buisson et al 2013].

- *DCX* pathogenic nonsense variants in males are very rare and have mainly been observed as postzygotic mosaic events.
- Loss-of-function variants are more likely to occur in simplex cases (i.e., a single occurrence in a family); missense variants are more likely to be observed in familial cases [Gleeson et al 1999, Leger et al 2008, Bahi-Buisson et al 2013].
- Hemizygous *DCX* missense variants within the N-terminal DC tandem repeat domain tend to result in more severe forms of lissencephaly than missense variants in the C-DC domain.
- Truncating variants were more frequently associated with generalized subcortical bands; missense variants were more commonly associated with frontal band heterotopia only [Matsumoto et al 2001, Leventer 2005, Leger et al 2008, Haverfield et al 2009].
- *DCX*-related SBH in males appears to result predominantly from either mosaicism for a *DCX* pathogenic variant or specific missense variants with residual function [Leger et al 2008].

For further information on postulated functional consequences of various *DCX* pathogenic missense variants and the observed clinical manifestations in male and female patients see Bahi-Buisson et al [2013].

Penetrance

Males

- No instances of asymptomatic males with germline hemizygous *DCX* pathogenic variants have been reported, thus suggesting full penetrance of germline *DCX* pathogenic variants in males.
- Males with postzygotic mosaic pathogenic variants may have milder clinical manifestations or, in rare cases, be asymptomatic (see Clinical Description, Somatic Mosaicism).

Females

- Heterozygous females with germline missense or nonsense *DCX* variants may have no obvious brain malformation or seizures [Aigner et al 2003, Guerrini et al 2003].
- Penetrance was reported to be less than 50% in the mothers with a heterozygous or mosaic pathogenic variant in *DCX* whose children presented with *DCX*-related disorders [Bahi-Buisson et al 2013].

Nomenclature

Classic lissencephaly may also be called lissencephaly type 1. In the absence of associated intra- or extracranial malformations it is also termed isolated lissencephaly sequence.

Classic lissencephaly that occurs in combination with cerebellar hypoplasia is classified as lissencephaly with cerebellar hypoplasia.

Classic lissencephaly is morphologically and etiologically distinct from lissencephaly type 2, which is also called cobblestone lissencephaly, and from thin lissencephaly.

To emphasize their X-linked inheritance, *DCX*-related lissencephaly and SBH have variably been termed and abbreviated:

- X-linked lissencephaly (XLIS)
- Lissencephaly, X-linked (LISX)
- Isolated lissencephaly, X-linked (ILSX)
- Subcortical laminar heterotopia, X-linked (X-SCLH)
- Subcortical band heterotopia, X-linked (SBHX)

DCX-related lissencephaly and SBH have also been referred to as double cortex syndrome.

Prevalence

The incidence of all forms of type 1 lissencephaly has been estimated at 1:100,000 births [Orphanet], with the majority resulting from heterozygous pathogenic variants of *PAFAH1B1* (*LIS1*). No specific data on the prevalence of lissencephaly due to pathogenic variants in *DCX* are available.

DCX-related disorders account for:

- Virtually all families with X-linked inheritance of classic lissencephaly and/or SBH;
- About 10% of all persons with classic lissencephaly (38% of all males, but only rare females);
- About 53%-85% of all SBH, about 80% of sporadic SBH, and about 29% of SBH in males [Pilz et al 1998, Gleeson et al 1999, Matsumoto et al 2001, Guerrini & Filippi 2005].

Genetically Related (Allelic) Disorders

No phenotypes other than those discussed in this *GeneReview* are known to be associated with pathogenic variants in *DCX*.

Differential Diagnosis

See Tables 2a, 2b, and 2c for disorders to consider in the differential diagnosis of *DCX*-related disorders.

Table 2a. Disorders with Lissencephaly-Pachygyria with Classic or Thick Lissencephaly (cortex 10-20 mm) to Consider in the Differential Diagnosis

Disorder	Gene(s)	MOI	Clinical Features Differentiating This Disorder from *DCX* Disorders
PAFAH1B1-associated lissencephaly	*PAFAH1B1*	AD	• Most frequent cause of classic or thick lissencephaly • More prominent in the posterior regions of the brain, w/a P>A gradient (*DCX*-related lissencephaly presents w/an A>P gradient.) [1]
Miller-Dieker syndrome	Microdeletion of 17p13.3 [2]	AD	• Distinctive facial features (i.e., prominent forehead, bitemporal hollowing, short nose w/upturned tip & anteverted nostrils, & protuberant upper lip w/thin vermilion border) • Cardiac malformations & omphalocele also reported as rare associated extracerebral manifestations [3]
TUBA1A-related lissencephaly (See Tubulinopathies Overview.)	*TUBA1A*	AD	• Tubulinopathy-related dysgyria as more complex cortical phenotype incl areas w/polymicrogyria-like appearance or simplified gyral pattern • Small brain stem, cerebellar vermis &/or cerebellar hemispheres, dysmorphic or absent corpus callosum, anterior limb of the capsula interna not delineated, large tectum [4]
DYNC1H1-related pachygyria (See *DYNC1H1*-Related Disorders.)	*DYNC1H1*	AD	Posterior or anterior predominant pachygyria or dysgyria [5]
KIF5C-related pachygyria (OMIM 615282)	*KIF5C*	AD	• Posterior or anterior predominant pachygyria • Severe intrauterine growth retardation • Arthrogryposis • Microcephaly [5]
Baraitser-Winter syndrome (OMIM PS243310)	*ACTB* *ACTG1*	AD	• Thick cortex anterior or central predominant or SBH • Dysmorphic features • Iris or retinal coloboma • Sensoneurinal deafness • Congenital cardiac or renal malformations • Abnormal corpus callosum (short, thick or absent) [6]

Table 2a. continued from previous page.

Disorder	Gene(s)	MOI	Clinical Features Differentiating This Disorder from *DCX* Disorders
CDK5-related lissencephaly (OMIM 616342)	*CDK5*	AR	• Agyria • Agenesis of the corpus callosum • Severe cerebellar & pontine hypoplasia • Dilated subarachnoidal spaces • Dysmorphic facial features, lymphedema, arthrogryposis multiplex • Early lethal [7]

A = anterior; AD = autosomal dominant; AR = autosomal recessive; MOI = mode of inheritance; P = posterior; SBH = subcortical band heterotopia
1. Uyanik et al [2007]
2. Miller-Dieker syndrome is caused by either small cytogenetically visible deletions or FISH-detectable microdeletions of 17p13.3 that include *LIS1* (officially designated as *PAFAH1B1*) and *YWHAE*, and intervening genes.
3. Bruno et al [2010]
4. Bahi-Buisson et al [2014]
5. Poirier et al [2013]
6. Di Donato et al [2016a], Di Donato et al [2016b]
7. Magen et al [2015]

Table 2b. Disorders with Lissencephaly-Pachygyria with Thin Lissencephaly (cortex 5-10 mm) to Consider in the Differential Diagnosis

Disorder	Gene(s)	MOI	Clinical Features Differentiating This Disorder from *DCX* Disorders
X-linked lissencephaly w/ambiguous genitalia (OMIM 300215)	*ARX*	XL	• Temporal predominant thin lissencephaly (6-10 mm) • Agenesis of the corpus callosum • Perinatal encephalopathy w/intractable seizures • Brain stem & cerebellum appear normal • Ambiguous or underdeveloped genitalia • Chronic diarrhea • High lethality in 1st 3 mos of life [1]
RELN-related lissencephaly (OMIM 257320)	*RELN*	AR	• Thin lissencephaly w/A>P gradient • Severe cerebellar hypoplasia [2]
VLDLR-associated cerebellar hypoplasia	*VLDLR*	AR	• Thin lissencephaly w/A>P gradient • Severe cerebellar hypoplasia [2]
CRADD related lissencephaly (OMIM 614499)	*CRADD*	AR	• Anterior predominant thin lissencephaly • Megalencephaly • Normal cerebellum [3]

A = anterior; AR = autosomal recessive; MOI = mode of inheritance; P = posterior; XL = X-linked
1. Uyanik et al [2003], Coman et al [2017]
2. Valence et al [2016]
3. Di Donato et al [2016a], Di Donato et al [2016b]

Table 2c. Disorders with Subcortical Band Heterotopia to Consider in the Differential Diagnosis

Disorder	Gene(s)	MOI	Clinical Features Differentiating This Disorder from *DCX* Disorders
PAFAH1B1-associated subcortical band heterotopia	*PAFAH1B1*	AD	More prominent in the posterior regions of the brain, w/a P>A gradient (*DCX*-related SBH presents w/an A>P gradient.) [1]
Baraitser-Winter syndrome (OMIM 243310, 614583)	*ACTB* *ACTG1*	AD	• Short central regions of SBH adjacent to frontal pachygyria • Dysmorphic features • Iris or retinal coloboma • Sensoneurinal deafness • Congenital cardiac or renal malformations • Abnormal corpus callosum (short; thick or absent) [2]

A = anterior; AD = autosomal dominant; MOI = mode of inheritance; P = posterior; SBH = subcortical band heterotopia
1. Uyanik et al [2007]
2. Di Donato et al [2016a], Di Donato et al [2016b]

Other disorders to consider include those with cobblestone lissencephaly (i.e., Walker-Warburg syndrome, muscle eye brain disease [see OMIM PS236670], and Fukuyama congenital muscular dystrophy) as well as tubulinopathies (see Tubulinopathies Overview), disorders with polymicrogyria, and disorders with periventricular nodular heterotopia (see *FLNA*-Related Periventricular Nodular Heterotopia).

Management

Evaluations Following Initial Diagnosis

To establish the individual clinical manifestation of a *DCX*-related disorder, the following evaluations are recommended if they have not already been completed:

- Neurologic evaluation, including EEG and cerebral MRI. This is best performed by a pediatric neurologist or neurologist with special expertise in the diagnosis, treatment, and surveillance of individuals with multiple disabilities and difficult-to-treat seizures
- Developmental evaluation including motor skills, cognition, and speech
- Growth and head circumference
- Nutrition and feeding evaluation (including a swallowing assessment in individuals lacking head control or the ability to sit unsupported) to enable early recognition of malnutrition or risk constellations for aspiration that would require special medical surveillance or measures (e.g., tube feeding)
- Ophthalmologic evaluation for impaired vision, potentially correctable by glasses
- Consultation with a clinical geneticist and/or genetic counselor

Treatment of Manifestations

Epileptic seizures require anti-seizure medication. Individual treatment strategies should be based on the type and frequency of seizures, EEG results, and responsiveness.

Surgical resection of heterotopic brain tissue has been tried in only a few individuals with SBH; overall it has not been effective in reducing seizure activity and thus is not recommended [Bernasconi et al 2001]. More recently, deep brain stimulation has been suggested to improve the seizure disorder in individuals with SBH based on first results in small treated cohorts [Franco et al 2016].

In addition, appropriate interdisciplinary management should start at the time of diagnosis and can prolong survival and improve quality of life for individuals with a *DCX*-related disorder:

- Feeding problems in newborns may require special strategies including placement of a percutaneous endoscopic gastrostomy tube to deal with weak or uncoordinated sucking.
- Physical therapy helps to maintain and promote mobility and prevent contractures. Special adaptive chairs or positioners or other measures may support sitting and mobility.
- Occupational therapy may help improve fine motor skills and oral motor control.
- Speech therapy may improve communication
- A full range of educational training and enrichment programs should be available.
- Parents should be informed early and repeatedly on the common presentation and appropriate management of seizures. For parents of individuals with a severe manifestation of a *DCX*-related disorder this should also include appropriate discussion of the level of care in sudden critical situations.
- For information on non-medical interventions and coping strategies for parents or caregivers of children with seizure disorders see Epilepsy Foundation Toolbox.

Prevention of Secondary Complications

Adequate anti-seizure treatment is important to reduce the number of seizures, which may be associated with irreversible and life-threatening complications.

Surveillance

The following are appropriate:

- Regular neuropediatric or neurologic examination including monitoring of seizure activity, EEG, and anti-seizure medication levels
- Regular measurement of height, weight, and head circumference; evaluation of feeding and nutrition status; assessment of psychomotor, speech, and cognitive development
- Prompt neuropediatric, neurologic, or pediatric consultation in the event of novel neurologic findings or deterioration, aspiration, or infections
- Monitoring of orthopedic complications including foot deformity and scoliosis

Evaluation of Relatives at Risk

See Genetic Counseling for issues related to testing of at-risk relatives for genetic counseling purposes.

Pregnancy Management

For pregnant women with *DCX*-related SBH and known history of seizures or current epileptic seizures, close medical surveillance by a neurologist familiar with the treatment of seizures (preferably at an epilepsy center) is recommended.

Counseling should include discussion of the teratogenic risks associated with the currently used anti-seizure medication. For some anti-seizure medications or their combination, a substantially increased risk for fetal malformations may prompt reconsideration of the dosage or drug combination. Pregnant women should, however, be encouraged to continue medical seizure control under close surveillance and be informed about the risks associated with discontinuation of treatment.

Counseling should also cover the preferred mode of delivery based on the current neurologic findings as well as any recommended postnatal measures for the newborn related to fetal medication exposure and its postnatal drop.

Whenever possible, women should discuss the current anti-seizure medication or any recommended replacement of medication with higher teratogenic potential prior to any planned pregnancy.

See MotherToBaby for further information on medication use during pregnancy.

Therapies Under Investigation

Search ClinicalTrials.gov in the US and EU Clinical Trials Register in Europe for information on clinical studies for a wide range of diseases and conditions. Note: There may not be clinical trials for this disorder.

Genetic Counseling

Genetic counseling is the process of providing individuals and families with information on the nature, mode(s) of inheritance, and implications of genetic disorders to help them make informed medical and personal decisions. The following section deals with genetic risk assessment and the use of family history and genetic testing to clarify genetic status for family members; it is not meant to address all personal, cultural, or ethical issues that may arise or to substitute for consultation with a genetics professional. —ED.

Mode of Inheritance

DCX-related disorders are inherited in an X-linked manner.

Risk to Family Members

Parents of a proband

- A female proband may have the disorder as the result of a *de novo DCX* pathogenic variant or have inherited a *DCX* pathogenic variant from:
  - An asymptomatic or only mildly affected mother; about half of identified heterozygous mothers appear clinically unaffected [Bahi-Buisson et al 2013]; asymptomatic heterozygous females without obvious structural changes of the brain have been reported [Demelas et al 2001, Aigner et al 2003].
  - An asymptomatic or mildly affected father with somatic and germline mosaicism [Moreira et al 2015].
- A male proband may either have the disorder as the result of a *de novo DCX* pathogenic variant or have inherited the *DCX* pathogenic variant from an asymptomatic or only mildly affected mother. Note: The father of an affected male will not have the disorder nor will he have somatic mosaicism or be hemizygous for the *DCX* pathogenic variant; therefore, he does not require further evaluation/testing.
- The parents of approximately 90% of female probands and 25% of male probands are clinically unaffected. The *DCX* pathogenic variants in these probands may be either *de novo* or inherited from an asymptomatic heterozygous or mosaic parent.
- In a family with more than one affected individual, the mother of an affected male either is heterozygous or – if the *DCX* pathogenic variant cannot be detected in her leukocyte DNA and she has more than one affected child and no other affected relatives – she most likely has germline mosaicism. Preliminary data suggest that as many as 10% of unaffected mothers of probands with a *DCX* pathogenic variant may have germline mosaicism with or without somatic mosaicism [Gleeson et al 2000].
- Molecular genetic testing of the mother for the *DCX* pathogenic variant identified in a male or female proband is recommended. If the *DCX* pathogenic variant is not identified in maternal leukocyte DNA, additional maternal tissues (e.g., buccal swabs) may be examined for the *DCX* pathogenic variant identified in her offspring. In addition, the possibility of maternal somatic mosaicism could be assessed by neurologic and/or clinical examination of the mother and brain MRI to search for subcortical band heterotopia (SBH).
- If the *DCX* pathogenic variant of a female proband is not identified in her mother, genetic testing (with sufficient sensitivity to uncover rare paternal somatic mosaicism) of paternal leukocyte DNA and additional paternal tissues for the *DCX* pathogenic variant may be considered.

Sibs of a proband. The risk to sibs depends on the clinical/genetic status of the parents:

- If the proband's mother is affected and/or heterozygous for a *DCX* pathogenic variant, the chance of transmitting the *DCX* pathogenic variant in each pregnancy is 50%.
  - Males who inherit the pathogenic variant will usually be affected with *DCX*-related classic lissencephaly.
  - Females who inherit the pathogenic variant will be heterozygous and will be at high risk of developing the variable phenotype associated with SBH.
- If the proband is hemizygous/heterozygous for a *DCX* pathogenic variant and represents a simplex case (i.e., a single occurrence in a family) and if the *DCX* pathogenic cannot be detected in maternal leukocyte DNA:
  - Recurrence risk to sibs of the proband has been estimated between 5%-10% because of the possibility of parental germline mosaicism, mainly in the mother [Gleeson et al 2000, Guerrini & Filippi 2005].
  - Recurrence risk to sibs is also slightly increased by the possibility of paternal transmission of a *DCX* pathogenic variant from an asymptomatic or mildly affected father with somatic and germline mosaicism [Moreira et al 2015].
- If somatic mosaicism for a *de novo DCX* pathogenic variant due to a postzygotic event is suggested based on molecular genetic laboratory results in a proband presenting a simplex case, sibs would not be considered at increased risk.

Offspring of a proband

- Males with classic lissencephaly are usually severely affected and are not known to reproduce; to date, no instances of offspring have been reported.
- Females with a *DCX*-related disorder have a 50% chance of transmitting the pathogenic variant to each child:
  - Males who inherit the pathogenic variant will usually be affected with *DCX*-related classic lissencephaly.
  - Females who inherit the pathogenic variant will be heterozygous and will be at high risk of developing the variable phenotype associated with SBH.
- For male or female probands with mild disease forms resulting from somatic mosaicism for *DCX* pathogenic variants(e.g., SBH in males), recurrence risk depends on the proportion of germ cells with the pathogenic variant and may be as high as the formal risk assumed for the offspring of individuals heterozygous or, theoretically, hemizygous for the pathogenic variant [Moreira et al 2015].

Other family members. The proband's maternal grandmother and maternal aunts are at higher risk of being heterozygous for the familial *DCX* pathogenic variant. The offspring of heterozygous females have a 50% chance of being heterozygous or hemizygous, depending on their sex, for the *DCX* pathogenic variant and developing the respective phenotype.

Note: Molecular genetic testing may be able to identify the family member in whom a *de novo* pathogenic variant arose – information that could help determine genetic risk status of the extended family.

Heterozygote Detection in Asymptomatic Females

Molecular genetic testing of at-risk female relatives to determine their genetic status is most informative if the *DCX* pathogenic variant has been identified in the proband.

Note: (1) Females who are heterozygous for this X-linked disorder or have somatic mosaicism may be clinically unaffected or may present with a wide range of clinical manifestations. (2) Identification of heterozygous females requires either (a) prior identification of the *DCX* pathogenic variant in the family or, (b) if an affected

individual is not available for testing, molecular genetic testing first by sequence analysis, and if no pathogenic variant is identified, by gene-targeted deletion/duplication analysis.

Related Genetic Counseling Issues

X-chromosome inactivation. As in other X-linked disorders, X-chromosome inactivation may further significantly contribute to a wide inter- and intrafamilial phenotypic variability in females heterozygous for the pathogenic variant. However, data obtained from a peripheral blood sample may not represent the proportion of cells with the active mutated *DCX* allele in other tissues. Furthermore, testing for skewed X-chromosome inactivation in any available pre- or postnatal sample is of no value in predicting the clinical manifestations of a heterozygous *DCX* pathogenic variant in any individual.

Family planning

- The optimal time for determination of genetic risk, clarification of genetic status, and discussion of the availability of prenatal/preimplantation genetic testing is before pregnancy.
- It is appropriate to offer genetic counseling (including discussion of potential risks to offspring and reproductive options) to young adults who are affected, are heterozygous, or are at risk of being heterozygous.

DNA banking. Because it is likely that testing methodology and our understanding of genes, pathogenic mechanisms, and diseases will improve in the future, consideration should be given to banking DNA from probands in whom a molecular diagnosis has not been confirmed (i.e., the causative pathogenic mechanism is unknown). For more information, see Huang et al [2022].

Prenatal Testing and Preimplantation Genetic Testing

Molecular genetic testing. Once the *DCX* pathogenic variant has been identified in an affected family member, prenatal and preimplantation genetic testing are possible. Accurate prediction of the expected clinical manifestations in a female fetus prenatally diagnosed as heterozygous for a *DCX* pathogenic variant is not possible. Therefore, prenatal testing of a female fetus should be offered only after thorough discussion with the expecting parents regarding the reduced penetrance and wide phenotypic variability in females heterozygous for a *DCX* pathogenic variant.

Fetal ultrasonography/MRI. During fetal development first gyri appear around the 20th week of gestation, and a reduced gyration pattern (compared to postnatal images) remains physiologic until late gestation. Therefore, in the absence of a positive family history, *DCX*-related classic lissencephaly may not be recognized even during late gestation by fetal sonography; SBH, in most cases, will not be recognized until birth. However, occasional detection of SBH or X-linked lissencephaly by fetal MRI and/or ultrasound examination at later stages of gestation has been reported [Ghai et al 2006].

Note: Gestational age is expressed as menstrual weeks calculated either from the first day of the last normal menstrual period or by ultrasound measurements.

Resources

GeneReviews staff has selected the following disease-specific and/or umbrella support organizations and/or registries for the benefit of individuals with this disorder and their families. GeneReviews is not responsible for the information provided by other organizations. For information on selection criteria, click here.

- **American Association on Intellectual and Developmental Disabilities (AAIDD)**

  Phone: 202-387-1968

aaidd.org

- **American Epilepsy Society**
  aesnet.org
- **Epilepsy Foundation**
  Phone: 800-332-1000; 866-748-8008
  epilepsy.com
- **LISS e.V.**
  Anlaufstelle für Eltern & Angehörige an Lissenzephalie leidender Kinder e.V.
  Germany
  www.lissenzephalie.de

Molecular Genetics

Information in the Molecular Genetics and OMIM tables may differ from that elsewhere in the GeneReview: tables may contain more recent information. —ED.

Table A. DCX-Related Disorders: Genes and Databases

Gene	Chromosome Locus	Protein	Locus-Specific Databases	HGMD	ClinVar
DCX	Xq23	Neuronal migration protein doublecortin	DCX database	DCX	DCX

Data are compiled from the following standard references: gene from HGNC; chromosome locus from OMIM; protein from UniProt. For a description of databases (Locus Specific, HGMD, ClinVar) to which links are provided, click here.

Table B. OMIM Entries for DCX-Related Disorders (View All in OMIM)

300067	LISSENCEPHALY, X-LINKED, 1; LISX1
300121	DOUBLECORTIN; DCX

Molecular Pathogenesis

DCX shares homology with a group of genes that have a conserved doublecortin (DC) domain comprising two tandemly repeated 80-amino acid regions (pep1 and pep2) [Sapir et al 2000, Taylor et al 2000]. This gene family comprises eleven paralogs in human and in mouse and includes genes such as *RP1* (OMIM 603937), associated with a form of retinitis pigmentosa, and *DCDC2* (OMIM 605755), associated with dyslexia [Reiner et al 2006].

Gene structure. *DCX* spans 118 kb of genomic DNA and comprises nine exons including the coding exons 2-7; alternatively spliced exons 1a, 1b, and 1c are untranslated [des Portes et al 1998]. *DCX* transcripts include:

- NM_178153.2; DCX-203 (ENST00000371993.6) – the main isoform; comprising 7 exons including the untranslated exon 1b;
- NM_001195553 – alternative transcript with 18-bp (6-amino acid) insertion between exons 5 and 6 and 3-bp (1-amino acid) insertion between exons 6 and 7 [Gleeson et al 1998].

For a detailed summary of gene and protein information, see Table A, **Gene**.

Pathogenic variants. Disease-causing alleles include missense (~80%) and nonsense variants, frameshifts, intragenic and gene deletions, and small deletions or insertions. The majority of missense variants occur in the two evolutionary conserved domains, the N-terminal N-DC and C-terminal C-DC domains [Gleeson et al 1999, Sapir et al 2000, Leger et al 2008].

Hot spot variants, observed multiple times, account for more than one third of identified sequence variants: p.Arg39Ter, p.Arg303Ter, p.Arg78Cys, p.Arg78His, p.Arg78Leu, p.Arg192Trp, p.Arg186Cys, p.Arg186His, p.Arg186Leu [Bahi-Buisson et al 2013].

To date, males with lissencephaly resulting from a constitutional hemizygous *DCX* whole-gene deletion or hemizygous nonsense variant appear to be extremely rare, suggesting that *DCX* loss-of-function variants are likely lethal [Haverfield et al 2009, Leger et al 2008].

Somatic mosaicism is a frequent finding in *DCX*-related SBH. The detection rate for mosaicism depends on the sensitivity of the testing method used and will further increase with widespread use of next-generation sequencing methodology [Jamuar et al 2014]. Due to the sensitivity of current technologies, the proportion of somatic mosaicism in both affected individuals and parents for deletions or duplications may be underestimated.

In females with two X chromosomes, *DCX* pathogenic variants may not result in characteristic clinical features. To the authors' knowledge, sex-chromosome aneuploidies (e.g., 45,X or 47,XXX or 47,XXY) have not to date been associated with *DCX*-related disorders.

Table 3. *DCX* Pathogenic Variants Discussed in This *GeneReview*

DNA Nucleotide Change	Predicted Protein Change	Reference Sequences
c.115C>T	p.Arg39Ter	NM_178153.2 NP_835366.1
c.232C>T	p.Arg78Cys	
c.233G>A	p.Arg78His	
c.233G>T	p.Arg78Leu	
c.556C>T	p.Arg186Cys	
c.557G>A	p.Arg186His	
c.557G>T	p.Arg186Leu	
c.574C>T	p.Arg192Trp	
c.907C>T	p.Arg303Ter	

Variants listed in the table have been provided by the authors. *GeneReviews* staff have not independently verified the classification of variants.
GeneReviews follows the standard naming conventions of the Human Genome Variation Society (varnomen.hgvs.org). See Quick Reference for an explanation of nomenclature.

Normal gene product. Neuronal migration protein doublecortin (DCX) is a microtubule-binding protein containing two in-tandem-organized microtubule-binding domains, in the so-called DCX domain, not previously described in other microtubule-associated proteins (MAPs). Microtubules constitute a central element of the cytoskeleton and as such play a crucial role in many cellular processes such as cell division, cell migration, and maintenance of cellular morphology. In vitro, DCX can promote microtubule polymerization and stabilization of the microtubules.

DCX associates with the 13-protofilaments microtubules to stabilize them and can even override the nucleotide dependence of microtubule polymerization [Moores et al 2006, Fourniol et al 2010]. DCX is particularly enriched at the end neuronal processes where microtubules enter the growth cone [Friocourt et al 2003]. DCX

also appears to be enriched in axonal regions capable of generating collaterals [Tint et al 2009]. Therefore, DCX is thought to promote elongation and stabilization of the microtubule network during process outgrowth. Moreover, DCX could also be involved in the somal translocation occurring during neuroblast migration and influence the course of neuroblast proliferation.

DCX is a phosphoprotein that can be a substrate for several protein kinases including JNK, PKA, MARK, and Cdk5. Phosphorylation of DCX alters its interaction with microtubules and thereby possibly its function. The impact of DCX phosphorylation on its reported interaction with other proteins, such as LIS1, neurabin II, or clathrin-associated protein μ1A, remains to be investigated.

More recently, *DCX* has also been shown to be expressed during embryonal development in motor neurons and skeletal muscle at the neuromuscular junctions with loss of DCX resulting in disturbed neuromuscular junction formation [Bourgeois et al 2015].

Abnormal gene product. Abnormal DCX products may affect proper microtubule formation and perturb the mitotic machinery, although not all abnormal products appear to do so to the same extent [Sapir et al 2000, Couillard-Despres et al 2004]. The effect of *DCX* pathogenic variants on protein function is therefore not yet fully understood. Functional studies indicate loss of function for several abnormal DCX products, which may however be mediated by different cellular or off-pathway mechanisms [Yap et al 2016].

Chapter Notes

Author Notes

www.humangenetik-regensburg.de

Revision History

- 7 February 2019 (ha) Comprehensive update posted live
- 24 March 2011 (me) Comprehensive update posted live
- 19 October 2007 (me) Review posted live
- 31 March 2006 (jw) Original submission

References

Literature Cited

Aigner L, Uyanik G, Couillard-Despres S, Ploetz S, Wolff G, Morris-Rosendahl D, Martin P, Eckel U, Spranger S, Otte J, Woerle H, Holthausen H, Apheshiotis N, Fluegel D, Winkler J. Somatic mosaicism and variable penetrance in doublecortin-associated migration disorders. Neurology. 2003;60:329–32. PubMed PMID: 12552055.

Bahi-Buisson N, Poirier K, Fourniol F, Saillour Y, Valence S, Lebrun N, Hully M, Bianco CF, Boddaert N, Elie C, Lascelles K, Souville I, Beldjord C, Chelly J, et al. The wide spectrum of tubulinopathies: what are the key features for the diagnosis? Brain. 2014;137:1676–700. PubMed PMID: 24860126.

Bahi-Buisson N, Souville I, Fourniol FJ, Toussaint A, Moores CA, Houdusse A, Lemaitre JY, Poirier K, Khalaf-Nazzal R, Hully M, Leger PL, Elie C, Boddaert N, Beldjord C, Chelly J, Francis F, et al. New insights into genotype-phenotype correlations for the double cortin-related lissencephaly spectrum. Brain. 2013;136:223–44. PubMed PMID: 23365099.

Bernasconi A, Martinez V, Rosa-Neto P, D'Agostino D, Bernasconi N, Berkovic S, MacKay M, Harvey AS, Palmini A, da Costa JC, Paglioli E, Kim HI, Connolly M, Olivier A, Dubeau F, Andermann E, Guerrini R,

Whisler W, de Toledo-Morrell L, Morrell F, Andermann F. Surgical resection for intractable epilepsy in "double cortex" syndrome yields inadequate results. Epilepsia. 2001;42:1124–9. PubMed PMID: 11580758.

Bourgeois F, Messéant J, Kordeli E, Petit JM, Delers P, Bahi-Buisson N, Bernard V, Sigoillot SM, Gitiaux C, Stouffer M, Francis F, Legay C. A critical and previously unsuspected role for doublecortin at the neuromuscular junction in mouse and human. Neuromuscul Disord. 2015;25:461–73. PubMed PMID: 25817838.

Bruno DL, Anderlid BM, Lindstrand A, van Ravenswaaij-Arts C, Ganesamoorthy D, Lundin J, Martin CL, Douglas J, Nowak C, Adam MP, Kooy RF, Van der Aa N, Reyniers E, Vandeweyer G, Stolte-Dijkstra I, Dijkhuizen T, Yeung A, Delatycki M, Borgström B, Thelin L, Cardoso C, van Bon B, Pfundt R, de Vries BB, Wallin A, Amor DJ, James PA, Slater HR, Schoumans J. Further molecular and clinical delineation of co-locating 17p13.3 microdeletions and microduplications that show distinctive phenotypes. J Med Genet. 2010;47:299–311. PubMed PMID: 20452996.

Coman D, Fullston T, Shoubridge C, Leventer R, Wong F, Nazaretian S, Simpson I, Gecz J, McGillivray G. X-linked lissencephaly with absent corpus callosum and abnormal genitalia: an evolving multisystem syndrome with severe congenital intestinal diarrhea disease. Child Neurol Open. 2017;4:2329048X17738625.

Couillard-Despres S, Uyanik G, Ploetz S, Karl C, Koch H, Winkler J, Aigner L. Mitotic impairment by doublecortin is diminished by doublecortin mutations found in patients. Neurogenetics. 2004;5:83–93. PubMed PMID: 15045646.

D'Agostino MD, Bernasconi A, Das S, Bastos A, Valerio RM, Palmini A, Costa da Costa J, Scheffer IE, Berkovic S, Guerrini R, Dravet C, Ono J, Gigli G, Federico A, Booth F, Bernardi B, Volpi L, Tassinari CA, Guggenheim MA, Ledbetter DH, Gleeson JG, Lopes-Cendes I, Vossler DG, Malaspina E, Franzoni E, Sartori RJ, Mitchell MH, Mercho S, Dubeau F, Andermann F, Dobyns WB, Andermann E. Subcortical band heterotopia (SBH) in males: clinical, imaging and genetic findings in comparison with females. Brain. 2002;125:2507–22. PubMed PMID: 12390976.

Demelas L, Serra G, Conti M, Achene A, Mastropaolo C, Matsumoto N, Dudlicek LL, Mills PL, Dobyns WB, Ledbetter DH, Das S. Incomplete penetrance with normal MRI in a woman with germline mutation of the DCX gene. Neurology. 2001;57:327–30. PubMed PMID: 11468322.

des Portes V, Pinard JM, Billuart P, Vinet MC, Koulakoff A, Carrie A, Gelot A, Dupuis E, Motte J, Berwald-Netter Y, Catala M, Kahn A, Beldjord C, Chelly J. A novel CNS gene required for neuronal migration and involved in X-linked subcortical laminar heterotopia and lissencephaly syndrome. Cell. 1998;92:51–61. PubMed PMID: 9489699.

Di Donato N, Chiari S, Mirzaa GM, Aldinger K, Parrini E, Olds C, Barkovich AJ, Guerrini R, Dobyns WB. Lissencephaly: expanded imaging and clinical classification. Am J Med Genet A. 2017;173:1473–88. PubMed PMID: 28440899.

Di Donato N, Jean YY, Maga AM, Krewson BD, Shupp AB, Avrutsky MI, Roy A, Collins S, Olds C, Willert RA, Czaja AM, Johnson R, Stover JA, Gottlieb S, Bartholdi D, Rauch A, Goldstein A, Boyd-Kyle V, Aldinger KA, Mirzaa GM, Nissen A, Brigatti KW, Puffenberger EG, Millen KJ, Strauss KA, Dobyns WB, Troy CM, Jinks RN. Mutations in CRADD result in reduced caspase-2-mediated neuronal apoptosis and cause megalencephaly with a rare lissencephaly variant. Am J Hum Genet. 2016a;99:1117–29. PubMed PMID: 27773430.

Di Donato N, Kuechler A, Vergano S, Heinritz W, Bodurtha J, Merchant SR, Breningstall G, Ladda R, Sell S, Altmüller J, Bögershausen N, Timms AE, Hackmann K, Schrock E, Collins S, Olds C, Rump A, Dobyns WB. Update on the ACTG1-associated Baraitser-Winter cerebrofrontofacial syndrome. Am J Med Genet A. 2016b;170:2644–51. PubMed PMID: 27240540.

Dobyns WB. The clinical patterns and molecular genetics of lissencephaly and subcortical band heterotopia. Epilepsia. 2010;51 Suppl 1 :5–9. PubMed PMID: 20331703.

Forman MS, Squier W, Dobyns WB, Golden JA. Genotypically defined lissencephalies show distinct pathologies. J Neuropathol Exp Neurol. 2005;64:847–57. PubMed PMID: 16215456.

Fourniol FJ, Sindelar CV, Amigues B, Clare DK, Thomas G, Perderiset M, Francis F, Houdusse A, Moores CA. Template-free 13-protofilament microtubule-MAP assembly visualized at 8 A resolution. J Cell Biol. 2010;191:463–70. PubMed PMID: 20974813.

Franco A, Pimentel J, Campos AR, Morgado C, Pinelo S, Ferreira AG, Bentes C. Stimulation of the bilateral anterior nuclei of the thalamus in the treatment of refractory epilepsy: two cases of subcortical band heterotopia. Epileptic Disord. 2016;18:426–30. PubMed PMID: 27965181.

Friocourt G, Koulakoff A, Chafey P, Boucher D, Fauchereau F, Chelly J, Francis F. Doublecortin functions at the extremities of growing neuronal processes. Cereb Cortex. 2003;13:620–6. PubMed PMID: 12764037.

Ghai S, Fong KW, Toi A, Chitayat D, Pantazi S, Blaser S. Prenatal US and MR imaging findings of lissencephaly: review of fetal cerebral sulcal development. Radiographics. 2006;26:389–405. PubMed PMID: 16549605.

Gleeson JG, Allen KM, Fox JW, Lamperti ED, Berkovic S, Scheffer I, Cooper EC, Dobyns WB, Minnerath SR, Ross ME, Walsh CA. Doublecortin, a brain-specific gene mutated in human X-linked lissencephaly and double cortex syndrome, encodes a putative signaling protein. Cell. 1998;92:63–72. PubMed PMID: 9489700.

Gleeson JG, Minnerath S, Kuzniecky RI, Dobyns WB, Young ID, Ross ME, Walsh CA. Somatic and germline mosaic mutations in the doublecortin gene are associated with variable phenotypes. Am J Hum Genet. 2000;67:574–81. PubMed PMID: 10915612.

Gleeson JG, Minnerath SR, Fox JW, Allen KM, Luo RF, Hong SE, Berg MJ, Kuzniecky R, Reitnauer PJ, Borgatti R, Mira AP, Guerrini R, Holmes GL, Rooney CM, Berkovic S, Scheffer I, Cooper EC, Ricci S, Cusmai R, Crawford TO, Leroy R, Andermann E, Wheless JW, Dobyns WB, Ross ME, Walsh CA. Characterization of mutations in the gene doublecortin in patients with double cortex syndrome. Ann Neurol. 1999;45:146–53. PubMed PMID: 9989615.

González-Morón D, Vishnopolska S, Consalvo D, Medina N, Marti M, Córdoba M, Vazquez-Dusefante C, Claverie S, Rodríguez-Quiroga SA, Vega P, Silva W, Kochen S, Kauffman MA. Germline and somatic mutations in cortical malformations: molecular defects in Argentinean patients with neuronal migration disorders. PLoS One. 2017;12:e0185103. PubMed PMID: 28953922.

Guerrini R, Filippi T. Neuronal migration disorders, genetics, and epileptogenesis. J Child Neurol. 2005;20:287–99. PubMed PMID: 15921228.

Guerrini R, Moro F, Andermann E, Hughes E, D'Agostino D, Carrozzo R, Bernasconi A, Flinter F, Parmeggiani L, Volzone A, Parrini E, Mei D, Jarosz JM, Morris RG, Pratt P, Tortorella G, Dubeau F, Andermann F, Dobyns WB, Das S. Nonsyndromic mental retardation and cryptogenic epilepsy in women with doublecortin gene mutations. Ann Neurol. 2003;54:30–7. PubMed PMID: 12838518.

Haverfield EV, Whited AJ, Petras KS, Dobyns WB, Das S. Intragenic deletions and duplications of the LIS1 and DCX genes: a major disease-causing mechanism in lissencephaly and subcortical band heterotopia. Eur J Hum Genet. 2009;17:911–8. PubMed PMID: 19050731.

Hoischen A, Landwehr C, Kabisch S, Ding XQ, Trost D, Stropahl G, Wigger M, Radlwimmer B, Weber RG, Haffner D. Array-CGH in unclear syndromic nephropathies identifies a microdeletion in Xq22.3-q23. Pediatr Nephrol. 2009;24:1673–81. PubMed PMID: 19444485.

Huang SJ, Amendola LM, Sternen DL. Variation among DNA banking consent forms: points for clinicians to bank on. J Community Genet. 2022;13:389–97. PubMed PMID: 35834113.

Jamuar SS, Lam AT, Kircher M, D'Gama AM, Wang J, Barry BJ, Zhang X, Hill RS, Partlow JN, Rozzo A, Servattalab S, Mehta BK, Topcu M, Amrom D, Andermann E, Dan B, Parrini E, Guerrini R, Scheffer IE, Berkovic SF, Leventer RJ, Shen Y, Wu BL, Barkovich AJ, Sahin M, Chang BS, Bamshad M, Nickerson DA,

Shendure J, Poduri A, Yu TW, Walsh CA. Somatic mutations in cerebral cortical malformations. N Engl J Med. 2014;371:733–43. PubMed PMID: 25140959.

Leger PL, Souville I, Boddaert N, Elie C, Pinard JM, Plouin P, Moutard ML, des Portes V, Van Esch H, Joriot S, Renard JL, Chelly J, Francis F, Beldjord C, Bahi-Buisson N. The location of DCX mutations predicts malformation severity in X-linked lissencephaly. Neurogenetics. 2008;9:277–85. PubMed PMID: 18685874.

Leventer RJ. Genotype-phenotype correlation in lissencephaly and subcortical band heterotopia: the key questions answered. J Child Neurol. 2005;20:307–12. PubMed PMID: 15921231.

Magen D, Ofir A, Berger L, Goldsher D, Eran A, Katib N, Nijem Y, Vlodavsky E, Tzur S, Behar DM, Fellig Y, Mandel H. Autosomal recessive lissencephaly with cerebellar hypoplasia is associated with a loss-of-function mutation in CDK5. Hum Genet. 2015;134:305–14. PubMed PMID: 25560765.

Marcorelles P, Laquerrière A, Adde-Michel C, Marret S, Saugier-Veber P, Beldjord C, Friocourt G. Evidence for tangential migration disturbances in human lissencephaly resulting from a defect in LIS1, DCX and ARX genes. Acta Neuropathol. 2010;120:503–15. PubMed PMID: 20461390.

Martin P, Uyanik G, Wiemer-Kruel A, Schneider S, Gross C, Hehr U, Winkler J. Different clinical and morphological phenotypes in monozygotic twins with identical DCX mutation. J Neurol. 2004;251:108–10. PubMed PMID: 14999500.

Matsumoto N, Leventer RJ, Kuc JA, Mewborn SK, Dudlicek LL, Ramocki MB, Pilz DT, Mills PL, Das S, Ross ME, Ledbetter DH, Dobyns WB. Mutation analysis of the DCX gene and genotype/phenotype correlation in subcortical band heterotopia. Eur J Hum Genet. 2001;9:5–12. PubMed PMID: 11175293.

Moores CA, Perderiset M, Kappeler C, Kain S, Drummond D, Perkins SJ, Chelly J, Cross R, Houdusse A, Francis F. Distinct roles of doublecortin modulating the microtubule cytoskeleton. EMBO J. 2006;25:4448–57. PubMed PMID: 16957770.

Moreira I, Bastos-Ferreira R, Silva J, Ribeiro C, Alonso I, Chaves J. Paternal transmission of subcortical band heterotopia through DCX somatic mosaicism. Seizure. 2015;25:62–4. PubMed PMID: 25645638.

Mutch CA, Poduri A, Sahin M, Barry B, Walsh CA, Barkovich AJ. Disorders of microtubule function in neurons: imaging correlates. AJNR Am J Neuroradiol. 2016;37:528–35. PubMed PMID: 26564436.

Pilz DT, Matsumoto N, Minnerath S, Mills P, Gleeson JG, Allen KM, Walsh CA, Barkovich AJ, Dobyns WB, Ledbetter DH, Ross ME. LIS1 and XLIS (DCX) mutations cause most classical lissencephaly, but different patterns of malformation. Hum Mol Genet. 1998;7:2029–37. PubMed PMID: 9817918.

Poirier K, Lebrun N, Broix L, Tian G, Saillour Y, Boscheron C, Parrini E, Valence S, Pierre BS, Oger M, Lacombe D, Geneviève D, Fontana E, Darra F, Cances C, Barth M, Bonneau D, Bernadina BD, N'guyen S, Gitiaux C, Parent P, des Portes V, Pedespan JM, Legrez V, Castelnau-Ptakine L, Nitschke P, Hieu T, Masson C, Zelenika D, Andrieux A, Francis F, Guerrini R, Cowan NJ, Bahi-Buisson N, Chelly J. Mutations in TUBG1, DYNC1H1, KIF5C and KIF2A cause malformations of cortical development and microcephaly. Nature Genet. 2013;45:639–47. PubMed PMID: 23603762.

Quélin C, Saillour Y, Souville I, Poirier K, N'guyen-Morel MA, Vercueil L, Millisher-Bellaiche AE, Boddaert N, Dubois F, Chelly J, Beldjord C, Bahi-Buisson N. Mosaic DCX deletion causes subcortical band heterotopia in males. Neurogenetics. 2012;13:367–73. PubMed PMID: 22833188.

Reiner O, Coquelle FM, Peter B, Levy T, Kaplan A, Sapir T, Orr I, Barkai N, Eichele G, Bergmann S. The evolving doublecortin (DCX) superfamily. BMC Genomics. 2006;7:188. PubMed PMID: 16869982.

Richards S, Aziz N, Bale S, Bick D, Das S, Gastier-Foster J, Grody WW, Hegde M, Lyon E, Spector E, Voelkerding K, Rehm HL; ACMG Laboratory Quality Assurance Committee. Standards and guidelines for the interpretation of sequence variants: a joint consensus recommendation of the American College of Medical Genetics and Genomics and the Association for Molecular Pathology. Genet Med. 2015;17:405-24. PubMed PMID: 25741868.

Sapir T, Horesh D, Caspi M, Atlas R, Burgess HA, Wolf SG, Francis F, Chelly J, Elbaum M, Pietrokovski S, Reiner O. Doublecortin mutations cluster in evolutionarily conserved functional domains. Hum Mol Genet. 2000;9:703–12. PubMed PMID: 10749977.

Taylor KR, Holzer AK, Bazan JF, Walsh CA, Gleeson JG. Patient mutations in doublecortin define a repeated tubulin-binding domain. J Biol Chem. 2000;275:34442–50. PubMed PMID: 10946000.

Tint I, Jean D, Baas PW, Black MM. Doublecortin associates with microtubules preferentially in regions of the axon displaying actin-rich protrusive structures. J Neurosci. 2009;29:10995–1010. PubMed PMID: 19726658.

Tsai MH, Kuo PW, Myers CT, Li SW, Lin WC, Fu TY, Chang HY, Mefford HC, Chang YC, Tsai JW. A novel DCX missense mutation in a family with X-linked lissencephaly and subcortical band heterotopia syndrome inherited from alow-level somatic mosaic mother: genetic and functional studies. Eur J Paediatr Neurol. 2016;20:788–94. PubMed PMID: 27292316.

Uyanik G, Aigner L, Martin P, Gross C, Neumann D, Marschner-Schäfer H, Hehr U, Winkler J. ARX mutations in X-linked lissencephaly with abnormal genitalia. Neurology. 2003;61:232–5. PubMed PMID: 12874405.

Uyanik G, Morris-Rosendahl DJ, Stiegler J, Klapecki J, Gross C, Berman Y, Martin P, Dey L, Spranger S, Korenke GC, Schreyer I, Hertzberg C, Neumann TE, Burkart P, Spaich C, Meng M, Holthausen H, Ades L, Seidel J, Mangold E, Buyse G, Meinecke P, Schara U, Zeschnigk C, Muller D, Helland G, Schulze B, Wright ML, Kortge-Jung S, Hehr A, Bogdahn U, Schuierer G, Kohlhase J, Aigner L, Wolff G, Hehr U, Winkler J. Location and type of mutation in the LIS1 gene do not predict phenotypic severity. Neurology. 2007;69:442–7. PubMed PMID: 17664403.

Valence S, Garel C, Barth M, Toutain A, Paris C, Amsallem D, Barthez MA, Mayer M, Rodriguez D, Burglen L. RELN and VLDLR mutations underlie two distinguishable clinico-radiological phenotypes. Clin Genet. 2016;90:545–9. PubMed PMID: 27000652.

Wynshaw-Boris A, Pramparo T, Youn YH, Hirotsune S. Lissencephaly: mechanistic insights from animal models and potential therapeutic strategies. Semin Cell Dev Biol. 2010;21:823–30. PubMed PMID: 20688183.

Yap CC, Digilio L, McMahon L, Roszkowska M, Bott CJ, Kruczek K, Winckler B. Different doublecortin (DCX) patient alleles show distinct phenotypes in cultured neurons: evidence for divergent loss-of-function and "off-pathway" cellular mechanisms. J Biol Chem. 2016;291:26613–26. PubMed PMID: 27799303.

License

GeneReviews® chapters are owned by the University of Washington. Permission is hereby granted to reproduce, distribute, and translate copies of content materials for noncommercial research purposes only, provided that (i) credit for source (http://www.genereviews.org/) and copyright (© 1993-2024 University of Washington) are included with each copy; (ii) a link to the original material is provided whenever the material is published elsewhere on the Web; and (iii) reproducers, distributors, and/or translators comply with the GeneReviews® Copyright Notice and Usage Disclaimer. No further modifications are allowed. For clarity, excerpts of GeneReviews chapters for use in lab reports and clinic notes are a permitted use.

For more information, see the GeneReviews® Copyright Notice and Usage Disclaimer.

For questions regarding permissions or whether a specified use is allowed, contact: admasst@uw.edu.