



Cranioectodermal Dysplasia

Synonym: Sensenbrenner Syndrome

Weizhen Tan, MD,¹ Angela Lin, MD,² and Kim Keppler-Noreuil, MD³

Created: September 12, 2013; Revised: December 15, 2022.

Summary

Clinical characteristics

Cranioectodermal dysplasia (CED) is a ciliopathy with skeletal involvement (narrow thorax, shortened proximal limbs, syndactyly, polydactyly, brachydactyly), ectodermal features (widely spaced hypoplastic teeth, hypodontia, sparse hair, skin laxity, abnormal nails), joint laxity, growth deficiency, and characteristic facial features (frontal bossing, low-set simple ears, high forehead, telecanthus, epicanthal folds, full cheeks, everted lower lip). Most affected children develop nephronophthisis that often leads to end-stage kidney disease in infancy or childhood, a major cause of morbidity and mortality. Hepatic fibrosis and retinal dystrophy are also observed.

Dolichocephaly, often secondary to sagittal craniosynostosis, is a primary manifestation that distinguishes CED from most other ciliopathies. Brain malformations and developmental delay may also occur.

Diagnosis/testing

The diagnosis of CED is established in a proband with characteristic clinical and radiographic features (including two frequent features and two other abnormalities, with at least one ectodermal defect – i.e., involvement of the teeth, hair, or nails) and/or by identification of biallelic pathogenic variants in one of the six genes currently known to be associated with CED: *IFT43*, *IFT52*, *IFT122*, *IFT140*, *WDR19*, or *WDR35*.

Management

Treatment of manifestations: As needed, surgery to correct sagittal craniosynostosis usually before age one year. Surgical correction may be needed for polydactyly of the hands and feet. Orthopedic care for hip dysplasia. Human growth hormone therapy could be considered in those who meet standard treatment criteria. Standard treatment for dental anomalies, nephronophthisis, liver disease, cardiac anomalies, and/or inguinal and umbilical hernias. For those with progressive visual impairment: low-vision aids and appropriate educational

Author Affiliations: 1 Clinical Instructor, Harvard Medical School, Division of Pediatric Nephrology, MassGeneral Hospital for Children, Boston, Massachusetts; Email: wtan2@partners.org. 2 Professor of Pediatrics, Harvard Medical School, Medical Genetics, MassGeneral Hospital for Children, Boston, Massachusetts; Email: lin.angela@mgh.harvard.edu. 3 Professor of Pediatrics, Division Chief of Genetics & Metabolism University of Wisconsin School of Medicine and Public Health, Madison, Wisconsin; Email: keppelnoreu@wisc.edu.

programs. Mechanical ventilation may be required in newborns with pulmonary hypoplasia. For those with developmental delay, speech and physical therapy and appropriate educational programs.

Surveillance: In infancy and childhood: monitor tooth development; morning urine osmolarity testing, urine collection assay for polyuria, blood pressure, serum creatinine and blood urea assessment, and renal ultrasound as recommended by nephrologist; hepatic transaminases and measurement of synthetic liver function as recommended by hepatologist. Annual ophthalmologic examinations starting at age four years to detect early signs of retinal degeneration. Cardiac examinations, EKG, and echocardiography per cardiologist. Review of developmental progress at each primary care visit, and formal evaluation with neuropsychological testing if delays noted.

Genetic counseling

CED is inherited in an autosomal recessive manner. If both parents are known to be heterozygous for a CED-causing pathogenic variant, each sib of an affected individual has at conception a 25% chance of being affected, a 50% chance of being an asymptomatic carrier, and a 25% chance of being unaffected and not a carrier. Carrier testing for at-risk relatives, prenatal testing for a pregnancy at increased risk, and preimplantation genetic testing are possible once the CED-causing pathogenic variants have been identified in an affected family member. Second-trimester ultrasound examination may detect renal cysts, shortening of the limbs, and/or polydactyly.

Diagnosis

Suggestive Findings

Cranioectodermal dysplasia (CED) **should be suspected** in individuals with the following clinical and radiographic findings.

Frequent features (in >75%)

- Characteristic facial features (e.g., frontal bossing, low-set/simple ears, high forehead, telecanthus, epicanthal folds, full cheeks, everted lower lip)
- Brachydactyly
- Dolichocephaly and sagittal craniosynostosis
- Shortening (and bowing) of proximal bones (mostly humeri)
- Short stature

Common features (50%-75%)

- Narrow thorax (with dysplastic ribs and pectus excavatum)
- Dental abnormalities (malformed, widely spaced teeth, and/or hypodontia)
- Sparse and/or thin hair
- Nephronophthisis (a phenotype of progressive kidney disease that may include features such as renal cysts, scarring, echogenic kidneys on ultrasound, chronic tubulointerstitial nephritis, and reduced renal function / renal concentrating ability)
- Developmental delay (most often affecting motor development)

Less common features (25%-50%)

- Joint laxity
- Liver disease (hepatic fibrosis, cirrhosis, and/or hepatomegaly)
- Syndactyly
- Polydactyly
- Abnormal nails

- Skin laxity
- Recurrent lung infections
- Bilateral inguinal hernias

Occasional to infrequent features (<25%)

- Retinal dystrophy
- Hip dysplasia
- Cystic hygroma
- Congenital heart defect
- Intellectual disability

Note: Some suggestive findings (e.g., developmental delay, dental abnormalities, abnormalities of the retina, kidney, and liver) may not be present in a neonate at the time of evaluation.

Establishing the Diagnosis

Although formal evidence-based diagnostic criteria have not been delineated, the clinical diagnosis of CED can be **established** in a proband based on clinical diagnostic criteria [Lin et al 2013], or the molecular diagnosis can be established in a proband with suggestive findings and biallelic pathogenic (or likely pathogenic) variants in one of the genes listed in Table 1.

Note: (1) Per ACMG/AMP variant interpretation guidelines, the terms "pathogenic variant" and "likely pathogenic variant" are synonymous in a clinical setting, meaning that both are considered diagnostic and can be used for clinical decision making [Richards et al 2015]. Reference to "pathogenic variants" in this *GeneReview* is understood to include any likely pathogenic variants. (2) Identification of biallelic variants of uncertain significance (or of one known pathogenic variant and one variant of uncertain significance) in one of the genes listed in Table 1 does not establish or rule out the diagnosis.

Clinical diagnosis. The clinical diagnosis of CED can be **established** in a proband with characteristic clinical and radiographic features described in Suggestive Findings including two frequent features and two other abnormalities, at least one of which is an ectodermal defect (i.e., involvement of the teeth, hair, or nails). Sagittal craniosynostosis distinguishes CED from most other ciliopathies [Lin et al 2013].

Molecular diagnosis. The molecular diagnosis of CED is **established** in a proband with Suggestive Findings and biallelic pathogenic variants in one of the genes listed in Table 1 identified on molecular genetic testing.

Molecular genetic testing approaches can include a combination of **gene-targeted testing** (multigene panel) and **comprehensive genomic testing** (exome sequencing, genome sequencing) depending on the phenotype.

Gene-targeted testing requires that the clinician determine which gene(s) are likely involved, whereas genomic testing does not. Individuals with the distinctive findings described in Suggestive Findings are likely to be diagnosed using gene-targeted testing (see Option 1), whereas those with a phenotype indistinguishable from many other inherited disorders with ectodermal dysplasia and/or skeletal anomalies are more likely to be diagnosed using genomic testing (see Option 2).

Option 1

A **multigene panel** that includes the genes listed in Table 1 and other genes of interest (see Differential Diagnosis) is most likely to identify the genetic cause of the condition while limiting identification of variants of uncertain significance and pathogenic variants in genes that do not explain the underlying phenotype. Note: (1) The genes included in the panel and the diagnostic sensitivity of the testing used for each gene vary by laboratory and are likely to change over time. (2) Some multigene panels may include genes not associated with the condition discussed in this *GeneReview*. (3) In some laboratories, panel options may include a custom

laboratory-designed panel and/or custom phenotype-focused exome analysis that includes genes specified by the clinician. (4) Methods used in a panel may include sequence analysis, deletion/duplication analysis, and/or other non-sequencing-based tests.

For an introduction to multigene panels click [here](#). More detailed information for clinicians ordering genetic tests can be found [here](#).

Option 2

When the phenotype is indistinguishable from many other inherited disorders characterized by ectodermal dysplasia and/or skeletal anomalies, **comprehensive genomic testing**, which does not require the clinician to determine which gene(s) are likely involved, is the best option. **Exome sequencing** is most commonly used; **genome sequencing** is also possible.

For an introduction to comprehensive genomic testing click [here](#). More detailed information for clinicians ordering genomic testing can be found [here](#).

Table 1. Molecular Genetic Testing Used in Cranioectodermal Dysplasia

Gene ^{1, 2}	Proportion of CED Attributed to Pathogenic Variants in Gene	Proportion of Pathogenic Variants ³ Detectable by Method	
		Sequence analysis ⁴	Gene-targeted deletion/duplication analysis ⁵
<i>IFT43</i>	2/71 (3%)	100% ⁶	None reported ⁷
<i>IFT52</i>	1/71 (1%)	100% ⁶	None reported ⁷
<i>IFT122</i>	13/71 (18%)	100% ⁶	None reported ⁷
<i>IFT140</i>	3/71 (4%)	60% ^{8, 9}	40% ⁸
<i>WDR19</i>	5/71 (7%)	100% ⁶	None reported ⁷
<i>WDR35</i>	23/71 (32%)	100% ⁶	None reported ¹⁰
Unknown	24/71 (34%)	NA	

CED = cranioectodermal dysplasia; NA = not applicable

1. Genes are listed in alphabetic order.

2. See Table A. Genes and Databases for chromosome locus and protein.

3. See Molecular Genetics for information on variants detected in these genes.

4. Sequence analysis detects variants that are benign, likely benign, of uncertain significance, likely pathogenic, or pathogenic. Variants may include missense, nonsense, and splice site variants and small intragenic deletions/insertions; typically, exon or whole-gene deletions/duplications are not detected. For issues to consider in interpretation of sequence analysis results, click [here](#).

5. Gene-targeted deletion/duplication analysis detects intragenic deletions or duplications. Methods used may include a range of techniques such as quantitative PCR, long-range PCR, multiplex ligation-dependent probe amplification (MLPA), and a gene-targeted microarray designed to detect single-exon deletions or duplications.

6. Data derived from subscription-based professional view of Human Gene Mutation Database [Stenson et al 2020]

7. Gene-targeted deletion/duplication analysis has not identified any deletions/duplications.

8. Walczak-Sztulpa et al [2020]

9. Bayat et al [2017]

10. No deletions or duplications involving *WDR35* have been reported to cause cranioectodermal dysplasia. See also Genetically Related Disorders for a phenotype resulting from *WDR35* exon deletion.

Clinical Characteristics

Clinical Description

Cranioectodermal dysplasia (CED) is a ciliopathy with significant involvement of the skeleton, ectoderm (teeth, hair, and nails), retina, kidneys, liver, lungs, and occasionally the brain. The current understanding of the CED phenotype is limited by the small number of well-described affected individuals reported and the even smaller number with a molecularly confirmed diagnosis.

To date, 44 individuals with biallelic pathogenic variants in one of the genes listed in Table 1 have been described clinically [Zaffanello et al 2006; Fry et al 2009; Gilissen et al 2010; Walczak-Sztulpa et al 2010; Arts et al 2011; Bredrup et al 2011; Bacino et al 2012; Hoffer et al 2013; Lin et al 2013; Alazami et al 2014; Tsurusaki et al 2014; Li et al 2015; Daoud et al 2016; Girisha et al 2016; Moosa et al 2016; Smith et al 2016; Antony et al 2017; Bayat et al 2017; Silveira et al 2017; Walczak-Sztulpa et al 2017; Xu et al 2017; Yoshikawa et al 2017; Ackah et al 2018; Córdova-Fletes et al 2018; Walczak-Sztulpa et al 2018; Walczak-Sztulpa et al 2020; Author, personal communication]. The following description of the phenotypic features associated with this condition is based on these reports.

Table 2. Select Features of Cranioectodermal Dysplasia

Frequency	Features
Frequent (>75%)	Characteristic facial features (frontal bossing, low-set/simple ears, high forehead, telecanthus, epicanthal folds, full cheeks, everted lower lip)
	Brachydactyly
	Dolichocephaly & sagittal craniosynostosis
	Shortening/bowing of proximal bones (most often humeri)
	Short stature
Common (50%-75%)	Narrow thorax w/dysplastic ribs & pectus excavatum
	Dental abnormalities (malformed, widely spaced, &/or hypodontia)
	Sparse &/or thin hair
	Nephronophthisis
	Developmental delay (most often motor development)
Less common (25%-50%)	Joint laxity
	Liver disease (hepatic fibrosis, cirrhosis, &/or hepatomegaly)
	Syndactyly
	Polydactyly
	Abnormal nails
	Skin laxity
	Recurrent lung infections
Bilateral inguinal hernias	

Table 2. continued from previous page.

Frequency	Features
Occasional to infrequent (<25%)	Retinal dystrophy
	Hip dysplasia
	Cystic hygroma
	Congenital heart defect
	Intellectual disability

Characteristic facial features can be observed from birth and are evident in nearly all individuals with CED (see Figure 1), including frontal bossing, bitemporal narrowing, and a tall forehead; low-set, simple, and/or posteriorly rotated ears; telecanthus, epicanthal folds, and/or down-/upslanting palpebral fissures; full cheeks; micrognathia; everted lower lip; and anteverted nares.

Dolichocephaly (apparently increased anteroposterior length of the head compared to width) and frontal bossing are usually secondary to sagittal craniosynostosis, which is usually present at birth. Sib pairs may show discordance for sagittal craniosynostosis [Arts et al 2011, Bredrup et al 2011].

Skeletal findings

- **Hands and feet.** Prenatal ultrasound may detect polydactyly during mid-gestation [Konstantinidou et al 2009]. Neonates often have brachydactyly (with short middle and distal phalanges that may be abnormally shaped), postaxial polydactyly, and cutaneous syndactyly of fingers and toes (most frequently mild cutaneous syndactyly of second and third toes). Epiphyses of phalanges can have a normal appearance on radiograph or can be flattened or cone shaped [Fry et al 2009]. Other findings of the hands and feet variably seen include fifth-finger clinodactyly, abnormal palmar creases, restricted finger flexion, osteoporosis, sandal gap, and/or triphalangeal hallux [Gilissen et al 2010, Bacino et al 2012, Hoffer et al 2013, Lin et al 2013].
- **Thorax.** A narrow thorax with short dysplastic ribs is common, though not ubiquitous, and may be noted as early as mid-gestation; however, this finding was most commonly first noted at birth [Lin et al 2013]. Pectus excavatum is often observed [Hoffer et al 2013]. Rib deformities (e.g., short ribs, coat-hanger-shaped ribs) may normalize during childhood [Bacino et al 2012].
- **Shortening (and bowing) of proximal long bones** has been noted as early as 23 weeks' gestation. Upper limbs are often shorter compared to lower limbs; humeri are particularly affected. Long bones may display bowing, and epiphyses may be flattened and/or display metaphyseal flaring [Bacino et al 2012, Hoffer et al 2013, Lin et al 2013].
- **Growth deficiency.** At birth the length as related to gestational age may be within the normal range but can also be below the third centile. Infants may have growth deficiency with length below the third centile, but length may also be between the fifth and tenth centile [Bacino et al 2012].

Ectodermal defects

- **Teeth.** Tooth eruption is often delayed. Deciduous teeth are generally small and widely spaced. Hypodontia, enamel defects, taurodontia, and fused and cone-shaped teeth have also been reported. Similar characteristics are seen in permanent teeth. Hypo- or oligodontia may affect upper as well as lower permanent teeth [Fry et al 2009, Gilissen et al 2010, Walczak-Sztulpa et al 2010, Arts et al 2011, Bredrup et al 2011].
- **Skin.** Prenatal ultrasound may reveal mid-gestational nuchal webbing and skin thickening. Generalized skin laxity and redundant skin folds have been reported in infancy and thereafter. Skin folds have been

found particularly at the neck, ankles, and wrists. Skin may be dry; hyperkeratosis has been reported [Arts et al 2011, Bredrup et al 2011, Bacino et al 2012].

- **Hair.** Most infants and young children with CED have sparse, fine hair. Hair may be hypopigmented with reduced diameter. Hair growth may also be affected [Arts et al 2011, Lin et al 2013]. In some instances, hair growth may normalize during childhood [Konstantinidou et al 2009].
- **Nails** are short, broad, and slow growing from infancy [Hoffer et al 2013].

Kidney disease is due to nephronophthisis (tubulointerstitial nephritis). At least 60%-70% of persons with CED were reported to have renal insufficiency. Although end-stage kidney disease (ESKD) can be evident prenatally as poly/oligohydramnios and small cystic kidneys in the second trimester of pregnancy, the first signs of kidney disease are often evident in early childhood (age ~2 years) [Bacino et al 2012]. Initially reduced urinary concentrating ability leads to polyuria and polydipsia. Nocturnal enuresis may be evident. Hypertension, proteinuria, hematuria, and electrolyte imbalances usually develop later in the disease course as a result of renal insufficiency and filtration defects. In ten of 21 children kidney disease progressed to ESKD. Of note, this number may have increased over time as follow-up studies are limited. Most children developed ESKD between ages two and six years [Hoffer et al 2013, Lin et al 2013].

Renal ultrasound examination in infancy and early childhood usually shows normal-sized or small kidneys with increased echogenicity and poor corticomedullary differentiation [Lin et al 2013]. Renal biopsy shows interstitial fibrosis with focal inflammatory cell infiltrates, tubular atrophy, glomerulosclerosis, and occasional cysts [Obikane et al 2006, Konstantinidou et al 2009, Bredrup et al 2011, Lin et al 2013]. The latter features occur in advanced disease.

Liver findings range from hepatosplenomegaly without signs of progressive liver disease to extensive liver abnormalities including (recurrent) hyperbilirubinemia and cholestatic disease requiring hospitalization in the newborn period [Walczak-Sztulpa et al 2010, Bacino et al 2012]. Liver cirrhosis, severe cholestasis with bile duct proliferation, and acute cholangitis have been described in infants [Zaffanello et al 2006, Arts et al 2011, Bacino et al 2012, Lin et al 2013]. Liver cysts have been detected in children age three and four years [Hoffer et al 2013], but also as early as age ten months [Lin et al 2013]. Longitudinal data on liver disease are not available; however, the long-term prognosis with respect to liver fibrosis and cirrhosis is probably poor.

Eye findings include retinal dystrophy and nystagmus [Bredrup et al 2011, Lin et al 2013]. Nyctalopia (night blindness) is often evident in the first years of life [Bredrup et al 2011]. Abnormal scotopic and photopic electroretinograms have been reported as early as ages four to 11 years, while fundoscopy has revealed attenuated arteries and bone-spicule-shaped deposits as early as ages five to 11 years in some [Bredrup et al 2011]. The natural history of the retinal dystrophy remains to be reported; however, in overlapping ciliopathies such as Bardet-Biedl syndrome, night blindness usually progresses to legal blindness in young adults (see [Bardet-Biedl Syndrome](#)). A similar prognosis is to be expected in CED.

Other ophthalmologic findings include hyperopia, myopia, esotropia, myopic/hypermetropic astigmatism, and euryblepharon (excess horizontal eyelid length) [Konstantinidou et al 2009, Bredrup et al 2011, Hoffer et al 2013, Lin et al 2013].

Pulmonary. In infancy or early childhood, children with CED may experience life-threatening respiratory distress due to pulmonary hypoplasia and recurrent respiratory infections. Asthma and pneumothorax have also been reported [Bredrup et al 2011, Bacino et al 2012, Hoffer et al 2013]. Many children die of respiratory distress after birth or of pneumonia during early childhood [Tamai et al 2002]. Recurrent respiratory infections have been reported to diminish in frequency over time [Konstantinidou et al 2009].

Cardiac malformations have included patent ductus arteriosus and atrial and ventricular septal defects. Thickening of the mitral and tricuspid valves, ventricular hypertrophy/dilatation, and peripheral pulmonary

stenosis have also been reported [Arts et al 2011, Bacino et al 2012]. Bacino et al [2012] reported one affected child in whom cardiac arrhythmia and atrial septal defect resolved at age three years.

Central nervous system. Although the majority of children develop normally, mild developmental delay is reported in some individuals [Hoffer et al 2013, Lin et al 2013]. Sitting unsupported may be delayed to nine to 15 months and walking to three years [Fry et al 2009, Bacino et al 2012, Hoffer et al 2013]. Delays in speech may vary from a few words at age 19 months to no words at age five years [Hoffer et al 2013]. No information is available on how affected individuals respond to speech and physical therapy. Cognitive and social abilities are usually normal but intellectual disability is diagnosed in some individuals [Fry et al 2009, Alazami et al 2014, Li et al 2015].

Brain imaging has revealed cortical atrophy, ventriculomegaly, large cisterna magna, hypoplasia of the corpus callosum, focal microdysgenesis, enlarged extracerebral fluid spaces, large posterior fossa cyst, and Dandy-Walker malformation [Zannolli et al 2001, Fry et al 2009, Konstantinidou et al 2009, Bacino et al 2012, Hoffer et al 2013, Lin et al 2013, Girisha et al 2016, Walczak-Sztulpa et al 2020].

Other

- **Joint laxity** can be observed from the neonatal period [Fry et al 2009].
- **Hernia.** (Bilateral) inguinal hernias and/or umbilical hernia can be present in neonates or during the first year of life [Fry et al 2009, Walczak-Sztulpa et al 2010].

Life expectancy. Morbidity is high in individuals with CED and hospitalization may be frequent and/or extended [Bacino et al 2012]. Mortality rates are unclear, although 10/65 children with CED died before age seven years of respiratory failure [Levin et al 1977, Savill et al 1997, Tamai et al 2002], heart failure [Eke et al 1996, Savill et al 1997, Bacino et al 2012, Silveira et al 2017, Walczak-Sztulpa et al 2017], hypovolemic shock (as a result of coagulopathy) [Bacino et al 2012], or unknown causes [Lin et al 2013, Antony et al 2017]. This number could be higher as longitudinal data on the majority of individuals with CED are unavailable. At least three persons with CED survived into young adulthood (see Bredrup et al [2011] and Figure 1).

Phenotype Correlations by Gene

Phenotypes resulting from biallelic pathogenic variants in any one of the six known genes (i.e., *IFT43*, *IFT52*, *IFT122*, *IFT140*, *WDR19*, *WDR35*) are not distinguishable [Walczak-Sztulpa et al 2010, Arts et al 2011, Bredrup et al 2011, Bacino et al 2012, Hoffer et al 2013, Girisha et al 2016, Bayat et al 2017].

Genotype-Phenotype Correlations

No genotype-phenotype correlations have been confirmed.

Nomenclature

CED was first described as Sensenbrenner syndrome in a sib pair with dolichocephaly, rhizomelic shortening of the bones, brachydactyly, and ectodermal defects [Sensenbrenner et al 1975]. Subsequently Levin et al [1977] described affected individuals from two additional families and renamed the disorder cranioectodermal dysplasia.

Prevalence

CED is rare; its exact frequency is unknown. Fewer than 100 affected individuals have been reported.

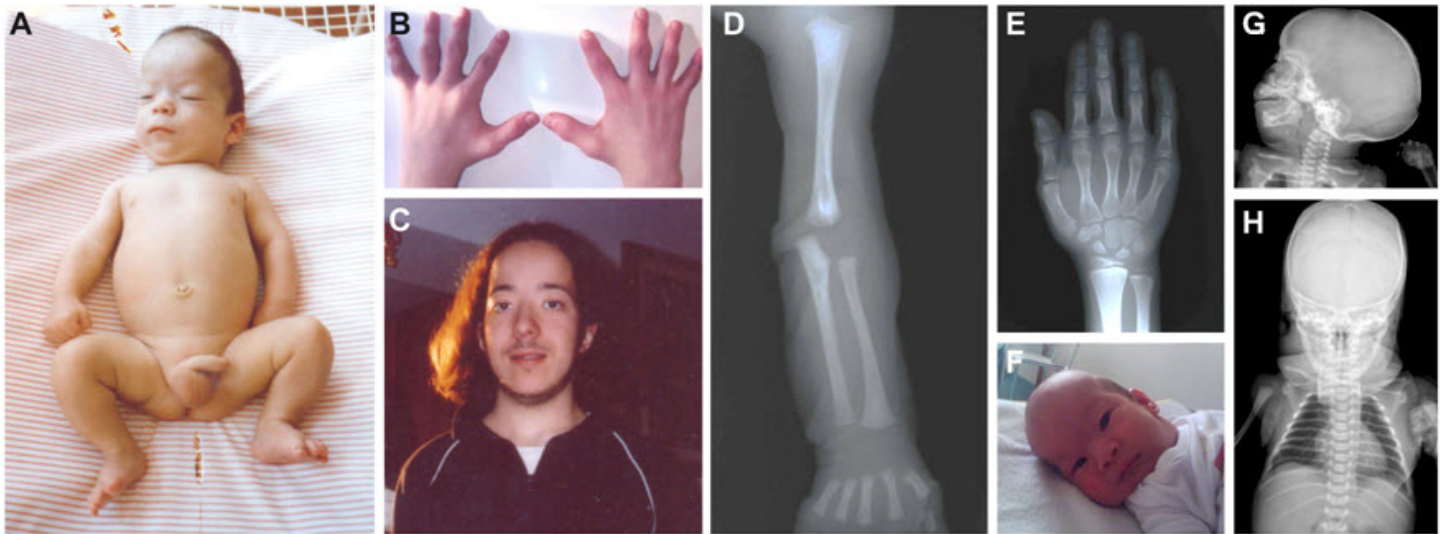


Figure 1. Clinical and radiographic features of cranioectodermal dysplasia (CED)

Patient 1 (A-E):

A. Newborn with cranioectodermal dysplasia (CED) with rhizomelic shortening of the arms, narrow thorax, and characteristic facies with prominent forehead, ocular hypertelorism, and low-set ears

B. Short, broad hands with interphalangeal swelling at age 16 years

C. CED facial features in a young adult

D. Radiograph showing rhizomelia in the newborn period

E. Radiograph showing short phalanges at age nine years

Patient 2 (F-H):

F. Female with typical facial characteristics, including a prominent forehead, and bilateral epicanthal folds

G. Radiograph showing dolichocephaly in the newborn period

H. Radiograph showing narrow thorax

Images are shown with informed consent of the families/affected individuals.

Genetically Related (Allelic) Disorders

No phenotypes other than those discussed in this *GeneReview* are known to be associated with pathogenic variants in *IFT122*. Note: An individual with biallelic *IFT122* pathogenic variants was diagnosed with Beemer-Langer syndrome (short-rib polydactyly syndrome, type IV); on further review, however, the phenotype in this individual is more consistent with cranioectodermal dysplasia (CED) [Silveira et al 2017].

Heterozygous pathogenic variants in *IFT140* have been identified in individuals with a mild polycystic kidney disease phenotype (see [Polycystic Kidney Disease, Autosomal Dominant](#)).

Biallelic pathogenic variants in *IFT43* and *IFT140* have been associated with isolated retinitis pigmentosa 81 (OMIM 617871) and isolated retinitis pigmentosa 80 (OMIM 617781), respectively. Other autosomal recessive phenotypes associated with germline pathogenic variants in *IFT43*, *IFT52*, *IFT140*, *WDR19*, and *WDR35* are summarized in Table 3. These disorders have phenotypic features that overlap with CED and should be considered in the Differential Diagnosis.

Table 3. Allelic Disorders to Consider in the Differential Diagnosis of Cranioectodermal Dysplasia

Gene	Disorder
<i>IFT43</i>	SRPS unclassified ¹
<i>IFT52</i>	Jeune asphyxiating thoracic dystrophy ¹
	Jeune asphyxiating thoracic dystrophy ¹
<i>IFT140</i>	Mainzer-Saldino syndrome ¹
	Opitz trigonocephaly C syndrome ²
<i>WDR19</i>	Jeune asphyxiating thoracic dystrophy ¹
	Nephronophthisis
	Senior-Løken syndrome (OMIM 616307)
<i>WDR35</i>	Chondroectodermal dysplasia (Ellis-van Creveld syndrome) ¹
	SRPS type 5 ¹
	SRPS unclassified ¹

SRPS = short-rib polydactyly syndrome

1. Mortier et al [2019]

2. Peña-Padilla et al [2017]

Differential Diagnosis

Cranioectodermal dysplasia (CED) is part of a spectrum of disorders caused by disruption of the cilium, an organelle of the cell that appears and functions as an antenna (see Figure 2) [Huber & Cormier-Daire 2012]. These disorders, collectively referred to as ciliopathies, display marked phenotypic overlap. Typical clinical features of ciliopathies are: renal cystic disease; retinal dystrophy; shortening of ribs, phalanges, and long bones; polydactyly; hepatic fibrosis; and developmental delay.

Within the ciliopathies, Jeune asphyxiating thoracic dystrophy, Mainzer-Saldino syndrome, [Ellis-van Creveld syndrome](#), and the short-rib polydactyly syndromes resemble CED the most (see Table 4). These autosomal recessive skeletal ciliopathies are referred to as short-rib thoracic dysplasia in OMIM (OMIM [PS208500](#)).

Table 4. Skeletal Ciliopathies of Interest in the Differential Diagnosis of Cranioectodermal Dysplasia

Genes	Disorder	Overlapping Features		Distinguishing Features
		Skeletal abnormalities	Extraskeletal features	
<i>CEP120</i> <i>DYNC2H1</i> <i>DYNC2I1</i> (<i>WDR60</i>) <i>DYNC2I2</i> (<i>WDR34</i>) <i>DYNC2LI1</i> <i>IFT52</i> <i>IFT80</i> <i>IFT81</i> <i>IFT140</i> <i>IFT172</i> <i>INTU</i> <i>KIAA0586</i> <i>NEK1</i> <i>TCTEX1D2</i> <i>TTC21B</i> <i>WDR19</i> (OMIM PS208500)	Jeune asphyxiating thoracic dystrophy (JATD)	Polydactyly, brachydactyly, rhizomelic limb shortening	Renal cystic disease, liver anomalies, retinal dystrophy	JATD has a strong phenotypic overlap w/CED: narrow rib cage is seen in both disorders; but the phenotype is usually mild in CED & more pronounced in JATD, often leading to severe respiratory distress. In a review of 10 newborns or infants w/JATD, 6 died of respiratory insufficiency. ¹
	Mainzer-Saldino syndrome (MZSDS)	Phalangeal cone-shaped epiphyses; narrow thorax & scaphocephaly variably seen ²	Retinal dystrophy; nephronophthisis; cerebellar ataxia & hepatic fibrosis variably seen ²	MZSDS usually lacks typical ectodermal features of CED.
	Short-rib polydactyly syndromes (SRPS) ^{1,3}	Extremely short limbs & ribs (severe narrow rib cage), polydactyly	Malformations in variety of organs ⁴	SRPS is lethal in perinatal period due to severe narrow rib cage.
<i>EVC</i> <i>EVC2</i> <i>WDR35</i>	Ellis-van Creveld syndrome (EVC) ³	Postaxial polydactyly; shortening of limbs & ribs	Ectodermal dysplasia affecting hair, nails, & teeth; ⁵ congenital heart disease (major finding in EVC syndrome: septal defects, mainly atrial)	Frequency of heart defects in EVC syndrome (occurring in 60% of affected persons ⁶) is greater than in CED.

CED = cranioectodermal dysplasia

1. Oberklaid et al [1977]

2. Perrault et al [2012]

3. In addition to the genes listed, SRPS and EVC can be caused by pathogenic variants in *WDR35* (see Genetically Related Disorders).

4. Elçioğlu & Hall [2002], Huber & Cormier-Daire [2012]

5. Huber & Cormier-Daire [2012]

6. Ruiz-Perez et al [2000], Baujat & Le Merrer [2007]

Other ciliopathies that clinically overlap with CED include isolated **nephronophthisis**, isolated retinal dystrophy, Caroli disease, Senior-Løken syndrome, **Joubert syndrome**, Meckel-Gruber syndrome (OMIM PS249000), and **Bardet-Biedl syndrome** [Huber & Cormier-Daire 2012].

- **Senior-Løken syndrome** (OMIM 266900) is a heterogeneous autosomal recessive disorder that is characterized by nephronophthisis and retinal dystrophy. Pathogenic variants in *CEP290*, *IQCB1*, *NPHP1*, *NPHP4*, *SDCCAG8*, *TRAF3IP1*, and *WDR19* have been detected in persons with Senior-Løken syndrome. (Note: Pathogenic variants in *WDR19* are also associated with CED.)
- **Caroli disease** (OMIM 600643) is characterized by polycystic liver disease and cholangitis. It is part of the **autosomal recessive polycystic kidney disease** spectrum of disorders and can occur as an isolated finding as well as in combination with other features including renal cystic disease.
- **Autosomal recessive retinal dystrophy** (also known as **retinitis pigmentosa**) can be an isolated finding or occur in syndromic disorders such as CED. Retinitis pigmentosa usually starts with night blindness and can progress to complete blindness later in life due to loss of the photoreceptors (rods and cones). The fundus often displays attenuation of retinal vessels and may reveal abnormal peripheral pigmentation (referred to as bone-spicule deposits). More than 50% of families with isolated retinitis pigmentosa have

an autosomal recessive form. Pathogenic variants in more than 50 genes can cause RP, and almost two thirds of these genes encode ciliary proteins.

Management

Evaluations Following Initial Diagnosis

To establish the extent of disease and needs of a newborn or infant diagnosed with cranioectodermal dysplasia (CED), the evaluations summarized in Table 5 (if not performed as part of the evaluation that led to the diagnosis) are recommended.

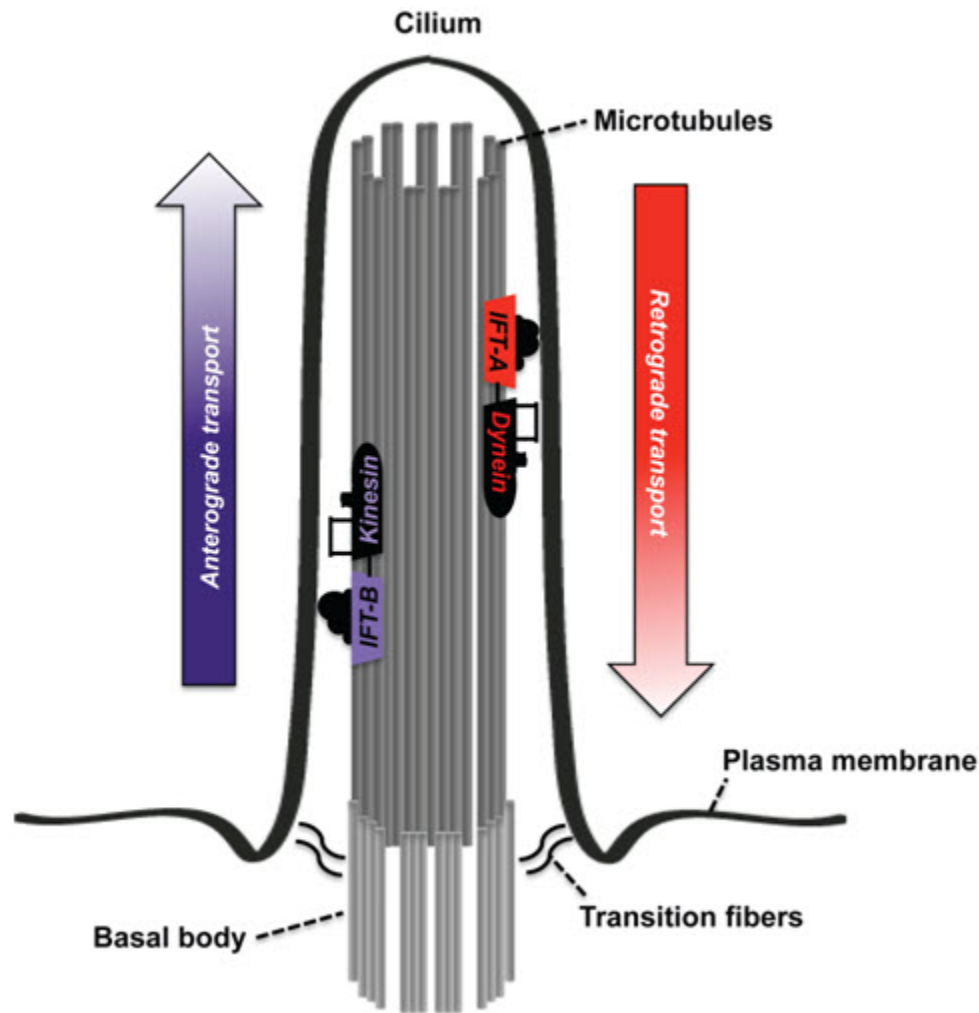


Figure 2. Schematic architecture of a cilium and ciliary transport

The cilium is a tail-like protrusion from the apical plasma membrane of the cell. It is composed of two compartments: the basal body from which the cilium is initially assembled, and the ciliary axoneme that protrudes from the plasma membrane. Cilia assembly and signaling depend on ciliary transport known as intraflagellar transport (IFT). This transport process occurs bidirectionally along the axonemal microtubules from the ciliary base to its tip (anterograde transport) and back (retrograde transport). While anterograde transport is driven by the kinesin-2 motor and the IFT-B complex, the dynein-2 motor and the IFT-A complex regulate transport in the opposite direction. The IFT-A complex consists of six different proteins; biallelic pathogenic variants have been identified in four of the six genes that encode these IFT-A complex proteins in individuals with cranioectodermal dysplasia. The IFT-B complex consists of at least 12 proteins.

Table 5. Recommended Evaluations Following Initial Diagnosis in Individuals with Cranioectodermal Dysplasia

System/Concern	Evaluation	Comment
Sagittal craniosynostosis	Head CT exam in those w/dolichocephaly	To evaluate for craniosynostosis
Skeletal features	Radiograph of thorax & long bones	
Ectodermal manifestations	Physical exam of skin, hair, nails, & teeth	
Dental anomalies	Dental eval	

Table 5. continued from previous page.

System/Concern	Evaluation	Comment
Nephronophthisis	<ul style="list-style-type: none"> • Urinalysis (first AM void) (& optional 24-hour urine collection) to identify polyuria • Osmolarity testing on morning urine • Blood pressure • Serum creatinine & blood urea concentration • Renal ultrasound exam 	Renal biopsy is often taken after detection of abnormalities.
Hepatic fibrosis	<ul style="list-style-type: none"> • Liver ultrasound exam • Measurement of transaminases & synthetic liver function 	
Retinal dystrophy	Ophthalmologic eval	By age 4 yrs; ERG & funduscopy can be performed earlier if evidence of ↓ vision.
Pulmonary manifestations (respiratory distress, asthma, pneumothorax)	Eval by pulmonologist	
Cardiac malformations	Cardiac eval incl EKG & echocardiogram	
Developmental delay	Developmental eval	Brain MRI in those w/delays to assess cause
Genetic counseling	By genetics professionals ¹	To inform affected persons & families re nature, MOI, & implications of CED to facilitate medical & personal decision making
Family support & resources	By clinicians, wider care team, & family support organizations	<p>Assessment of family & social structure to determine need for:</p> <ul style="list-style-type: none"> • Community or online resources such as Parent to Parent • Social work involvement for parental support • Home nursing referral

CED = cranioectodermal dysplasia; EKG = electrocardiogram; ERG = electroretinography; MOI = mode of inheritance

1. Medical geneticist, certified genetic counselor, or certified advanced genetic nurse

Treatment of Manifestations

Table 6. Treatment of Manifestations in Individuals with Cranioectodermal Dysplasia

Manifestation/Concern	Treatment	Considerations/Other
Craniosynostosis	Surgical treatment usually in 1st yr of life	
Polydactyly	Surgical correction is optional.	
Hip dysplasia	Orthopedic care as required	
Short stature	Growth hormone treatment when standard criteria for this treatment are met	Only for those children w/severe growth deficiency in whom therapy is expected to be successful.
Dental anomalies	Standard treatment per dentist &/or oral surgeon	Timely intervention of structural tooth abnormalities &/or oligodontia may limit aesthetic, functional, & psychological issues.

Table 6. continued from previous page.

Manifestation/Concern	Treatment	Considerations/Other
Nephronophthisis	Treatment per nephrologist	Renal transplantation is an option in advanced stages.
Hepatic fibrosis	Treatment per hepatologist	Liver transplantation is treatment option in advanced stages.
Progressive visual impairment	Low-vision aids per ophthalmologist & appropriate educational programs	
Pulmonary hypoplasia	Mechanical ventilation may be required in affected newborns.	
Respiratory infections	<ul style="list-style-type: none"> Chest radiograph & sputum analysis if pneumonia suspected Antibiotics as indicated 	Those susceptible to recurrent respiratory infections should be treated w/long-term prophylaxis.
Cardiac malformations	Treatment per cardiologist	
Developmental delay	<ul style="list-style-type: none"> Speech therapy & PT Early intervention &/or IEP as needed 	
Inguinal/umbilical hernias	Surgical intervention	

IEP = individualized educational plan; PT = physical therapy

Surveillance

Table 7. Recommended Surveillance for Individuals with Cranioectodermal Dysplasia

System/Concern	Evaluation	Frequency
Dental anomalies	Dental exam to detect tooth damage & oligodontia	Every 6 mos beginning at age 1 yr
Nephronophthisis	<ul style="list-style-type: none"> Osmolarity testing in AM urine Urine collection assays to test for polyuria Blood pressure Serum creatinine & blood urea concentration Renal ultrasound exam to determine renal size & presence of cysts 	Per clinical course & per nephrologist after diagnosis
Hepatic fibrosis	Measurement of transaminases & synthetic liver function	Per clinical course & per hepatologist after diagnosis
Retinal dystrophy	Ophthalmologic exams	Annually starting at age 4 yrs; ERG & funduscopy can be performed earlier if evidence of ↓ vision.
Cardiac malformations	Cardiac exam, EKG, & echocardiography per cardiologist	Per clinical course & per cardiologist recommendations, depending on initial findings after diagnosis
Developmental delay	Developmental eval	<ul style="list-style-type: none"> W/each visit during infancy & childhood Formal eval w/neuropsychologist if delays are present

EKG = electrocardiogram; ERG = electroretinography

Agents/Circumstances to Avoid

If kidney disease is present, a nephrologist may recommend reduction of potassium and phosphorus from the diet.

Nephrotoxic medications, including the NSAID class of drugs, may also be a relative contraindication in individuals with kidney involvement. Individuals should be under the care of a nephrologist, if indicated, to discuss what nephrotoxic agents to avoid.

Evaluation of Relatives at Risk

If the CED-causing pathogenic variants have been identified in an affected family member, it is appropriate to clarify the genetic status of at-risk infants to allow early diagnosis and appropriate management and surveillance, particularly for respiratory complications, renal and liver disease, and visual impairment.

If the pathogenic variants are not known in a family, the following is recommended for at-risk children:

- **In the newborn.** Physical examination by a pediatrician; consultation with a clinical geneticist as determined by the clinical findings
- **By age three months.** Kidney and liver evaluation including ultrasound examination and measurement of blood pressure, serum creatinine concentration, and liver enzymes
- **At six-month intervals.** Repeat kidney and liver evaluation

Parents should be alerted to the signs of CED and advised to contact their child's health care provider if suspicious symptoms, such as polydipsia and/or jaundice, appear.

See Genetic Counseling for issues related to testing of at-risk relatives for genetic counseling purposes.

Therapies Under Investigation

Search [ClinicalTrials.gov](https://clinicaltrials.gov) in the US and [EU Clinical Trials Register](https://clinicaltrialsregister.eu) in Europe for information on clinical studies for a wide range of diseases and conditions. Note: There may not be clinical trials for this disorder.

Genetic Counseling

Genetic counseling is the process of providing individuals and families with information on the nature, mode(s) of inheritance, and implications of genetic disorders to help them make informed medical and personal decisions. The following section deals with genetic risk assessment and the use of family history and genetic testing to clarify genetic status for family members; it is not meant to address all personal, cultural, or ethical issues that may arise or to substitute for consultation with a genetics professional. —ED.

Mode of Inheritance

Cranioectodermal dysplasia (CED) is inherited in an autosomal recessive manner.

Risk to Family Members

Parents of a proband

- The parents of an affected child are obligate heterozygotes (i.e., presumed to be carriers of one CED-causing pathogenic variant based on family history).
- Molecular genetic testing is recommended for the parents of a proband to confirm that both parents are heterozygous for a CED-causing pathogenic variant and to allow reliable recurrence risk assessment. If a pathogenic variant is detected in only one parent, the following possibilities should be considered:
 - One of the pathogenic variants identified in the proband occurred as a *de novo* event in the proband or as a postzygotic *de novo* event in a mosaic parent [Walczak-Sztulpa et al 2010, Jónsson et al 2017].
 - Uniparental isodisomy for the parental chromosome with the pathogenic variant resulted in homozygosity for the pathogenic variant in the proband.
- Heterozygotes (carriers) are asymptomatic and are not at risk of developing the disorder.

Sibs of a proband

- If both parents are known to be heterozygous for a CED-causing pathogenic variant, each sib of an affected individual has at conception a 25% chance of being affected, a 50% chance of being an asymptomatic carrier, and a 25% chance of being unaffected and not a carrier.
- Clinical manifestations of CED are highly variable and may differ among affected sibs.
- Heterozygotes (carriers) are asymptomatic and are not at risk of developing the disorder.

Offspring of a proband. Due to the rarity of CED and lack of longitudinal follow up, it is currently unknown whether individuals with CED are fertile. No individuals with CED have been reported to reproduce. This may be due to the severity of the disorder and to limited life expectancy.

Other family members. If both parents are known to be heterozygous for a CED-causing pathogenic variant, each sib of the proband's parents is at a 50% risk of being a carrier.

Carrier Detection

Carrier testing for at-risk relatives requires prior identification of the CED-causing pathogenic variants in the family.

Related Genetic Counseling Issues

See Management, Evaluation of Relatives at Risk for information on evaluating at-risk relatives for the purpose of early diagnosis and treatment.

Family planning

- The optimal time for determination of genetic risk and discussion of the availability of prenatal/preimplantation genetic testing is before pregnancy.
- It is appropriate to offer genetic counseling (including discussion of potential risks to offspring and reproductive options) to young adults who are affected, are carriers, or are at risk of being carriers.

DNA banking. Because it is likely that testing methodology and our understanding of genes, pathogenic mechanisms, and diseases will improve in the future, consideration should be given to banking DNA from probands in whom a molecular diagnosis has not been confirmed (i.e., the causative pathogenic mechanism is unknown). For more information, see Huang et al [2022].

Prenatal Testing and Preimplantation Genetic Testing

Molecular genetic testing. Once the CED-causing pathogenic variants have been identified in an affected family member, prenatal and preimplantation genetic testing are possible.

Fetal ultrasound examination. Second-trimester ultrasound examination may detect renal cysts, shortening of the limbs, and/or polydactyly.

Differences in perspective may exist among medical professionals and within families regarding the use of prenatal testing. While most centers would consider use of prenatal testing to be a personal decision, discussion of these issues may be helpful.

Resources

GeneReviews staff has selected the following disease-specific and/or umbrella support organizations and/or registries for the benefit of individuals with this disorder and their families. GeneReviews is not responsible for the information provided by other organizations. For information on selection criteria, click [here](#).

- **National Foundation for Ectodermal Dysplasias (NFED)**
Phone: 618-566-2020
Email: info@nfed.org
www.nfed.org
- **Ectodermal Dysplasias International Registry**
Email: info@nfed.org
[Ectodermal Dysplasias International Registry](http://EctodermalDysplasiasInternationalRegistry.org)

Molecular Genetics

Information in the Molecular Genetics and OMIM tables may differ from that elsewhere in the GeneReview: tables may contain more recent information. —ED.

Table A. Cranioectodermal Dysplasia: Genes and Databases

Gene	Chromosome Locus	Protein	Locus-Specific Databases	HGMD	ClinVar
<i>IFT43</i>	14q24.3	Intraflagellar transport protein 43 homolog		IFT43	IFT43
<i>IFT52</i>	20q13.12	Intraflagellar transport protein 52 homolog		IFT52	IFT52
<i>IFT122</i>	3q21.3-q22.1	Intraflagellar transport protein 122 homolog	IFT122 database	IFT122	IFT122
<i>IFT140</i>	16p13.3	Intraflagellar transport protein 140 homolog	IFT140 @ LOVD	IFT140	IFT140
<i>WDR19</i>	4p14	WD repeat-containing protein 19	WDR19 @ LOVD	WDR19	WDR19
<i>WDR35</i>	2p24.1	WD repeat-containing protein 35		WDR35	WDR35

Data are compiled from the following standard references: gene from [HGNC](#); chromosome locus from [OMIM](#); protein from [UniProt](#). For a description of databases (Locus Specific, HGMD, ClinVar) to which links are provided, click [here](#).

Table B. OMIM Entries for Cranioectodermal Dysplasia ([View All in OMIM](#))

218330	CRANIOECTODERMAL DYSPLASIA 1; CED1
606045	INTRAFLAGELLAR TRANSPORT 122; IFT122
608151	WD REPEAT-CONTAINING PROTEIN 19; WDR19
613602	WD REPEAT-CONTAINING PROTEIN 35; WDR35
613610	CRANIOECTODERMAL DYSPLASIA 2; CED2
614068	INTRAFLAGELLAR TRANSPORT 43; IFT43
614099	CRANIOECTODERMAL DYSPLASIA 3; CED3
614378	CRANIOECTODERMAL DYSPLASIA 4; CED4
614620	INTRAFLAGELLAR TRANSPORT 140; IFT140
617094	INTRAFLAGELLAR TRANSPORT 52; IFT52

Molecular Pathogenesis

Cranioectodermal dysplasia (CED) belongs to a spectrum of disorders known as ciliopathies [Baker & Beales 2009, Konstantinidou et al 2009, Arts & Knoers 2013]. Ciliopathies are thought to result from defects in cilia (see Figure 2), projections from the cell that occur almost ubiquitously throughout the human body. These microtubule-based organelles are thought to function as signaling hubs regulating pathways that are essential for normal human development and tissue homeostasis [Hildebrandt et al 2011].

A process that is required for ciliogenesis and regulation of signaling pathways is ciliary transport (also known as intraflagellar transport [IFT]) [Hildebrandt et al 2011, Taschner et al 2012]. Upward (anterograde) movement of cargo or signaling molecules occurs through the multi-subunit IFT-B complex in association with the heterotrimeric kinesin-2 motor, while downward (i.e., tip-to-base [retrograde]) ciliary transport is regulated by the dynein-2 motor in association with the IFT-A complex [Hildebrandt et al 2011, Taschner et al 2012].

Most pathogenic variants in individuals with CED identified to date occur in genes that encode members of the IFT-A hexamere protein complex: *IFT122* (previously *WDR10*), *WDR35* (*IFT121*), *WDR19* (*IFT144*), *IFT43* (previously *C14orf179*), or *IFT140* [Gilissen et al 2010, Arts et al 2011, Bredrup et al 2011, Bacino et al 2012, Hoffer et al 2013, Lin et al 2013, Caparrós-Martín et al 2015]. The remaining IFT-A complex member is encoded by *TTC21B*. Of note, genes encoding the proteins IFT139, IFT140, and *DYNC2H1* (a subunit of dynein-2 motor) are mutated in disorders that clinically overlap with CED (see Differential Diagnosis) [Dagoneau et al 2009, Davis et al 2011, Perrault et al 2012].

When the IFT-A protein complex is disrupted in CED, cilia in fibroblasts have bulging tips, which contain accumulations of IFT-B complex proteins that normally regulate base-to-tip (anterograde) ciliary transport [Arts et al 2011, Bredrup et al 2011].

Pathogenic variants in *IFT52*, which encodes part of the IFT-B protein complex, have also been reported to cause CED [Girisha et al 2016].

Although shortening of cilia in fibroblasts from persons with CED has also been reported [Walczak-Sztulpa et al 2010], this is not always observed [Bredrup et al 2011]. It is thought that defective IFT and resulting structural defects in the ciliary architecture disturb important developmental signaling cascades (e.g., hedgehog signaling), resulting in CED [Walczak-Sztulpa et al 2010, Ocbina et al 2011, Qin et al 2011, Liem et al 2012].

Mechanism of disease causation. Loss of function

Gene-specific laboratory considerations. A pathogenic variant in *IFT140* resulting in a tandem duplication has been identified.

Chapter Notes

Author Notes

This work was funded by the grants from the Dutch Kidney Foundation (CP11.18 "KOUNCIL" to N Knoers and H Arts) and the Netherlands Organization for Health Research and Development (ZonMw 91613008 to H Arts); both projects aim to unravel the genetics and mechanisms of disease of renal ciliopathies including Sensenbrenner syndrome.

Acknowledgments

We are thankful for the participation of the Sensenbrenner syndrome families in our study and for their consent for publication of clinical images. We also thank Dr E Lapi and Dr E Andreucci for their clinical contribution,

Dr C Marcelis, Dr N van de Kar, Dr L Koster-Kamphuis, and Dr K Noordam for useful discussions, and Prof Dr HG Brunner for communication.

Author History

Heleen Arts, PhD; McMaster University (2013-2021)

Kim Keppler-Noreuil, MD (2021-present)

Nine Knoers, MD, PhD; University Medical Center Groningen (2013-2021)

Angela Lin, MD (2021-present)

Weizhen Tan, MD (2021-present)

Revision History

- 15 December 2022 (aa) Revision: added *IFT140*-related autosomal dominant polycystic kidney disease to Genetically Related Disorders
- 11 March 2021 (sw) Comprehensive update posted live
- 12 April 2018 (ha) Revision: Lin et al [2013] added
- 12 September 2013 (me) Review posted live
- 26 April 2012 (ha) Original submission

References

Literature Cited

- Ackah RL, Yoeli D, Kueht M, Galván NTN, Cotton RT, Rana A, O'Mahony CA, Goss JA. Orthotopic liver transplantation for Sensenbrenner syndrome. *Pediatr Transplant*. 2018;22. PubMed PMID: 29076289.
- Alazami AM, Seidahmed MZ, Alzahrani F, Mohammed AO, Alkuraya FS. Novel IFT122 mutation associated with impaired ciliogenesis and cranioectodermal dysplasia. *Mol Genet Genomic Med*. 2014;2:103–6. PubMed PMID: 24689072.
- Antony D, Nampoory N, Bacchelli C, Melhem M, Wu K, James CT, Beales PL, Hubank M, Thomas D, Mashankar A, Behbehani K, Schmidts M, Alsmadi O. Exome sequencing for the differential diagnosis of ciliary chondrodysplasias: Example of a WDR35 mutation case and review of the literature. *Eur J Med Genet*. 2017;60:658–66. PubMed PMID: 28870638.
- Arts HH, Bongers EM, Mans DA, van Beersum SE, Oud MM, Bolat E, Spruijt L, Cornelissen EA, Schuurs-Hoeijmakers JH, de Leeuw N, Cormier-Daire V, Brunner HG, Knoers NV, Roepman R. C14ORF179 encoding IFT43 is mutated in Sensenbrenner syndrome. *J Med Genet*. 2011;48:390–5. PubMed PMID: 21378380.
- Arts HH, Knoers NV. Current insights into renal ciliopathies: what can genetics teach us? *Pediatr Nephrol*. 2013;28:863–74. PubMed PMID: 22829176.
- Bacino CA, Dhar SU, Brunetti-Pierri N, Lee B, Bonnen PE. WDR35 mutation in siblings with Sensenbrenner syndrome: a ciliopathy with variable phenotype. *Am J Med Genet A*. 2012;158A:2917–24. PubMed PMID: 22987818.
- Baker K, Beales PL. Making sense of cilia in disease: the human ciliopathies. *Am J Med Genet C Semin Med Genet*. 2009;151C:281–95. PubMed PMID: 19876933.
- Baujat G, Le Merrer M. Ellis-van Creveld syndrome. *Orphanet J Rare Dis*. 2007;2:27. PubMed PMID: 17547743.
- Bayat A, Kerr B, Douzgou S, et al. The evolving craniofacial phenotype of a patient with Sensenbrenner syndrome caused by IFT140 compound heterozygous mutations. *Clin Dysmorphol*. 2017;26:247–51. PubMed PMID: 28288023.

- Bredrup C, Saunier S, Oud MM, Fiskerstrand T, Hoischen A, Brackman D, Leh SM, Midtbø M, Filhol E, Bole-Feysot C, Nitschké P, Gilissen C, Haugen OH, Sanders JS, Stolte-Dijkstra I, Mans DA, Steenbergen EJ, Hamel BC, Matignon M, Pfundt R, Jeanpierre C, Boman H, Rødahl E, Veltman JA, Knappskog PM, Knoers NV, Roepman R, Arts HH. Ciliopathies with skeletal anomalies and renal insufficiency due to mutations in the IFT-A gene WDR19. *Am J Hum Genet.* 2011;89:634–43. PubMed PMID: 22019273.
- Caparrós-Martín JA, De Luca A, Cartault F, Aglan M, Temtamy S, Otaify GA, Mehrez M, Valencia M, Vázquez L, Alessandri JL, Nevado J, Rueda-Arenas I, Heath KE, Digilio MC, Dallapiccola B, Goodship JA, Mill P, Lapunzina P, Ruiz-Perez VL. Specific variants in WDR35 cause a distinctive form of Ellis-van Creveld syndrome by disrupting the recruitment of the EvC complex and SMO into the cilium. *Hum Mol Genet.* 2015;24:4126–37. PubMed PMID: 25908617.
- Córdova-Fletes C, Becerra-Solano LE, Rangel-Sosa MM, Rivas-Estilla AM, Alberto Galán-Huerta K, Ortiz-López R, Rojas-Martínez A, Juárez-Vázquez CI, García-Ortiz JE. Uncommon runs of homozygosity disclose homozygous missense mutations in two ciliopathy-related genes (SPAG17 and WDR35) in a patient with multiple brain and skeletal anomalies. *Eur J Med Genet.* 2018;61:161–7. PubMed PMID: 29174089.
- Dagoneau N, Goulet M, Geneviève D, Sznajder Y, Martinovic J, Smithson S, Huber C, Baujat G, Flori E, Tecco L, Cavalcanti D, Delezoide AL, Serre V, Le Merrer M, Munnich A, Cormier-Daire V. DYNC2H1 mutations cause asphyxiating thoracic dystrophy and short rib-polydactyly syndrome, type III. *Am J Hum Genet.* 2009;84:706–11. PubMed PMID: 19442771.
- Daoud H, Luco SM, Li R, Bareke E, Beaulieu C, Jarinova O, Carson N, Nikkel SM, Graham GE, Richer J, Armour C, Bulman DE, Chakraborty P, Geraghty M, Lines MA, Lacaze-Masmonteil T, Majewski J, Boycott KM, Dymont DA. Next-generation sequencing for diagnosis of rare diseases in the neonatal intensive care unit. *CMAJ.* 2016;188:E254–E260. PubMed PMID: 27241786.
- Davis EE, Zhang Q, Liu Q, Diplas BH, Davey LM, Hartley J, Stoetzel C, Szymanska K, Ramaswami G, Logan CV, Muzny DM, Young AC, Wheeler DA, Cruz P, Morgan M, Lewis LR, Cherukuri P, Maskeri B, Hansen NF, Mullikin JC, Blakesley RW, Bouffard GG, Gyapay G, Rieger S, Tönshoff B, Kern I, Soliman NA, Neuhaus TJ, Swoboda KJ, Kayserili H, Gallagher TE, Lewis RA, Bergmann C, Otto EA, Saunier S, Scambler PJ, Beales PL, Gleeson JG, Maher ER, Attié-Bitach T, Dollfus H, Johnson CA, Green ED, Gibbs RA, Hildebrandt F, Pierce EA, Katsanis N, et al. TTC21B contributes both causal and modifying alleles across the ciliopathy spectrum. *Nat Genet.* 2011;43:189–96. PubMed PMID: 21258341.
- Eke T, Woodruff G, Young ID. A new oculorenal syndrome: retinal dystrophy and tubulointerstitial nephropathy in cranioectodermal dysplasia. *Br J Ophthalmol.* 1996;80:490–1. PubMed PMID: 8695580.
- Elçioglu NH, Hall CM. Diagnostic dilemmas in the short rib-polydactyly syndrome group. *Am J Med Genet.* 2002;111:392–400. PubMed PMID: 12210298.
- Fry AE, Klingenberg C, Matthes J, Heimdal K, Hennekam RC, Pilz DT. Connective tissue involvement in two patients with features of cranioectodermal dysplasia. *Am J Med Genet A.* 2009;149A:2212–5. PubMed PMID: 19760620.
- Gilissen C, Arts HH, Hoischen A, Spruijt L, Mans DA, Arts P, van Lier B, Steehouwer M, van Reeuwijk J, Kant SG, Roepman R, Knoers NV, Veltman JA, Brunner HG. Exome sequencing identifies WDR35 variants involved in Sensenbrenner syndrome. *Am J Hum Genet.* 2010;87:418–23. PubMed PMID: 20817137.
- Girisha KM, Shukla A, Trujillano D, Bhavani GS, Hebbar M, Kadavigere R, Rolfs A. A homozygous nonsense variant in IFT52 is associated with a human skeletal ciliopathy. *Clin Genet.* 2016;90:536–9. PubMed PMID: 26880018.
- Hildebrandt F, Benzing T, Katsanis N. Ciliopathies. *N Engl J Med.* 2011;364:1533–43. PubMed PMID: 21506742.
- Hoffer JL, Fryssira H, Konstantinidou AE, Ropers HH, Tzschach A. Novel WDR35 mutations in patients with cranioectodermal dysplasia (Sensenbrenner syndrome). *Clin Genet.* 2013;83:92–5. PubMed PMID: 22486404.

- Huang SJ, Amendola LM, Sternen DL. Variation among DNA banking consent forms: points for clinicians to bank on. *J Community Genet.* 2022;13:389–97. PubMed PMID: 35834113.
- Huber C, Cormier-Daire V. Ciliary disorder of the skeleton. *Am J Med Genet C Semin Med Genet.* 2012;160C:165–74. PubMed PMID: 22791528.
- Jónsson H, Sulem P, Kehr B, Kristmundsdóttir S, Zink F, Hjartarson E, Hardarson MT, Hjorleifsson KE, Eggertsson HP, Gudjonsson SA, Ward LD, Arnadóttir GA, Helgason EA, Helgason H, Gylfason A, Jonasdóttir A, Jonasdóttir A, Rafnar T, Frigge M, Stacey SN, Th Magnusson O, Thorsteinsdóttir U, Masson G, Kong A, Halldorsson BV, Helgason A, Gudbjartsson DF, Stefansson K. Parental influence on human germline de novo mutations in 1,548 trios from Iceland. *Nature.* 2017;549:519–22. PubMed PMID: 28959963.
- Konstantinidou AE, Fryssira H, Sifakis S, Karadimas C, Kaminopetros P, Agrogiannis G, Velonis S, Nikkels PG, Patsouris E. Cranioectodermal dysplasia: a probable ciliopathy. *Am J Med Genet A.* 2009;149A:2206–11. PubMed PMID: 19760621.
- Levin LS, Perrin JC, Ose L, Dorst JP, Miller JD, McKusick VA. A heritable syndrome of craniosynostosis, short thin hair, dental abnormalities, and short limbs: cranioectodermal dysplasia. *J Pediatr.* 1977;90:55–61. PubMed PMID: 830894.
- Li Y, Garrod AS, Madan-Khetarpal S, Sreedher G, McGuire M, Yagi H, Klena NT, Gabriel GC, Khalifa O, Zahid M, Panigrahy A, Weiner DJ, Lo CW. Respiratory motile cilia dysfunction in a patient with cranioectodermal dysplasia. *Am J Med Genet A.* 2015;167A:2188–96. PubMed PMID: 25914204.
- Liem KF Jr, Ashe A, He M, Satir P, Moran J, Beier D, Wicking C, Anderson KV. The IFT-A complex regulates Shh signaling through cilia structure and membrane protein trafficking. *J Cell Biol.* 2012;197:789–800. PubMed PMID: 22689656.
- Lin AE, Traum AZ, Sahai I, Keppler-Noreuil K, Kukolich MK, Adam MP, Westra SJ, Arts HH. Sensenbrenner syndrome (cranioectodermal dysplasia): clinical and molecular analyses of 39 patients including two new patients. *Am J Med Genet A.* 2013;161A:2762–76. PubMed PMID: 24123776.
- Moosa S, Obregon MG, Altmüller J, Thiele H, Nürnberg P, Fano V, Wollnik B. Novel IFT122 mutations in three Argentinian patients with cranioectodermal dysplasia: Expanding the mutational spectrum. *Am J Med Genet A.* 2016;170A:1295–301. PubMed PMID: 26792575.
- Mortier GR, Cohn DH, Cormier-Daire V, Hall C, Krakow D, Mundlos S, Nishimura G, Robertson S, Sangiorgi L, Savarirayan R, Sillence D, Superti-Furga A, Unger S, Warman ML. Nosology and classification of genetic skeletal disorders: 2019 revision. *Am J Med Genet A.* 2019;179:2393–419. PubMed PMID: 31633310.
- Oberklaid F, Danks DM, Mayne V, Campbell P. Asphyxiating thoracic dysplasia. Clinical, radiological, and pathological information on 10 patients. *Arch Dis Child.* 1977;52:758–65. PubMed PMID: 931421.
- Obikane K, Nakashima T, Watarai Y, Morita K, Cho K, Tonoki H, Nagata M, Sasaki S. Renal failure due to tubulointerstitial nephropathy in an infant with cranioectodermal dysplasia. *Pediatr Nephrol.* 2006;21:574–6. PubMed PMID: 16491415.
- Ocbina PJ, Eggenschwiler JT, Moskowitz I, Anderson KV. Complex interactions between genes controlling trafficking in primary cilia. *Nat Genet.* 2011;43:547–53. PubMed PMID: 21552265.
- Peña-Padilla C, Marshall CR, Walker S, Scherer SW, Tavares-Macías G, Razo-Jiménez G, Bobadilla-Morales L, Acosta-Fernández E, Corona-Rivera A, Mendoza-Londono R, Corona-Rivera JR. Compound heterozygous mutations in the IFT140 gene cause Opitz trigonocephaly C syndrome in a patient with typical features of a ciliopathy. *Clin Genet.* 2017;91:640–6. PubMed PMID: 27874174.
- Perrault I, Saunier S, Hanein S, Filhol E, Bizet AA, Collins F, Salih MA, Gerber S, Delphin N, Bigot K, Orssaud C, Silva E, Baudouin V, Oud MM, Shannon N, Le Merrer M, Roche O, Pietrement C, Goumid J, Baumann C, Bole-Feysot C, Nitschke P, Zahrate M, Beales P, Arts HH, Munnich A, Kaplan J, Antignac C, Cormier-Daire

- V, Rozet JM. Mainzer-Saldino syndrome is a ciliopathy caused by IFT140 mutations. *Am J Hum Genet.* 2012;90:864–70. PubMed PMID: 22503633.
- Qin J, Lin Y, Norman RX, Ko HW, Eggenschwiler JT. Intraflagellar transport protein 122 antagonizes Sonic Hedgehog signaling and controls ciliary localization of pathway components. *Proc Natl Acad Sci U S A.* 2011;108:1456–61. PubMed PMID: 21209331.
- Richards S, Aziz N, Bale S, Bick D, Das S, Gastier-Foster J, Grody WW, Hegde M, Lyon E, Spector E, Voelkerding K, Rehm HL, et al. Standards and guidelines for the interpretation of sequence variants: a joint consensus recommendation of the American College of Medical Genetics and Genomics and the Association for Molecular Pathology. *Genet Med.* 2015;17:405–24. PubMed PMID: 25741868.
- Ruiz-Perez VL, Ide SE, Strom TM, Lorenz B, Wilson D, Woods K, King L, Francomano C, Freisinger P, Spranger S, Marino B, Dallapiccola B, Wright M, Meitinger T, Polymeropoulos MH, Goodship J. Mutations in a new gene in Ellis-van Creveld syndrome and Weyers acrorenal dysostosis. *Nat Genet.* 2000;24:283–6. PubMed PMID: 10700184.
- Savill GA, Young ID, Cunningham RJ, Ansell I, Evans JH. Chronic tubulo-interstitial nephropathy in children with cranioectodermal dysplasia. *Pediatr Nephrol.* 1997;11:215–7. PubMed PMID: 9090669.
- Sensenbrenner JA, Dorst JP, Owens RP. New syndrome of skeletal, dental and hair anomalies. *Birth Defects Orig Artic Ser.* 1975;11:372–9. PubMed PMID: 1227553.
- Silveira KC, Moreno CA, Cavalcanti DP. Beemer-Langer syndrome is a ciliopathy due to biallelic mutations in IFT122. *Am J Med Genet A.* 2017;173:1186–9. PubMed PMID: 28370949.
- Smith C, Lamont RE, Wade A, Bernier FP, Parboosingh JS, Innes AM. A relatively mild skeletal ciliopathy phenotype consistent with cranioectodermal dysplasia is associated with a homozygous nonsynonymous mutation in WDR35. *Am J Med Genet A.* 2016;170:760–5. PubMed PMID: 26691894.
- Stenson PD, Mort M, Ball EV, Chapman M, Evans K, Azevedo L, Hayden M, Heywood S, Millar DS, Phillips AD, Cooper DN. The Human Gene Mutation Database (HGMD®): optimizing its use in a clinical diagnostic or research setting. *Hum Genet.* 2020;139:1197–207. PubMed PMID: 32596782.
- Tamai S, Tojo M, Kamimaki T, Sato Y, Nishimura G. Intrafamilial phenotypic variations in cranioectodermal dysplasia: proband with typical manifestations and her brother with perinatal death. *Am J Med Genet.* 2002;107:78–80. PubMed PMID: 11807876.
- Taschner M, Bhogaraju S, Lorentzen E. Architecture and function of IFT complex proteins in ciliogenesis. *Differentiation.* 2012;83:S12–22. PubMed PMID: 22118932.
- Tsurusaki Y, Yonezawa R, Furuya M, Nishimura G, Pooh R, Nakashima M, Saito H, Miyake N, Saito S, Matsumoto N. Whole exome sequencing revealed biallelic IFT122 mutations in a family with CED1 and recurrent pregnancy loss. *Clin Genet.* 2014;85:592–4. PubMed PMID: 23826986.
- Walczak-Sztulpa J, Eggenschwiler J, Osborn D, Brown DA, Emma F, Klingenberg C, Hennekam RC, Torre G, Garshasbi M, Tzschach A, Szczepanska M, Krawczynski M, Zachwieja J, Zwolinska D, Beales PL, Ropers HH, Latos-Bielenska A, Kuss AW. Cranioectodermal Dysplasia, Sensenbrenner syndrome, is a ciliopathy caused by mutations in the IFT122 gene. *Am J Hum Genet.* 2010;86:949–56. PubMed PMID: 20493458.
- Walczak-Sztulpa J, Posmyk R, Bukowska-Olech EM, Wawrocka A, Jamsheer A, Oud MM, Schmidts M, Arts HH, Latos-Bielenska A, Wasilewska A. Compound heterozygous IFT140 variants in two Polish families with Sensenbrenner syndrome and early onset end-stage renal disease. *Orphanet J Rare Dis.* 2020;15:36. PubMed PMID: 32007091.
- Walczak-Sztulpa J, Wawrocka A, Sobierajewicz A, Kuszel L, Zawadzki J, Grenda R, Swiader-Lesniak A, Kocyla-Karczmarewicz B, Wnuk A, Latos-Bielenska A, Chrzanowska KH. Intrafamilial phenotypic variability in a Polish family with Sensenbrenner syndrome and biallelic WDR35 mutations. *Am J Med Genet A.* 2017;173:1364–8. PubMed PMID: 28332779.

- Walczak-Sztulpa J, Wawrocka A, Swiader-Lesniak A, Socha M, Jamsheer A, Drozd D, Latos-Bielenska A, Zachwieja K. Clinical and molecular genetic characterization of a male patient with Sensenbrenner syndrome (cranioectodermal dysplasia) and biallelic WDR35 mutations. *Birth Defects Res.* 2018;110:376–81. PubMed PMID: 29134781.
- Xu W, Jin M, Hu R, Wang H, Zhang F, Yuan S, Cao Y. The Joubert syndrome protein Inpp5e controls ciliogenesis by regulating phosphoinositides at the apical membrane. *J Am Soc Nephrol.* 2017;28:118–29. PubMed PMID: 27401686.
- Yoshikawa T, Kamei K, Nagata H, Saida K, Sato M, Ogura M, Ito S, Miyazaki O, Urushihara M, Kondo S, Sugawara N, Ishizuka K, Hamasaki Y, Shishido S, Morisada N, Iijima K, Nagata M, Yoshioka T, Ogata K, Ishikura K. Diversity of renal phenotypes in patients with WDR19 mutations: two case reports. *Nephrology (Carlton).* 2017;22:566–71. PubMed PMID: 28621010.
- Zaffanello M, Omedi-Camassei F, Melzi ML, Torre G, Callea F, Emma F. Sensenbrenner syndrome: a new member of the hepatorenal fibrocystic family. *Am J Med Genet A.* 2006;140:2336–40. PubMed PMID: 17022080.
- Zannolli R, Mostardini R, Carpentieri ML, Gatti MG, Galluzzi P, Terrosi Vagnoli P, Giorgetti R, Calvieri S, Morgese G. Cranioectodermal dysplasia: a new patient with an inapparent, subtle phenotype. *Pediatr Dermatol.* 2001;18:332–5. PubMed PMID: 11576410.

License

GeneReviews® chapters are owned by the University of Washington. Permission is hereby granted to reproduce, distribute, and translate copies of content materials for noncommercial research purposes only, provided that (i) credit for source (<http://www.genereviews.org/>) and copyright (© 1993-2024 University of Washington) are included with each copy; (ii) a link to the original material is provided whenever the material is published elsewhere on the Web; and (iii) reproducers, distributors, and/or translators comply with the [GeneReviews® Copyright Notice and Usage Disclaimer](#). No further modifications are allowed. For clarity, excerpts of GeneReviews chapters for use in lab reports and clinic notes are a permitted use.

For more information, see the [GeneReviews® Copyright Notice and Usage Disclaimer](#).

For questions regarding permissions or whether a specified use is allowed, contact: admasst@uw.edu.