U.S. National Library of Medicine
National Center for Biotechnology Information

NLM Citation: Leroy JG, Cathey SS, Friez MJ. *GNPTAB*-Related Disorders. 2008 Aug 26 [Updated 2019 Aug 29]. In: Adam MP, Feldman J, Mirzaa GM, et al., editors. GeneReviews® [Internet]. Seattle (WA): University of Washington, Seattle; 1993-2024.
Bookshelf URL: https://www.ncbi.nlm.nih.gov/books/

GNPTAB-Related Disorders

Jules G Leroy, MD, PhD,[1,2] Sara S Cathey, MD, FACMG,[3] and Michael J Friez, PhD[4]

Created: August 26, 2008; Updated: August 29, 2019.

Summary

Clinical characteristics

GNPTAB-related disorders comprise the phenotypes mucolipidosis II (ML II) and mucolipidosis IIIα/β (ML IIIα/β), and phenotypes intermediate between ML II and ML IIIα/β.

- **ML II** is evident at birth and slowly progressive; death most often occurs in early childhood. Orthopedic abnormalities present at birth may include thoracic deformity, kyphosis, clubfeet, deformed long bones, and/or dislocation of the hip(s). Growth often ceases in the second year of life; contractures develop in all large joints. The skin is thickened, facial features are coarse, and gingiva are hypertrophic. All children have cardiac involvement, most commonly thickening and insufficiency of the mitral valve and, less frequently, the aortic valve. Progressive mucosal thickening narrows the airways, and gradual stiffening of the thoracic cage contributes to respiratory insufficiency, the most common cause of death.
- **ML IIIα/β** becomes evident at about age three years with slow growth rate and short stature; joint stiffness and pain initially in the shoulders, hips, and fingers; gradual mild coarsening of facial features; and normal to mildly impaired cognitive development. Pain from osteoporosis becomes more severe during adolescence. Cardiorespiratory complications (restrictive lung disease, thickening and insufficiency of the mitral and aortic valves, left and/or right ventricular hypertrophy) are common causes of death, typically in early to middle adulthood.
- **Phenotypes intermediate between ML II and ML IIIα/β** are characterized by physical growth in infancy that resembles that of ML II and neuromotor and speech development that resemble that of ML IIIα/β.

Diagnosis/testing

The diagnosis of a *GNPTAB*-related disorder is established in a proband with suggestive clinical, radiographic, and biochemical findings and biallelic pathogenic (or likely pathogenic) variants in *GNPTAB* identified on molecular genetic testing.

Author Affiliations: 1 Professor and Chairman Emeritus, Departments of Pediatrics and Medical Genetics, Ghent University Hospital, Ghent, Belgium. 2 Senior Scholar, Greenwood Genetic Center, Greenwood, South Carolina. 3 Clinical Geneticist, Greenwood Genetic Center, Charleston, South Carolina. 4 Director, Diagnostic Laboratory, Greenwood Genetic Center, Greenwood, South Carolina.

Copyright © 1993-2024, University of Washington, Seattle. GeneReviews is a registered trademark of the University of Washington, Seattle. All rights reserved.

Management

Treatment of manifestations: Management is supportive and symptomatic.

- **ML II.** Low-impact therapies, including aqua therapy, to avoid joint and tendon strain; cognitive stimulation through interactive programs; gingivectomy as needed for oral health.
- **ML IIIα/β.** Low-impact physical therapy is usually well tolerated. Carpal tunnel signs may require tendon release. In late childhood or early adolescence symptomatic relief of hip pain with over-the-counter analgesics; in some older adolescents and adults bilateral hip replacement has been successful. Later in disease course: management focuses on relief of general bone pain caused by osteoporosis; scheduled intermittent IV administration of the bisphosphonate pamidronate has been effective in some individuals.
- **All phenotypes.** Because of concerns about airway management, surgical intervention should be avoided if possible and undertaken only in tertiary care settings.

Surveillance:

- **ML II.** Outpatient follow-up visits approximately every three months for infants and toddlers; outpatient visits approximately every six months for older children until cardiac and respiratory monitoring need to be more frequent.
- **ML IIIα/β.** Twice-yearly outpatient clinic visits for young children; annual routine follow-up visits after age six years unless bone pain, deteriorating ambulation, and/or cardiac and respiratory monitoring necessitate more frequent attention.

Genetic counseling

GNPTAB-related disorders are inherited in an autosomal recessive manner. At conception, each sib of an affected individual has a 25% chance of being affected, a 50% chance of being an asymptomatic carrier, and a 25% chance of being unaffected and not a carrier. Once the *GNPTAB* pathogenic variants in the family are known, carrier testing for at-risk relatives, prenatal testing for a pregnancy at increased risk, and preimplantation genetic testing are possible.

GeneReview Scope

GNPTAB-Related Disorders: Included Phenotypes [1]
• Mucolipidosis II (ML II) • Mucolipidosis IIIα/β (ML IIIα/β) • Phenotypes intermediate between ML II and IIIα/β

For synonyms and outdated names, see Nomenclature.
1. For other genetic causes of these phenotypes see Differential Diagnosis.

Diagnosis

Suggestive Findings

GNPTAB-related disorders (which include the phenotypes mucolipidosis II [ML II] and mucolipidosis IIIα/β [ML IIIα/β] and phenotypes intermediate between ML II and IIIα/β) **should be suspected** in individuals with the following age-related clinical and radiographic findings and supportive biochemical findings [Cathey et al 2010].

Clinical Findings

ML II – Neonatal period

- Small to low-normal anthropometric measurements for gestational age
- Restricted range of passive motion in the shoulders
- Flat face, shallow orbits, and depressed nasal bridge
- Thick skin with wax-like texture (in neonates, most evident in and around the earlobes)
- Variable musculoskeletal findings that may include one or more of the following:
  - Thoracic deformity including kyphosis
  - Clubfeet
  - Deformed long bones (See Figure 1.)
  - Dislocation of the hip(s)

ML II – Later infancy

- Dysmorphic facies and musculoskeletal features that may have been mistakenly overlooked at birth become undeniable over the first year of life: overall coarsening of features, poor growth, and restriction of joint movements at the hips, knees, shoulders, and hands.
- Developmental milestones are not met.

ML IIIα/β

- Onset late infancy to late childhood
- Musculoskeletal findings
  - Growth parameters are typically normal at birth. Growth rate slows in preschool and early school years
  - Joint stiffness in the shoulders, hips, and fingers
  - Joint pain that is exacerbated by strenuous exercise or vigorous physical therapy
  - Variable kyphoscoliosis, mild to severe
  - Osteoporosis associated with bone pain
- Gradual mild coarsening of facial features
- Slight corneal cloudiness (in some but not all) only by slit-lamp examination
- Upper-respiratory infection and/or otitis media (variably present)
- No organomegaly
- Developmental milestones are met appropriately with the exception of late walking in a minority of children with ML III. Language skills are normal. Cognitive development is usually normal, and most children attend regular classes, irrespective of the physical handicap that gradually worsens.

Phenotypes intermediate between ML II and ML IIIα/β. In phenotypes intermediate between ML II and ML IIIα/β physical growth in infancy resembles that in the ML II natural course; neuromotor and speech development follow the course of ML IIIα/β. Infants typically have some manifestations of ML II (large joint contractures, mild dorsolumbar kyphoscoliosis) followed by slow growth near the end of the second year leading to consideration of the diagnosis of ML II; however, findings after age three years resemble those of ML IIIα/β, leading to consideration of a diagnosis of ML II / ML IIIα/β.

Radiographic Findings

Mucolipidosis II. The radiographic phenotype of ML II is complete before the second birthday, when the set of abnormalities is read as "severe dysostosis multiplex," a concept introduced by Spranger in order to summarize the variable but common set of associated skeletal abnormalities found in the large family of disorders of complex carbohydrate degradation or of failing lysosomal transport [Spranger et al 2002].

The severe dysostosis multiplex in ML II includes the following [Spranger et al 2002]:

- Skeletal age is significantly delayed. Generalized osteopenia and coarse bony trabeculation are consistent findings.

Figure 1. Female age three years with ML II

- Skull size and shape remain near normal; the sella turcica becomes oblong in children surviving into middle childhood.
- All vertebral bodies have a much shortened anteroposterior diameter, are taller posteriorly than anteriorly, and have concave anterior borders and mildly convex superior and inferior borders.
- The length of large and small long bones is much reduced. All large appendicular long bones have undertubulated diaphyses, dysplastic and small epiphyses, and overconstriction of the submetaphyseal regions.
- Diaphyseal widening in all small long bones of the hands becomes pronounced by early childhood and is accompanied by progressive claw-type deformation.
- Ribs have widened costochondral junctions but narrowed juxtavertebral parts.
- Pelvic dysplasia is manifest as narrow basilar portions of the ilia and relatively long pubic and ischial bones; slanting, shallow acetabular roofs and bilateral coxa valga, with varying degrees of (often asymmetric) hip dislocation
- In the most severely affected infants, transient signs reminiscent of rickets and osteopenia, and punctate calcifications in soft tissue (most frequently about the tarsal bones) are observed. In most infants, periosteal cloaking is observed around the diaphyses of the large long bones; this transient phenomenon is rarely detectable after age one year.

Mucolipidosis IIIα/β. By age 5-10 years, the findings of mild dysostosis multiplex are apparent in children with ML IIIα/β:

- Generalized osteopenia is slowly progressive.
- The sella turcica remains normal as the calvarium thickens gradually. Cranial size remains proportional to stature.
- The mildly platyspondylic vertebra remain rectangular with irregular endplates, dorsal scalloping, and narrow intervertebral spaces. Kyphoscoliosis may become severe and requires orthopedic attention.
- The shortened long bones show normal or slightly undertubulated diaphyses, small epiphyses, and widened irregular metaphyses. Progressive dysplasia of the proximal femoral epiphyses may be asymmetric and quite severe.
- The shape and size of phalanges corresponds to metacarpal changes, which may be mildly shortened or completely normal. The carpal bones are often smaller than normal with irregular borders. Even in the event of normal or near-normal small hand bones, colinear axis deviation of the fingers is frequent due to slowly progressive hardening of periarticular and tendon connective tissue; true claw-type hand deformation is rare in ML IIIα/β, but carpal tunnel syndrome is a regular feature.

Supportive Biochemical Findings

Assay of oligosaccharides (OSs) in urine. When the degradation of glycoproteins is impaired certain partially degraded free oligosaccharides are largely excreted in urine; the analysis of these free oligosaccharide species (FOS) can be used as a first tier of screening for oligosaccharidosis, including *GNPTAB*-related disorders.

Historically, measurement of the accumulating oligosaccharides utilized older technologies such as thin layer chromatography (TLC). Although still widely used, TLC has several limitations including intrinsic poor resolution, interference from drugs and diet, subjective interpretation, and lack of quantification. Ultra-performance liquid chromatography-tandem mass spectrometry for FOS analysis is far more sensitive and specific.

Assay of several acid hydrolases. Because lysosomal hydrolase enzymes are not properly targeted to the lysosome in *GNPTAB*-related disorders, the enzyme activity of multiple lysosomal hydrolases is increased in plasma and other body fluids. Compared to normal controls, the activity of nearly all lysosomal hydrolases in *GNPTAB*-related disorders is five- to 20-fold higher in plasma and other body fluids. *GNPTAB*-related disorder screening can be done on dried blood spots or plasma using fluorometric or tandem mass spectrometry substrates. Elevation of multiple hydrolases is a positive screen.

Note: In *GNPTAB*-related disorders the acid hydrolases are probably not improperly targeted to the lysosomes in leukocytes, where they are not deficient quantitatively. In contrast to storage disorders resulting from deficiency of a single lysosomal enzyme, *GNPTAB*-related disorders cannot be diagnosed by assay of acid hydrolases in leukocytes.

Urinary excretion of glycosaminoglycans (GAGs). Although total GAGS may be elevated in some individuals with a *GNPTAB*-related disorder, this may be missed by TLC methods. UPLC-MS/MS analysis of FOS in a large cohort of individuals with ML documented elevated keratan sulfate. In *GNPTAB*-related disorders the keratan sulfate elevation was as elevated (4-fold) as in individuals with mucopolysaccharidosis IVA (MPS IVA). In ML IIIα/β, keratan sulfate ranged from normal to 1.3-fold elevations [Ellsworth et al 2017].

Click here (pdf) for information on testing used in the past to confirm the diagnosis of ML II and ML IIIα/β.

Establishing the Diagnosis

The diagnosis of a *GNPTAB*-related disorder **is established** in a proband with suggestive clinical and radiographic findings, supportive biochemical findings, and biallelic pathogenic (or likely pathogenic) variants in *GNPTAB* identified on molecular genetic testing (see Table 1).

Note: (1) Per ACMG/AMP variant interpretation guidelines, the terms "pathogenic variant" and "likely pathogenic variant" are synonymous in a clinical setting, meaning that both are considered diagnostic and can be used for clinical decision making [Richards et al 2015]. Reference to "pathogenic variants" in this *GeneReview* is understood to include any likely pathogenic variants. (2) Identification of biallelic *GNPTAB* variants of uncertain significance (or of one known *GNPTAB* pathogenic variant and one *GNPTAB* variant of uncertain significance) does not establish or rule out the diagnosis

Single-gene testing. Sequence analysis of *GNPTAB* detects missense, nonsense, and splice site variants and small intragenic deletions/insertions; typically, exon or whole-gene deletions/duplications are not detected. Perform sequence analysis first. If only one or no pathogenic variant is found perform gene-targeted deletion/duplication analysis to detect intragenic deletions or duplications.

Table 1. Molecular Genetic Testing Used in Mucolipidosis II / Mucolipidosis III α/β

Gene [1]	Method	Proportion of Pathogenic Variants [2] Detectable by Method
GNPTAB	Sequence analysis [3]	>95% [4]
	Gene-targeted deletion/duplication analysis [5]	3% [6]

1. See Table A. Genes and Databases for chromosome locus and protein.
2. See Molecular Genetics for information on variants detected in this gene.
3. Sequence analysis detects variants that are benign, likely benign, of uncertain significance, likely pathogenic, or pathogenic. Variants may include missense, nonsense, and splice site variants and small intragenic deletions/insertions; typically, exon or whole-gene deletions/duplications are not detected. For issues to consider in interpretation of sequence analysis results, click here.
4. Velho et al [2019]
5. Gene-targeted deletion/duplication analysis detects intragenic deletions or duplications. Methods used may include a range of techniques such as quantitative PCR, long-range PCR, multiplex ligation-dependent probe amplification (MLPA), and a gene-targeted microarray designed to detect single-exon deletions or duplications.
6. A 897-bp deletion spanning exon 19 [Coutinho et al 2012]

Clinical Characteristics

Clinical Description

Mucolipidosis II and mucolipidosis III α/β are distinct clinical disorders with different age of onset and clinical course. Although the experienced clinician observes variation within each phenotype, the phenotypic spectrum between ML II and ML IIIα/β is discontinuous. Knowledge of these two "classic" phenotypes allows recognition of an interesting minority of intermediate clinical types in which physical growth in infancy resembles that in the ML II whereas neuromotor and speech development follow the course of ML IIIα/β.

Mucolipidosis II

Mucolipidosis II (ML II) is slowly progressive with clinical onset at birth and death most often in early childhood [Cathey et al 2010]. The following is a summary of the phenotype by system.

Growth. Birth weight is low to borderline normal. Postnatal growth is limited and ceases during the second year of life. In the event that the diagnosis is not made early, the term "failure to thrive" is often applied. Measured length appears to "decrease" over time as hip and knee contractures worsen (Figure 1). Head size remains proportional to body size.

Craniofacial. The neonate with ML II has a flat face, depressed nasal bridge, and shallow orbits. The mouth is prominent. Coarsening of facial features is apparent from early infancy and gradually progresses (Figure 1). Impressive gingival hypertrophy is apparent soon after birth and causes dental eruption to appear incomplete.

The skin is thickened especially around the earlobes. Additional cutaneous findings include prominent periorbital tortuous veins and telangiectatic capillaries in the subcutis over the cheeks. Hair texture and color may be atypical for families of northern European origin as the hair texture is fine and, in some instances, white to golden in color, even in neonates.

Metopic prominence is observed in some children. Craniosynostosis is regularly suspected but not formally confirmed and, in some instances, has resulted in inappropriate cranial surgery.

Ophthalmologic. The epicanthal folds persist. If corneal haziness is present in the slightly proptotic eyes, it is mild and detectable only by slit lamp examination.

Audiologic. Episodes of otitis media occur frequently in nearly all children with ML II. Even when otitis media is treated promptly and adequately, conductive hearing loss is common; however, significant hearing impairment is rare. Sensorineural hearing loss is uncommon.

Respiratory. The voice is consistently hoarse.

Breathing remains noisy throughout life. The airways are narrow and subject to slowly progressive mucosal thickening and overall stiffening of the connective tissues. These factors also adversely affect the lung parenchyma. The gradual stiffening of the thoracic cage compounds the restrictive respiratory insufficiency.

Severe pulmonary hypertension (PH) has been more formally documented in a longer-surviving individual with ML II [Kovacevic et al 2011]. PH is probably the rule instead of the exception in individuals with ML II who survive into childhood. Excessive egress of lysosomal glycoproteins into the extracellular matrix is likely the main cause of adverse and progressive interstitial lung disease, although storage of glycoprotein may contribute. Poor general health in these individuals often precludes invasive diagnostic procedures. Ultimately, cardiorespiratory failure refractory to treatment is the cause of death in most affected children.

Respiratory support is only infrequently required in newborns. Obstructive sleep apnea necessitates nighttime respiratory support in some children; a minority of longer-surviving children require persistent assisted ventilation. In these cases, invariably, respiratory support was initiated during treatment of an acute infection.

Cardiovascular. Cardiac involvement likely occurs in all children. Thickening and insufficiency of the mitral valve and (less frequently) the aortic valve are the most common findings. Right side and general ventricular hypertrophy and pulmonary artery hypertension have been reported but rarely objectively documented [Kovacevic et al 2011]. Slowly progressive valvular changes are common, but valvular deficiency not consistently observed. Rapidly progressive cardiomyopathy is not a common feature in ML II.

Gastrointestinal/feeding. Children with ML II are usually poor eaters. Growth is minimal and ceases in the second year of life. Small size and paucity of physical movements (most never walk independently) contribute to the limited appetite. Although often a parental request following recommendation of dieticians, only a minority of children require gastrostomy tube feeding. The abdomen is protuberant, although hepatomegaly is equivocal and splenomegaly rarely observed. Inguinal hernias are slightly more common than in the average infant and occur equally in males and females. Umbilical hernias, a nearly constant finding, may gradually enlarge, but are not known to cause gastrointestinal complications and do not require surgical correction.

Skeletal/soft connective tissue. Orthopedic abnormalities, often noticed at birth, may include one or more of the following: thoracic deformity, kyphosis, clubfeet, deformed long bones, and/or dislocation of the hip(s).

The range of motion of all major and small joints is significantly limited. Mobility of the shoulders is significantly reduced despite consistent axial and appendicular hypotonia. The wrists gradually lose range of motion, the hands and fingers broaden gradually in the few years after infancy and become progressively stiffer and fixed in volar claw-like flexion and usually deviate from the appendicular axis.

Neuromotor development and intellect. Alertness is limited in some, but close to normal in most affected children. Children with ML II show affection, happiness, and displeasure as would any child [Cathey et al 2010].

Early motor milestones are significantly delayed: sitting upright with support is usually acquired around age one year; unassisted sitting may not be achieved until age two years. In the majority of affected children, unaided walking is never achieved. Onset of expressive language is late and limited to single words. Receptive communication, which is much better than expressive language, is not age appropriate. Cognitive functioning, although obviously below normal for age, enables the child to understand, interact with, and enjoy the immediate environment.

Mucolipidosis IIIα/β

ML IIIα/β is slowly progressive with clinical onset at approximately age three years and death in early-to-middle adulthood [Leroy 2007, Cathey et al 2010]. Comprehensive data on life expectancy are still lacking.

Growth. Weight and length at birth are within normal limits. Gradual slowing of growth rate begins in late infancy to early childhood. Concerns about small stature rarely arise before age three years, when worsening shoulder, hip, and knee contractures adversely affect stature. ML IIIα/β does not cause frank dwarfism as does ML II (Figure 2); however, stature from early childhood is often below the third centile on standard growth curves. Final stature is well below expected for an individual's average family stature.

Craniofacial. True macrocephaly does not occur. Dysmorphic facial features are absent or minimal in younger children. Coarsening of facial features is gradual and more apparent in profile, including full cheeks, depressed nasal bridge, and prominent mouth. Gingival hypertrophy is mild and does not usually interfere with tooth eruption (Figure 2).

Ophthalmologic. Epicanthal folds persist longer than normal. Proptosis, often observed in ML II, is rare. The corneas are clear by routine clinical inspection, but corneal clouding, which is visually insignificant, may be appreciated by slit-lamp examination.

Audiologic. Episodes of otitis media occur in individuals with ML IIIα/β more frequently than in the general population. Conductive hearing loss, documented in some affected individuals, has not been studied systematically. Sensorineural hearing loss is not a typical feature of ML III.

Respiratory. Mild hoarseness of the voice is an inconsistent finding. Upper-respiratory infections are more frequent than expected in some (but not all) children. From late childhood onward bronchitis and bronchopneumonia are the most consistent clinical complications.

Adults exhibit restrictive lung disease caused by stiffening of the thoracic cage, slowly progressive sclerosis of bronchi, and hardening and thickening of the interstitial tissue (extracellular matrix) in lung parenchyma.

Cardiovascular. Individuals with ML IIIα/β are at risk for cardiac involvement. Gradual thickening and subsequent insufficiency of the mitral valve and the aortic valve are common from late childhood onward [Steet et al 2005].

Left and/or right ventricular hypertrophy are often documented on echocardiography in older individuals. Pulmonary hypertension may occur in some older individuals, but to date remains insufficiently documented.

Rapid progression of cardiac disease is rarely observed in ML IIIα/β.

Pneumonia may compound mild cardiac insufficiency. Death in early adulthood is often from cardiopulmonary causes, even without complicating factors such as pneumonia.

Gastrointestinal. Prominence of the abdomen especially upon standing upright is caused in part by lumbar hyperlordosis, compensation for hip and knee flexion contractures, and hypotonia of the abdominal wall musculature. Diastasis of the medial recti and small umbilical hernias may also be present. In general, individuals with ML IIIα/β do not have organomegaly.

Skeletal / soft connective tissue. Stiffness of all large and small joints is a cardinal feature. Limited range of motion in the shoulders is frequently the initial evidence of ML IIIα/β and is mainly of soft tissue origin.

Limited range of motion in the hips and knees explains the slow gait and inability of children to run effectively. Flexion contractures in the hips and knees cause the squatting standing posture, most apparent in lateral view (Figure 2).

Secondary but severe arthritic changes in the hips that can lead to destruction of the proximal femoral epiphyses make walking increasingly difficult and painful. Significant hardening of the surrounding soft tissues contributes to hip dysfunction. Many affected individuals become wheelchair bound before or during early adulthood.

Range of motion is less adversely affected in the wrists and ankles than in the other large joints. Dupuytren-type palmar contractures may appear from late childhood onward and exacerbate the moderate to severe claw-like flexion deformity of the fingers associated with recurrent swelling and progressive stiffness (Figure 2). Neuropathic carpal tunnel signs can become severe in some individuals.

In ML IIIα/β the hands and fingers are usually of near-normal length in contrast to the severely affected hands in ML II.

Before the appropriate diagnosis is made, many individuals with ML IIIα/β are evaluated for a rheumatologic disorder.

Osteoporosis affects the entire skeleton. Bone pain becomes the most distressing symptom in ML IIIα/β, even in individuals with limited ambulation. Osteolytic bone lesions also are associated with significant bone pain in those who are nonambulatory.

Neuromotor development and intellect are the most variable features in ML IIIα/β ranging from normal to mild developmental delay in reaching motor milestones. Onset and development of receptive and expressive language skills occur at the expected age. Stuttering has not been observed in individuals with ML IIIα/β. Although psychometric tests often reveal an IQ within normal limits, approximately half of affected children require school assistance, often because of their physical limitations.

Other

- The neck is short.
- Thickening of the skin is inconsistent and mild.

Phenotypes Intermediate Between ML II and ML IIIα/β

While the majority of individuals with a *GNPTAB*-related disorder have one of the two distinct phenotypes (ML II or ML IIIα/β), some have intermediate phenotypes. In a large study, seven of 61 probands had an intermediate phenotype that was not phenotypically homogeneous [Cathey et al 2010]. Of note, three of the seven individuals in the study of Cathey et al [2010] and five individuals in a single family ascertained subsequently had a homogeneous intermediate phenotype that was directly correlated to compound heterozygosity for the *GNPTAB* c.10A>C (p.Lys4Gln) variant and a second, different pathogenic frameshift variant [Leroy et al 2014]. See Genotype-Phenotype Correlations.

Figure 2. Female age 19 years with ML IIIα/β

All affected individuals had normal anthropometric data when born at term following normal pregnancies. In some facial features were considered coarse and flat. Contractures of some large joints and mild dorsolumbar kyphoscoliosis were noticed in infancy. Growth slowed near the end of the second year. The diagnosis of ML II was made before the third birthday. However, in later childhood the diagnosis was changed to ML IIIα/β or still later to ML II / ML IIIα/β [David-Vizcarra et al 2010].

Physical growth ceased by the time that maximal height was below 90 cm coincident with radiographic evidence of dysostosis multiplex. Even when the skeletal dysplasia was consistent with ML II, neuromotor development slowly progressed. All children were able to walk unaided at about age three years. Speech development was close to normal in some, and consistently better than that observed in ML II. Cognitive development was slow and deficient resulting in mild intellectual disability. Near-normal social interaction was reminiscent of that observed in ML IIIα/β.

Average life expectancy in this particular intermediate phenotype was similar to that in ML IIIα/β. Respiratory problems were mild and infrequent; however, slowly progressive hardening and thickening of the cardiac valves causing valvular insufficiency and subsequent myocardial hypertrophy and failure was the most common cause of death. The postmortem findings in one individual (originally reported to have had the ML IIIα/β phenotype) were published [Kobayashi et al 2011].

Genotype-Phenotype Correlations

Genotype-phenotype correlations support the clinical distinction between the phenotypes ML II, ML IIIα/β, and at least the type of intermediate ML described in Phenotypes Intermediate Between ML II and ML IIIα/β.

ML II. Homozygous and compound heterozygous *GNPTAB* pathogenic variants that result in no functional GlcNAc-1-phosphotransferase (GNPT) activity (typically nonsense or frameshift variants) are consistently associated with the ML II phenotype. This severe phenotype is caused by complete loss of enzyme activity.

ML IIIα/β. *GNPTAB* variants in the homozygous or compound heterozygous state in which some retained GNPT enzyme activity (between and 1% and 10% of the normal activity) usually result in the ML IIIα/β phenotype [Paik et al 2005, Steet et al 2005, Tiede et al 2005, Bargal et al 2006, Kudo et al 2006, Otomo et al 2009, Tappino et al 2009, Cathey et al 2010, David-Vizcarra et al 2010]. Some missense and several splice site variants have been associated with ML IIIα/β. Compound heterozygosity for one loss-of-function variant and one reduced function variant are also associated with ML IIIα/β. Hence, a variant that retains some activity protects against the ML II phenotype.

Of note, intellectual disability in one individual with ML IIIα/β homozygous for c.342delCA, whose parents were consanguineous, was significantly below the near-normal range of intellect typically observed in ML IIIα/β; it is unclear to what degree homozygosity for other variants could have affected this aspect of the phenotype.

Intermediate ML. The distinct, consistent intermediate phenotype similar to ML II in physical and radiographic features and to ML IIIα/β in psychomotor development and life expectancy results from compound heterozygosity for the *GNPTAB* variant c.10A>C (p.Lys4Gln) and a frameshift variant. GNPT enzyme activity is 7%-12% of normal [Leroy et al 2014]. The p.Lys4Gln missense variant located in the N-terminal cytoplasmic tail of the αβ polypeptide impairs its retention in the Golgi complex, but retains in vitro catalytic activity that is nearly normal [van Meel et al 2014].

Other intermediate phenotypes are to date less well defined. Some homozygous variant genotypes appear to be well represented and clinically heterogeneous.

Nomenclature

The term "mucolipidosis" has been used in four different inborn errors of metabolism; only ML II, ML IIIα/β, and intermediate ML are *GNPTAB* related.

During the 1970s excessive urinary excretion of oligosaccharides was documented in most of the mucolipidoses; therefore, the terms "oligosaccharidoses" or "glycoproteinoses" may be substituted for the term "mucolipidoses."

Table 2. Terms Used to Describe GNPTAB-Related Disorders

Mucolipidosis II [1] (ML Iiα/β)		Intermediate ML	Mucolipidosis IIIα/β
I-cell disease, a laboratory term [2], has been largely replaced by the term mucolipidosis type II.	**Pacman dysplasia,** once thought to be a distinct perinatal lethal skeletal dysplasia, is now known to represent (in most reported cases) the prenatal manifestation of ML II. [3]	**Webb type ML** is a term proposed by Leroy et al [2014] to describe a distinct phenotype similar to ML II in physical & radiographic features & to ML IIIα/β in psychomotor development & life expectancy in individuals compound heterozygous for the p.Lys4Gln pathogenic variant & a frameshift variant.	**Pseudo-Hurler-polydystrophy (PHP)** was the term used by Maroteaux & Lamy when they first clinically & radiologically delineated the multisystem disorder that had only progressive stiffening of the large & small joints in common w/ MPS I (Hurler disease). [4]

MPS = mucopolysaccharidosis

1. ML II, introduced in 1970 by Spranger in an attempt to provide the first clinical classification of the group of metabolic disorders, clinically considered intermediate between the lipidoses and the mucopolysaccharidoses (storage disorders of glycosaminoglycans). Although mucolipidosis is a clinically useful designation, biochemists consider it a misnomer because "mucolipids" do not exist in nature.

2. The finding by Jules Leroy and Robert DeMars by phase-contrast microscopy of large amounts of dark and dense granules filling almost the entire cytoplasm of cultured fibroblasts from skin biopsies of two unrelated children resulted in the use of the term "inclusion cells," abbreviated as "I-cells." Hence, the term "I-cell disease" was introduced.

3. Saul et al [2005]

4. Maroteaux & Lamy [1966]

See Figure 3 for a microscopic view of I-cells.

Prevalence

ML II. The few estimates of the prevalence of ML II confirm that it is rare. Estimates include the following:

- **Portugal.** Approximately 1:123,500 live births [Pinto et al 2004]
- **Japan.** 1:252,500 [Okada et al 1985]
- **Netherlands.** 1:625,500 [Poorthuis et al 1999]
- **Ireland.** 1.56:100,000 live births in Republic of Ireland (ROI) and Northern Ireland; 114:100, 000 in the Irish Travellers community in ROI. The data suggest a carrier rate for the most common pathogenic variant of 1:512 in the former and of 1:15 in the latter population [McElligott et al 2011].

If these findings reflect a global prevalence ranging between 2.5×10^{-6} and 1.10^{-5}, the overall carrier rate ranges between 1:158 and 1:316.

ML II has been reported in nearly all parts of the world.

An unusually high prevalence of ML II in 1:6,184 live births with an estimated carrier rate of 1:39 was found in the northeastern region of the province of Quebec, Canada [Plante et al 2008]. In this region, ML II in several large pedigrees has been attributed to a founder effect as only one *GNPTAB* pathogenic variant (c.3503_3504delTC) has been detected in all obligate carriers. The variant was introduced into that part of Canada in the 17th century by immigrants from France and Scotland. It is the most common *GNPTAB* pathogenic variant worldwide.

ML IIIα/β. Estimates of the prevalence of ML IIIα/β based on objective data are not available. It is, however, likely that the prevalence is of the same order of magnitude as that of ML II and hence estimated to range between 2.5×10^{-6} and 1.10^{-5}. Consequently, the carrier rate is estimated at between 1:158 and 1:316.

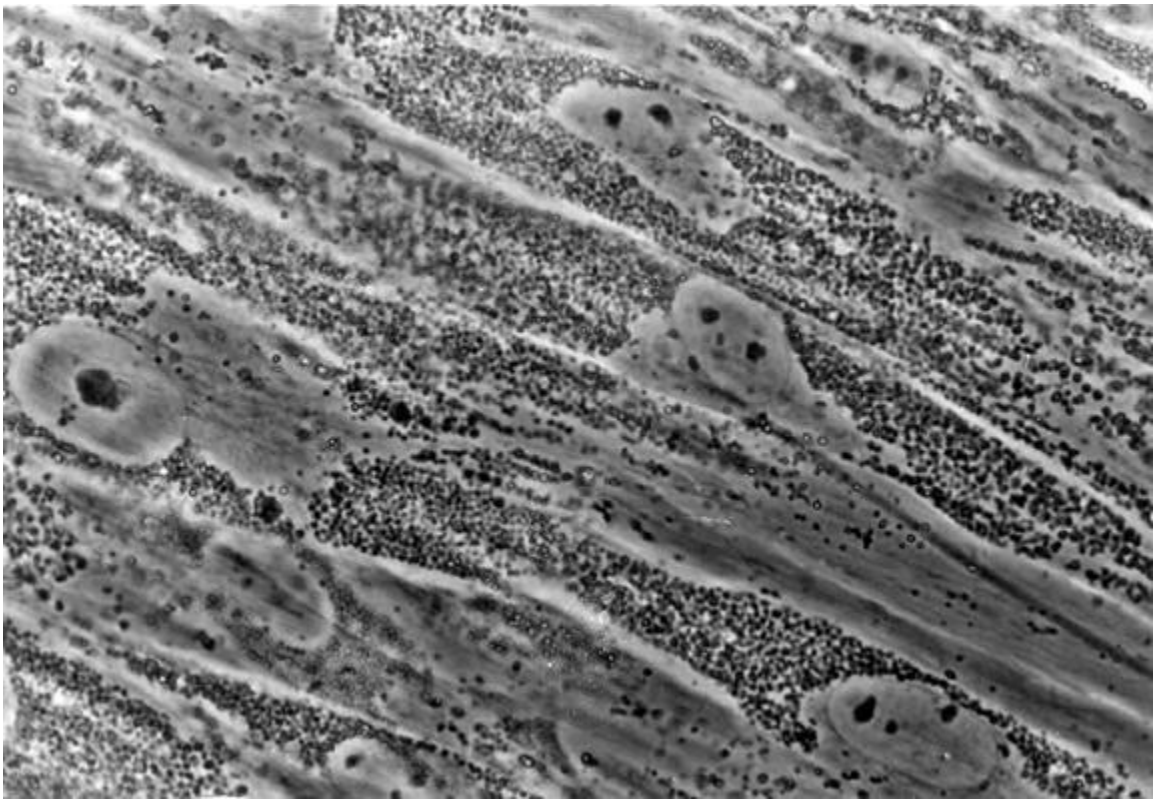

Figure 3. Phase-contrast microscopic view of "I-cells" in culture

Living culture of skin fibroblasts derived from a person with ML IIIα/β viewed by contrast light microscope. The cytoplasm is filled with dense granular inclusions that consistently spare a juxtanuclear zone that represents the endoplasmic reticulum and the Golgi apparatus. Electron microscopic study shows that the inclusions are swollen lysosomes bound by a unit membrane and filled with heterogeneous material of varying texture, shape, and electron density. The fibroblasts were originally called inclusion cells (I-cells) and the disorder associated with this in vitro phenotype "I-cell disease." No morphologic differences are observed between fibroblasts derived from an individual with ML II and an individual with ML IIIα/β.

The combined prevalence of ML II and ML IIIα/β is 0.22 per 100,000 in the Czech Republic [Poupetová et al 2010].

Genetically Related (Allelic) Disorders

No phenotypes other than those discussed in this chapter have been associated with biallelic *GNPTAB* pathogenic variants.

Differential Diagnosis

In addition to the disorders to consider in the differential diagnosis of *GNPTAB*-related disorders listed in Tables 3 and 4, the disorder ML IIIγ, caused by biallelic pathogenic variants in *GNPT* and closely resembling ML IIIα/β, needs to be considered.

Mucolipidosis II (ML II)

Table 3. Autosomal Recessive Lysosomal Storage Disorders to Consider in the Differential Diagnosis of ML II

Differential Diagnosis Disorder	Gene	Clinical Features of Differential Diagnosis Disorder	
		Overlapping w/ML II	Distinguishing from ML II
Severe mucopolysaccharidosis type I (MPS I; Hurler syndrome)	*IDUA*	• Coarse features • Slowed statural growth • Clawed hands	MPS I is more prevalent, has more signs of storage on physical exam, & has less severe dysostosis multiplex on radiographs.
Type I (infantile) GM1 gangliosidosis	*GLB1*	Radiographic features of dysostosis multiplex are indistinguishable in ML II (in early infancy & childhood) & GM1-gangliosidosis type 1 (in neonates). [1]	More hepatomegaly
Infantile galactosialidosis (OMIM 256540)	*CTSA*	• Growth restriction • Skeletal dysplasia	• Storage phenomena more pronounced • Presents as nonimmune hydrops fetalis more often than ML II
Infantile sialidosis (formerly called sialidosis type II or mucolipidosis I) (OMIM 256550)	*NEU1*	• Dysmorphic • Coarse features	• May present as nonimmune hydrops fetalis • In infants: more chronic disorder w/ moderate organomegaly, dysostosis multiplex that is milder than in ML II, [2] & minimal limitation of joint mobility • Growth & cognitive development much less impaired
Infantile free sialic acid storage disease	*SLC17A5*	• Coarse features • Significant DD	• Less facial dysmorphism & much less dysostosis multiplex • Severe DD

DD = developmental delay
1. Spranger et al [2002]
2. Barring the few instances with a rapidly evolving glomerular nephropathy & early fatal outcome

Mucolipidosis IIIα/β (ML IIIα/β)

Mucopolysaccharidosis 1 (see Table 4) and juvenile idiopathic arthritis are the top misdiagnoses for ML III α/β. ML III α/β and juvenile idiopathic arthritis are both characterized by joint pain and restricted range of motion; however, juvenile idiopathic arthritis is associated with a later onset of manifestations and lack of dysostosis multiplex. There are multiple types of juvenile idiopathic arthritis; the genetic etiology is unknown.

Mucopolysaccharidosis 1 and other disorders with a known genetic etiology are described in Table 4.

Table 4. Inherited Disorders to Consider in the Differential Diagnosis of ML IIIα/β

Disorder	Gene(s)	MOI	Clinical Features of Differential Diagnosis Disorder	
			Overlapping w/ML IIIα/β	Distinguishing from ML IIIα/β
ML III gamma (variant ML III)	*GNPTG*	AR	Clinical features of ML IIIγ are similar to but milder than those of ML IIIα/β.	Affected individuals are of Middle Eastern descent in most case reports.

Table 4. continued from previous page.

Disorder	Gene(s)	MOI	Clinical Features of Differential Diagnosis Disorder	
			Overlapping w/ML IIIα/β	Distinguishing from ML IIIα/β
Slowly progressive MPS I [1]	*IDUA*	AR	• Clinical findings in ML IIIα/β overlap those observed in nearly all late-onset mild MPSs • Share several clinical & radiographic aspects of dysostosis multiplex	• Evidence of more severe storage on physical exam • Enlarged head size in all MPSs (not seen in ML IIIα/β)
Slowly progressive MPS II [2]	*IDS*	XL		
MPS IVB [3] (See *GLB1*-Related Disorders.)	*GLB1*	AR		
MPS VI (OMIM 253200) [4]	*ARSB*	AR		
MPS VII [5]	*GUSB*	AR		
Alpha-mannosidosis	*MAN2B1*	AR	• Slowly coarsening features • Mild dysostosis	• Early hearing loss • More significant DD
Late infantile & juvenile galactosialidosis (OMIM 256540)	*CTSA*	AR	• Coarse facies • Vertebral abnormalities • Infantile form can present w/ nonimmune hydrops fetalis.	• Hepatosplenomegaly • Myoclonus & ataxia in juvenile form
Childhood dysmorphic sialidosis (ML I) (OMIM 256550)	*NEU1*	AR	• Coarse facies • Short trunk • Short stature	• Myoclonus • Seizures
Free sialic acid storage disorders (late infantile sialic acid storage disorder or Salla disease)	*SLC17A5*	AR	• DD • Coarse facies	• Much more prominent neurodegenerative aspects • Absent/minimal dysostosis multiplex
Multiple sulfatase deficiency (mucosulfatidosis)	*SUMF1*	AR	• DD • Restricted range of motion in joints • Dysostosis multiplex on skeletal radiographs	• Much more prominent neurodegenerative aspects
Osteoarthritis w/mild chondrodysplasia (OMIM 604864) [6]	*COL2A1*	AD	• Joint stiffness & bone pain • Limited joint mobility	• Later onset of symptoms • Absence of radiologic signs of dysostosis multiplex
Progressive pseudorheumatoid chondrodysplasia	*CCN6*	AR	Joint pain & stiffness	Absence of radiologic signs of dysostosis multiplex [7]
Multiple epiphyseal dysplasia (MED) (See MED, AR & MED, AD.)	*COL9A1* *COL9A2* *COL9A3* *COMP* *MATN3* *SLC26A2*	AR AD		

AD = autosomal dominant; AMPS = acid mucopolysaccharides; AR = autosomal recessive; DD = developmental delay; MOI = mode of inheritance; MPS = mucopolysaccharidosis; XL = X-linked

1. Formerly referred to as Hurler-Scheie syndrome or Scheie syndrome

2. Also referred to as Hunter syndrome

3. In the past, mucopolysaccharidosis type IVB was referred to as Morquio syndrome type B.

4. Also referred to as Maroteaux-Lamy syndrome

5. Also referred to as Sly syndrome

6. A late-manifesting type II collagenopathy

7. Spranger et al [2002]

Management

Evaluations Following Initial Diagnosis

To establish the extent of disease and needs of an individual diagnosed with a *GNPTAB*-related disorder, the evaluations for mucolipidosis II / mucolipidosis IIIα/β summarized in this section (if not performed as part of the evaluation that led to the diagnosis) are recommended.

Mucolipidosis II

- Radiographic skeletal survey, if not performed or incomplete in the diagnostic evaluation. Such survey in early infancy is important for comparison with similar radiographs in the third year of life.
- Cardiac evaluation with echocardiography to assess valve thickening and ventricular size and function
- Pulmonary radiographs to monitor interstitial lung disease in any serious lower respiratory infection. Chest CT may better show fibrotic changes in the lungs. It is doubtful that the child with ML II can cooperate sufficiently to achieve reliable pulmonary function tests, by which restrictive respiratory deficiency could be documented more objectively.
- Feeding problems concern parents as the affected child consumes fewer calories than expected. Poor suck, which may contribute to feeding difficulties early on, generally resolves quickly. Caloric need is less than that of an unaffected sib.
- Baseline ophthalmologic examination in a neonate with ML II is useful, but significant visual impairment is not a usual issue. An ophthalmologic evaluation between six and 12 months is recommended: Slit lamp examination will reveal corneal haziness, apparently without clinical implication; fundoscopic examination will show no specific retinal abnormalities.
- Hearing screen for conductive hearing loss secondary to recurrent otitis media. Hearing may be normal during the first year, but should be checked at least once after age six months. In the second year, some conductive hearing loss may be present, even without – but certainly following – upper airway infections.
- Developmental assessment to help establish appropriate expectations for the child's developmental progress
- Consultation with a clinical geneticist and/or genetic counselor

Mucolipidosis IIIα/β

- Radiographic skeletal survey if either not performed or incomplete in the diagnostic evaluation
- Baseline evaluations with an orthopedic surgeon and a metabolic bone specialist to better determine if/when surgical interventions or bisphosphonate therapy may be initiated (See Treatment of Manifestations.)
- Gentle physical and occupational therapy to maintain mobility and strength. Aggressive therapy can cause further joint damage.
- Cardiac evaluation with echocardiography to assess valve thickening and ventricular size and function
- Baseline ophthalmologic examination
- Hearing screen for evidence of conductive hearing loss secondary to recurrent otitis media
- Baseline developmental assessment
- Consultation with a clinical geneticist and/or genetic counselor

Treatment of Manifestations

Mucolipidosis II

Supportive and symptomatic management is indicated.

Joints. No measures are effective in treating the progressive limited range of motion in large and small joints. The classic physiotherapeutic early intervention programs that are often beneficial in children with developmental delay, neuromotor delay, or cerebral palsy cannot be recommended unequivocally in ML II because of the following:

- Stretching exercises are ineffective and painful.
- The unknowing therapist may cause damage to the surrounding joint capsule and adjacent tendons with subsequent soft tissue calcification.

Therapies that are "low impact" concerning joint and tendon strain, including short sessions of aqua therapy, are usually well tolerated. Instead of exercises of passive motion, often the child can be motivated to imitate active motion in joints despite the inherent limited range of motion.

Cognitive. Intellectual impairment to some degree is seen in all individuals with ML II. Affected children have impaired language skills, ranging from nonverbal to very limited vocabularies. Occupational therapy can be effective in any well-adapted program of cognitive stimulation such as interactive play that favors alertness, imitative skills, and ambition.

Dental. Severe gingival thickening can compromise routine dental cleaning. Mouth pain, infections, and even abscesses have been successfully treated with gingivectomy in some individuals.

Audiologic. Myringotomy tube placement for recurrent ear infections is common but should not be considered a routine procedure because of the unique airway issues (and hence anesthesia-related risk) and the narrow external auditory meatus.

Airway. Because of concerns about airway management, surgical intervention should be avoided as much as possible and undertaken only in tertiary care settings with pediatric anesthesiologists and intensive care. Children with ML II are small and have a small airway, reduced tracheal suppleness from stiff connective tissue, and progressive narrowing of the airway from mucosal thickening. The use of an endotracheal tube that is much smaller than that used for age- and size-matched children is necessary. Poor compliance of the thoracic cage and the progressively sclerotic lung parenchyma further complicate airway management. Extubation may also be challenging.

Mucolipidosis IIIα/β

Supportive and symptomatic management is indicated.

Skeletal. Therapies that are "low impact" in regard to joint and tendon strain, including short sessions of aqua therapy, are usually well tolerated.

Management of pain in the hips during and following walking requires attention from late childhood or early adolescence.

Carpal tunnel signs may require tendon release procedures for at least temporary relief. The procedure is repeated several time in some individuals.

Later in the disease course more general bone pain of variable intensity, unrelated to physical exercise or motion, is present.

Bisphosphonates decrease osteoclastic activity; when on therapy, some (but not all) individuals with ML IIIα/β experience decreased pain and associated increased mobility. Bone densitometry is improved in affected individuals and in animal models [Robinson et al 2002, Kollmann et al 2013]. Rare complications of bisphosphonate therapy include atypical femoral fractures and osteonecrosis of the jaw [Pispati et al 2018].

Bilateral hip replacement has been successful in older adolescents and adults with milder ML IIIα/β [Lewis & Gibson 2010].

Audiologic. Recurrent otitis media occurs more often in ML IIIα/β than in a control population; the prevalence decreases with age. Myringotomy tube placement may be considered necessary to prevent conductive hearing loss; however, it should not be considered a "routine" procedure given the unique airway issues and anesthesia risks of ML IIIα/β.

Airway. Because of concerns about airway management, surgical intervention should be avoided as much as possible and undertaken only in tertiary care settings with pediatric anesthesiologists and intensivists. Individuals with ML IIIα/β are smaller than their healthy peers and have a narrow airway, reduced tracheal suppleness from stiff connective tissue, and progressive narrowing of the airway from mucosal thickening. The use of a much smaller endotracheal tube than for age- and size-matched controls is necessary. Fiberoptic intubation must be available. Extubation may also be a challenge. Poor compliance of the thoracic cage and the progressively sclerotic lung parenchyma further complicate airway management, especially in older individuals.

Respiratory. Functional decline of lung parenchyma is likely due at least in part to slowly progressive degeneration of soft connective tissue in the extracellular matrix, a phenomenon insufficiently studied.

Cardiac. As subclinical cardiac failure may become overt during anesthesia, any surgical intervention should be preceded by a thorough cardiac evaluation.

Surveillance

Mucolipidosis II. Infants and toddlers with ML II and their families benefit from outpatient follow-up visits approximately every three months. Subsequently throughout early childhood, two outpatient visits per year may be adequate until cardiac and respiratory monitoring need to be more frequent.

Mucolipidosis IIIα/β. Young children with ML IIIα/β and their families benefit from outpatient clinic visits about twice a year. From age six years similar follow-up visits are recommended on a yearly basis unless bone pain and/or deteriorating ambulation become major handicaps and require closer orthopedic follow up and/or cardiac and respiratory monitoring need to be more frequent.

Evaluation of Relatives at Risk

See Genetic Counseling for issues related to testing of at-risk relatives for genetic counseling purposes.

Therapies Under Investigation

Search ClinicalTrials.gov in the US and EU Clinical Trials Register in Europe for access to information on clinical studies for a wide range of diseases and conditions. Note: There may not be clinical trials for this disorder.

Genetic Counseling

Genetic counseling is the process of providing individuals and families with information on the nature, mode(s) of inheritance, and implications of genetic disorders to help them make informed medical and personal decisions. The following section deals with genetic risk assessment and the use of family history and genetic testing to clarify genetic status for family members; it is not meant to address all personal, cultural, or ethical issues that may arise or to substitute for consultation with a genetics professional. —ED.

Mode of Inheritance

GNPTAB-related disorders are inherited in an autosomal recessive manner.

Risk to Family Members

Parents of a proband

- The parents of an affected child are obligate heterozygotes (i.e., carriers of one *GNPTAB* pathogenic variant).
- Heterozygotes (carriers) are asymptomatic and are not at risk of developing the disorder.

Sibs of a proband

- At conception, each sib of an affected individual has a 25% chance of being affected, a 50% chance of being an asymptomatic carrier, and a 25% chance of being unaffected and not a carrier.
- Heterozygotes (carriers) are asymptomatic and are not at risk of developing the disorder.

Offspring of a proband

- Individuals with ML II do not reproduce.
- Individuals with ML IIIα/β do not commonly reproduce but fertility is not known to be impaired.

Other family members. Each sib of the proband's parents is at a 50% risk of being a carrier of a *GNPTAB* pathogenic variant.

Carrier Detection

Carrier testing for at-risk relatives requires prior identification of the *GNPTAB* pathogenic variants in the family.

Related Genetic Counseling Issues

Family planning

- The optimal time for determination of genetic risk, clarification of carrier status, and discussion of the availability of prenatal/preimplantation genetic testing is before pregnancy.
- It is appropriate to offer genetic counseling (including discussion of potential risks to offspring and reproductive options) to young adults who are carriers or are at risk of being carriers.

Prenatal Testing and Preimplantation Genetic Testing

Once the *GNPTAB* pathogenic variants have been identified in an affected family member, prenatal and preimplantation genetic testing are possible.

Differences in perspective may exist among medical professionals and within families regarding the use of prenatal testing. While most centers would consider use of prenatal testing to be a personal decision, discussion of these issues may be helpful.

Resources

GeneReviews staff has selected the following disease-specific and/or umbrella support organizations and/or registries for the benefit of individuals with this disorder and their families. GeneReviews is not responsible for the information provided by other organizations. For information on selection criteria, click here.

No specific resources for *GNPTAB*-Related Disorders have been identified by *GeneReviews* staff.

Molecular Genetics

Information in the Molecular Genetics and OMIM tables may differ from that elsewhere in the GeneReview: tables may contain more recent information. —ED.

Table A. GNPTAB-Related Disorders: Genes and Databases

Gene	Chromosome Locus	Protein	Locus-Specific Databases	HGMD	ClinVar
GNPTAB	12q23.2	N-acetylglucosamine-1-phosphotransferase subunits alpha/beta	GNPTAB database	GNPTAB	GNPTAB

Data are compiled from the following standard references: gene from HGNC; chromosome locus from OMIM; protein from UniProt. For a description of databases (Locus Specific, HGMD, ClinVar) to which links are provided, click here.

Table B. OMIM Entries for GNPTAB-Related Disorders (View All in OMIM)

252500	MUCOLIPIDOSIS II ALPHA/BETA
252600	MUCOLIPIDOSIS III ALPHA/BETA
607840	N-ACETYLGLUCOSAMINE-1-PHOSPHOTRANSFERASE, ALPHA/BETA SUBUNITS; GNPTAB

Molecular Pathogenesis

GNPTAB-related disorders are autosomal recessive lysosomal storage disorders. The partial inactivation of N-acetylglucosamine-1-phosphotransferase subunits alpha/beta may result from pathogenic variants that allow reduced or residual functional enzyme production (missense or some of the splice site variants). Defective N-acetylglucosamine-1-phosphotransferase results in missorting of lysosomal enzymes and accumulation of nondegradable macromolecules in lysosomes, strongly impairing cellular function.

Click here (pdf) for information on the scientific history of *GNPTAB*-related disorders, including some of the more important progress made in the last few years.

Mechanism of disease causation. *GNPTAB* encodes the alpha and beta subunits of the oligomeric human GNPTAB in a single 6.2-kb alpha/beta transcript. N-acetylglucosamine-1-phosphotransferase subunits alpha and beta comprise the amine and carboxyl ends, respectively, of the native protein. Inactivity or deficiency of this enzyme causes ML II or ML III alpha/beta, respectively.

Table 5. Notable *GNPTAB* Pathogenic Variants

Reference Sequences	DNA Nucleotide Change	Predicted Protein Change	Comment [Reference]
NM_024312.4 NP_077288.2	c.10A>C	p.Lys4Gln	See Genotype/Phenotype Correlations [Leroy et al 2014].
	c.3503_3504del	p.Leu1168GlnfsTer5	Most prevalent pathogenic variant worldwide (See Prevalence.) [Velho et al 2019]
	c.3565C>T	p. Arg1189Ter	2nd most prevalent pathogenic variant [Velho et al 2019]

Variants listed in the table have been provided by the authors. *GeneReviews* staff have not independently verified the classification of variants.
GeneReviews follows the standard naming conventions of the Human Genome Variation Society (varnomen.hgvs.org). See Quick Reference for an explanation of nomenclature.

Chapter Notes

Revision History

- 29 August 2019 (bp) Comprehensive update posted live; this update combines *GNPTAB*-related disorders ML II and ML IIIα/β.
- 10 May 2012 (me) Comprehensive update posted live
- 26 August 2008 (cg) Review posted live
- 16 June 2008 (jgl) Original submission

References

Literature Cited

Bargal R, Zeigler M, Abu-Libdeh B, Zuri V, Mandel H, Ben Neriah Z, Stewart F, Elcioglu N, Hindi T, Le Merrer M, Bach G, Raas-Rothschild A. When mucolipidosis III meets mucolipidosis II: GNPTA gene mutations in 24 patients. Mol Genet Metab. 2006;88:359–63. PubMed PMID: 16630736.

Cathey SS, Leroy JG, Wood T, Eaves K, Simensen RJ, Kudo M, Stevenson RE, Friez MJ. Phenotype and genotype in mucolipidoses II and III alpha/beta: a study of 61 probands. J Med Genet. 2010;47:38–48. PubMed PMID: 19617216.

Coutinho MF, da Silva Santos L, Lacerda L, Quental S, Wibrand F, Lund AM, Johansen KB, Prata MJ, Alves S. Alu-Alu recombination underlying the first large genomic deletion in GlcNAc-phosphotransferase Alpha/Beta (GNPTAB) gene in a MLII Alpha/Beta patient. JIMD Rep. 2012;4:117–24. PubMed PMID: 23430906.

David-Vizcarra G, Briody J, Ault J, Fietz M, Fletcher J, Savarirayan R, Wilson M, McGill J, Edwards M, Munns C, Alcausin M, Cathey S, Sillence D. The natural history and osteodystrophy of mucolipidosis types II and III. J Paediatr Child Health. 2010;46:316–22. PubMed PMID: 20367762.

Ellsworth KA, Pollard LM, Cathey S, Wood T. Measurement of elevated concentrations of urine keratan sulfate by UPLC-MSMS in lysosomal storage disorders (LSDs): comparison of urine keratan sulfate levels in MPS IVA versus other LSDs. JIMD Rep. 2017;34:11–18. PubMed PMID: 27469132.

Kobayashi H, Takahashi-Fujigasaki J, Fukuda T, Sakurai K, Shimada Y, Nomura K, Ariga M, Ohashi T, Eto Y, Otomo T, Sakai N, Ida H. Pathology of the first autopsy case diagnosed as mucolipidosis type III α/β suggesting autophagic dysfunction. Mol Genet Metab. 2011;102:170–5. PubMed PMID: 21051253.

Kollmann K, Pestka JM, Kühn SC, Schöne E, Schweizer M, Karkmann K, Otomo T, Catala-Lehnen P, Failla AV, Marshall RP, Krause M, Santer R, Amling M, Braulke T, Schinke T. Decreased bone formation and increased osteoclastogenesis cause bone loss in mucolipidosis II. EMBO Mol Med. 2013;5:1871–86. PubMed PMID: 24127423.

Kovacevic A, Schranz D, Meissner T, Pillekamp F, Schmidt KG. Mucolipidosis II complicated by severe pulmonary hypertension. Mol Genet Metab. 2011;104:192–3. PubMed PMID: 21802970.

Kudo M, Brem MS, Canfield WM. Mucolipidosis II (I-cell disease) and mucolipidosis III (classical pseudo-Hurler polydystrophy) are caused by mutations in the GlcNAc-phosphotransferase alpha- / beta-subunits precursor gene. Am J Hum Genet. 2006;78:451–63. PubMed PMID: 16465621.

Leroy JG. Oligosaccharidoses, disorders allied to the oligosaccharides. In: Rimoin DL, Connor JM, Pyeritz RE, Korf BR, eds. Emery and Rimoin's Principles and Practice of Medical Genetics. 5 ed. Philadelphia, PA: Churchill Livingstone; 2007:2413-48.

Leroy JG, Sillence D, Wood T, Barnes J, Lebel RR, Friez MJ, Stevenson RE, Steet R, Cathey SS. A novel intermediate mucolipidosis II/IIIαβ caused by GNPTAB mutation in the cytosolic N-terminal domain. Eur J Hum Genet. 2014;22:594–601. PubMed PMID: 24045841.

Lewis JR, Gibson PH. Bilateral hip replacement in three patients with lysosomal storage disease: Mucopolysaccharidosis type IV and Mucolipidosis type III. J Bone Joint Surg Br. 2010;92:289–92. PubMed PMID: 20130326.

Maroteaux P, Lamy M. Hurler's pseudo-polydystrophy. Presse Med. 1966;74:2889–92. PubMed PMID: 4958870.

McElligott F, Beatty E, O'Sullivan S, Hughes J, Lambert D, Cooper A, Crushell E. Incidence of I-cell disease (mucolipidosis type II) in the irish population. J Inherit Metab Dis. 2011;34:S206.

Okada S, Owada M, Sakiyama T, Yutaka T, Ogawa M. I-cell disease: clinical studies of 21 Japanese cases. Clin Genet. 1985;28:207–15. PubMed PMID: 2998652.

Otomo T, Muramatsu T, Yorifuji T, Okuyama T, Nakabayashi H, Fukao T, Ohura T, Yoshino M, Tanaka A, Okamoto N, Inui K, Ozono K, Sakai N. Mucolipidosis II and III alpha/beta: mutation analysis of 40 Japanese patients showed genotype-phenotype correlation. J Hum Genet. 2009;54:145–51. PubMed PMID: 19197337.

Paik KH, Song SM, Ki CS, Yu HW, Kim JS, Min KH, Chang SH, Yoo EJ, Lee IJ, Kwan EK, Han SJ, Jin DK. Identification of mutations in the GNPTA (MFGC4170) gene coding for GlcNAc-phosphotransferase alpha/beta subunits in Korean patients with mucolipidosis type II and type IIIA. Hum Mutat. 2005;26:308–14. PubMed PMID: 16116615.

Pinto R, Caseiro C, Lemos M, Lopes L, Fontes A, Ribeiro H, Pinto E, Silva E, Rocha S, Marcão A, Ribeiro I, Lacerda L, Ribeiro G, Amaral O, Sá Miranda MC. Prevalence of lysosomal storage diseases in Portugal. Eur J Hum Genet. 2004;12:87–92. PubMed PMID: 14685153.

Pispati A, Pandey V, Patel R. Oral bisphosphonate-induced recurrent osteonecrosis of jaw with atypical femoral fracture and subsequent mandible fracture in the same patient: A Case Report. J Orthop Case Rep. 2018;8:85–8. PubMed PMID: 30584526.

Plante M, Claveau S, Lepage P, Lavoie E-M, Brunet S, Roquis D, Morin C, Vezina H, Laprise C. Mucolipidosis II: a single causal mutation in the N-acetylglucosamins-1-phosphotransferase gene (GNBPTAB) in a French Canadian founder population. Clin Genet. 2008;73:236–44. PubMed PMID: 18190596.

Poorthuis BJHM, Wevers R, Kleijer WJ, Groener JEM, de Jong JGN, van Weely S, Niezen-Koning KE, Van Diggelen OP. The frequency of lysosomal diseases in The Netherlands. Hum Genet. 1999;105:151–6. PubMed PMID: 10480370.

Poupetová H, Ledvinová J, Berná L, Dvoráková L, Kozich V, Elleder M. The birth prevalence of lysosomal storage disorders in the Czech Republic: comparison with data in different populations. J Inherit Metab Dis. 2010;33:387–96. PubMed PMID: 20490927.

Richards S, Aziz N, Bale S, Bick D, Das S, Gastier-Foster J, Grody WW, Hegde M, Lyon E, Spector E, Voelkerding K, Rehm HL, et al. Standards and guidelines for the interpretation of sequence variants: a joint consensus recommendation of the American College of Medical Genetics and Genomics and the Association for Molecular Pathology. Genet Med. 2015;17:405–24. PubMed PMID: 25741868.

Robinson C, Baker N, Noble J, King A, David G, Sillence D, Hofman P, Cundy T. The osteodystrophy of mucolipidosis type III and the effects of intravenous pamidronate treatment. J Inherit Metab Dis. 2002;25:681–93. PubMed PMID: 12705498.

Saul RA, Proud V, Taylor HA, Leroy JG, Spranger J. Prenatal mucolipidosis type II (I-cell disease) can present as Pacman dysplasia. Am J Med Genet A. 2005;135:328–32. PubMed PMID: 15887289.

Spranger JW, Brill PW, Poznanski A. Mucolipidosis III. In: Bone Dysplasias: Atlas of Genetic Disorders of Skeletal Development. 2 ed. New York, NY: Oxford University Press; 2002:295-9.

Steet RA, Hullin R, Kudo M, Martinelli M, Bosshard NU, Schaffner T, Kornfeld S, Steinmann B. A splicing mutation in the alpha/beta GlcNAc-1-phosphotransferase gene results in an adult onset form of mucolipidosis III associated with sensory neuropathy and cardiomyopathy. Am J Med Genet A. 2005;132A:369–75. PubMed PMID: 15633164.

Tappino B, Chuzhanova NA, Regis S, Dardis A, Corsolini F, Stroppiano M, Tonoli E, Beccari T, Rosano C, Mucha J, Blanco M, Szlago M, Di Rocco M, Cooper DN, Filocamo M. Molecular characterization of 22 novel UDP-N-acetylglucosamine-1-phosphate transferase alpha- and beta-subunit (GNPTAB) gene mutations causing mucolipidosis types IIalpha/beta and IIIalpha/beta in 46 patients. Hum Mutat. 2009;30:E956–73. PubMed PMID: 19634183.

Tiede S, Muschol N, Reutter G, Cantz M, Ullrich K, Braulke T. Missense mutations in N-acetylglucosamine-1-phosphotransferase alpha/beta subunit gene in a patient with mucolipidosis III and a mild clinical phenotype. Am J Med Genet A. 2005;137A:235–40. PubMed PMID: 16094673.

van Meel E, Qian Y, Kornfeld SA. Mislocalization of phosphotransferase as a cause of mucolipidosis III αβ. Proc Natl Acad Sci U S A. 2014;111:3532–7. PubMed PMID: 24550498.

Velho RV, Harms FL, Danyukova T, Ludwig NF, Friez MJ, Cathey SS, Filocamo M, Tappino B, Güneş N, Tüysüz B, Tylee KL, Brammeier KL, Heptinstall L, Oussoren E, van der Ploeg AT, Petersen C, Alves S, Saavedra GD, Schwartz IV, Muschol N, Kutsche K, Pohl S. The lysosomal storage disorders mucolipidosis type II, type III alpha/beta and type III gamma: update on GNPTAB and GNPTG mutations. Hum Mutat. 2019;40:842–64. PubMed PMID: 30882951.

License

GeneReviews® chapters are owned by the University of Washington. Permission is hereby granted to reproduce, distribute, and translate copies of content materials for noncommercial research purposes only, provided that (i) credit for source (http://www.genereviews.org/) and copyright (© 1993-2024 University of Washington) are included with each copy; (ii) a link to the original material is provided whenever the material is published elsewhere on the Web; and (iii) reproducers, distributors, and/or translators comply with the GeneReviews® Copyright Notice and Usage Disclaimer. No further modifications are allowed. For clarity, excerpts of GeneReviews chapters for use in lab reports and clinic notes are a permitted use.

For more information, see the GeneReviews® Copyright Notice and Usage Disclaimer.

For questions regarding permissions or whether a specified use is allowed, contact: admasst@uw.edu.