U.S. National Library of Medicine
National Center for Biotechnology Information

NLM Citation: Kalfa TA, Begtrup AH. *EPB42*-Related Hereditary Spherocytosis. 2014 Mar 13 [Updated 2022 Apr 7]. In: Adam MP, Feldman J, Mirzaa GM, et al., editors. GeneReviews® [Internet]. Seattle (WA): University of Washington, Seattle; 1993-2024.
Bookshelf URL: https://www.ncbi.nlm.nih.gov/books/

EPB42-Related Hereditary Spherocytosis

Theodosia A Kalfa, MD, PhD[1] and Amber H Begtrup, PhD, FACMG[2]

Created: March 13, 2014; Updated: April 7, 2022.

Summary

Clinical characteristics

EPB42-related hereditary spherocytosis (EPB42-HS) is a chronic nonimmune hemolytic anemia that is usually of mild-to-moderate severity. EPB42-HS can present with jaundice as early as the first 24 hours of life or can present later in childhood with anemia resulting from a hemolytic crisis or aplastic crisis (usually associated with a viral infection). In addition to the hematologic manifestations, serious complications include splenomegaly, which can become evident in early childhood, and cholelithiasis, which usually becomes evident in the second or third decade of life.

Typical laboratory findings in EPB42-HS include anemia (decreased hemoglobin [Hgb] level) and reticulocytosis (increased percentage of reticulocytes), with high mean corpuscular Hgb concentration, presence of spherocytes in the peripheral blood smear, significantly decreased or absent haptoglobin, mildly increased osmotic fragility in osmotic fragility assay, increased O_{min} (osmolality at which 50% of red blood cells hemolyze), and decreased maximal elongation index (EI_{max}) in osmotic gradient ektacytometry.

Diagnosis/testing

The diagnosis of EPB42-HS is established by identification of biallelic pathogenic variants in *EPB42*.

Management

Treatment of manifestations: Treatment of hyperbilirubinemia as needed; folic acid supplementation; red blood cell transfusion as needed for a hemolytic or aplastic crisis; routine immunizations; iron chelation therapy as needed. Prior to splenectomy, immunizations for *S pneumoniae*, *N meningitidis*, *and H influenzae*. Although splenectomy is rarely indicated in EPB42-HS because disease severity is usually mild or moderate, partial or total splenectomy may be recommended in those with moderately severe EPB42-HS who are older than age five years when quality of life is compromised. Following splenectomy, booster immunizations for *S pneumoniae* and *N meningitidis*, prophylactic antibiotics, and prompt antibiotics for fever are recommended. Cholecystectomy in

Author Affiliations: 1 Cancer and Blood Diseases Institute Division of Hematology Cincinnati Children's Hospital Medical Center and University of Cincinnati Medical School Cincinnati, Ohio; Email: theodosia.kalfa@cchmc.org. 2 GeneDx, Inc Gaithersburg, Maryland; Email: abegtrup@genedx.com.

Copyright © 1993-2024, University of Washington, Seattle. GeneReviews is a registered trademark of the University of Washington, Seattle. All rights reserved.

those with signs and/or symptoms of cholelithiasis; affected individuals with a history of cholelithiasis should have cholecystectomy at the time of splenectomy.

Surveillance: Monitor serum bilirubin concentration in neonates during the first week of life and Hgb in infants during the first two to four months of life. Those dependent on frequent transfusions and those receiving iron chelation therapy require monitoring of serum ferritin concentration. Monitor efficacy of chelation via T_2*-weighted liver MRI and adjust appropriately. Abdominal ultrasound examination to evaluate for cholelithiasis either when symptoms are present or, when hemolysis is significant, every five to ten years beginning at age ten to 12 years.

Agents/circumstances to avoid: Avoid supplements containing iron unless iron studies have documented iron deficiency. If so, treatment with supplemental iron must be closely monitored and then discontinued when iron stores have been repleted. Avoidance of contact sports is recommended in those with splenomegaly; of note, acute or excessive splenomegaly is a greater risk than chronic mild splenomegaly.

Evaluation of relatives at risk: When EPB42-HS has been diagnosed in a family member, the following is recommended for at-risk sibs: (1) Neonates at risk require monitoring of serum bilirubin concentration during the first week of life so that treatment for hyperbilirubinemia can be instituted promptly; (2) Infants at risk require monitoring in the first two to four months of life for significant anemia, which may require red blood cell transfusion and initiation of folic acid supplementation. Laboratory evaluation (CBC and reticulocyte count, blood smear, osmotic fragility or ektacytometry) and/or molecular genetic testing for the *EPB42* pathogenic variants in the family (if known) is appropriate for at-risk relatives.

Pregnancy management: Folic acid supplementation (800-1,000 µg daily); monitor for exacerbation of anemia with CBC and reticulocyte count.

Genetic counseling

EPB42-HS is inherited in an autosomal recessive manner. If both parents are known to be heterozygous for an *EPB42* pathogenic variant, each sib of an affected individual has at conception a 25% chance of being affected, a 50% chance of being an asymptomatic carrier, and a 25% chance of inheriting neither of the familial *EPB42* pathogenic variants. Once the *EPB42* pathogenic variants have been identified in an affected family member, carrier testing for at-risk relatives, prenatal testing for a pregnancy at increased risk, and preimplantation genetic testing are possible.

Diagnosis

Suggestive Findings

EPB42-related hereditary spherocytosis (EPB42-HS) **should be suspected** in individuals with any of the following clinical and laboratory findings.

Clinical findings

- Pallor and/or fatigue due to anemia, which is usually of mild-to-moderate severity
- Jaundice
  - Usually intermittent and caused by unconjugated hyperbilirubinemia resulting from exacerbated hemolysis
  - In rare instances, caused by conjugated hyperbilirubinemia resulting from biliary obstruction
- Splenomegaly
- Cholelithiasis in the second or third decade of life

Laboratory findings

- **Complete blood count** consistent with:
  - Chronic, nonimmune hemolytic anemia (decreased hemoglobin [Hgb] with reticulocytosis), usually of mild-to-moderate severity
    - Decreased Hgb level (See Table 1 for Hgb levels that define the severity of hereditary spherocytosis.)

      Note: Hgb values in EPB42-HS may also vary depending on the clinical status of the affected individual (baseline or during a hemolytic or aplastic crisis).
    - Increased percent of reticulocytes as well as increased absolute reticulocyte count (See Table 1 for percent of reticulocytes that define the severity of hereditary spherocytosis.)

      Note: Percent of reticulocytes may vary (depending on baseline or crisis status) from 2.5% to greater than 10% (or even normal or low when in aplastic crisis).
  - High mean corpuscular Hgb concentration. Normal values are typically 31-37 g/dL. Values in individuals with hereditary spherocytosis are usually 35.5-37.5 g/dL.
- **Negative (i.e., normal) direct anti-globulin test (DAT)**

  Note: DAT should always be evaluated in a person with newly diagnosed hemolytic anemia to evaluate for an acute immune-mediated (acquired) hemolytic anemia.
- **Peripheral blood smear** demonstrating presence of spherocytes and occasionally a few ovalocytes and elliptocytes

  Note: The term "spherocyte" refers to the sphere-shaped red blood cells (with a decreased surface-to-volume ratio) that characterize the red blood cell membrane skeleton disorders (see Differential Diagnosis).
- **Significantly decreased or absent haptoglobin.** After age six months normal haptoglobin values are 16-200 mg/dL. In hereditary spherocytosis, haptoglobin is typically undetectable; however, haptoglobin can be normal in the presence of concurrent inflammation (as it is an acute phase reactant).
- **Mildly increased osmotic fragility** (as in Figure 1B of Hammill et al [2011]; see full text)
- **Decreased maximal deformability index** (**DI_{max}**; also known as **elongation index**, or **EI_{max}**) and **increased O_{min}** (osmolality at which 50% of red blood cells hemolyze) measured by osmotic gradient ektacytometry, giving a typical hereditary spherocytosis curve [Clark et al 1983, Hammill et al 2011]

Family history is consistent with autosomal recessive inheritance (e.g., affected sibs and/or parental consanguinity). Absence of a known family history does not preclude the diagnosis.

Table 1. Severity of Hereditary Spherocytosis

Severity	Hgb (g/dL)	Reticulocytes	Splenectomy
Mild	11-15	3%-8%	Not necessary
Moderate	8-11.5	>8%	Consider if ↓ activity level & quality of life
Moderately severe	6-8	≥10%	Indicated at age >5 yrs
Severe	<6	≥10%	Indicated at age >3 yrs

Table 1. continued from previous page.

Severity	Hgb (g/dL)	Reticulocytes	Splenectomy
Normal [1]	11.7-15.7 (adult females) 13.3-17.7 (adult males)	0.5%-1.5% [2]	

Hgb = hemoglobin
Based on table by Eber & Lux [2004]
1. Normal values may vary somewhat depending on age and sex.
2. Absolute reticulocyte count = 45-90 x 10^3/μL

Establishing the Diagnosis

The diagnosis of EPB42-HS **is established** in a proband by the identification of biallelic pathogenic variants in *EPB42* (see Table 2).

Molecular genetic testing approaches can include **single-gene testing** or use of a **multigene panel**:

- **Single-gene testing.** Sequence analysis of *EPB42* to detect small intragenic deletions/insertions and missense, nonsense, and splice site variants. To date, exon-level deletions/duplications have not been identified in individuals with EPB42-HS.
- **A multigene panel** that includes *EPB42* and other genes of interest (see Differential Diagnosis) may also be considered. Note: (1) The genes included in the panel and the diagnostic sensitivity of the testing used for each gene vary by laboratory and are likely to change over time. (2) Some multigene panels may include genes not associated with the condition discussed in this *GeneReview*; thus, clinicians need to determine which multigene panel is most likely to identify the genetic cause of the condition while limiting identification of variants of uncertain significance and pathogenic variants in genes that do not explain the underlying phenotype. (3) In some laboratories, panel options may include a custom laboratory-designed panel and/or custom phenotype-focused exome analysis that includes genes specified by the clinician. (4) Methods used in a panel may include sequence analysis, deletion/duplication analysis, and/or other non-sequencing-based tests.

  For an introduction to multigene panels click here. More detailed information for clinicians ordering genetic tests can be found here.

Table 2. Molecular Genetic Testing Used in *EPB42*-Related Hereditary Spherocytosis

Gene [1]	Method	Proportion of Pathogenic Variants [2] Detectable by Method
EPB42	Sequence analysis [3]	100% [4]
	Gene-targeted deletion/duplication analysis [5]	See footnote 6.

1. See Table A. Genes and Databases for chromosome locus and protein.
2. See Molecular Genetics for information on variants detected in this gene.
3. Sequence analysis detects variants that are benign, likely benign, of uncertain significance, likely pathogenic, or pathogenic. Variants may include small intragenic deletions/insertions and missense, nonsense, and splice site variants; typically, exon or whole-gene deletions/duplications are not detected. For issues to consider in interpretation of sequence analysis results, click here.
4. Kanzaki et al [1997], Toye et al [2008], and data derived from the subscription-based professional view of Human Gene Mutation Database [Stenson et al 2020]
5. Gene-targeted deletion/duplication analysis detects intragenic deletions or duplications. Methods used may include a range of techniques such as quantitative PCR, long-range PCR, multiplex ligation-dependent probe amplification (MLPA), and a gene-targeted microarray designed to detect single-exon deletions or duplications.
6. The only gross deletion reported to date is a deletion of 32 base pairs [Hammill et al 2011] that is expected to be detectable by sequence analysis.

Clinical Characteristics

Clinical Description

Children with *EPB42*-related hereditary spherocytosis (EPB42-HS) frequently present within the first 24 hours of life with jaundice that requires treatment with phototherapy or, rarely, exchange transfusion to prevent kernicterus. They may also present later in childhood with anemia resulting from a hemolytic crisis or aplastic crisis usually associated with a viral infection.

Toddlers with hereditary spherocytosis are occasionally found to have age-related iron deficiency anemia; however, the anemia fails to completely resolve with iron supplementation and reticulocytosis persists [Hammill et al 2011].

As with all forms of mild or moderate hereditary spherocytosis (see Table 1 for definitions), EPB42-HS can be more severe in the first four to six months of life, requiring regular red blood cell transfusions. Thus, frequent transfusions during the first few months of life do not necessarily correlate with disease severity later on.

EPB42-HS, if not recognized during infancy or early childhood, may be diagnosed later in life as a mild (hemoglobin [Hgb] = 11-15 g/dL) to moderate (Hgb = 8-11.5 g/dL) chronic hemolytic anemia (see Table 1), with jaundice, splenomegaly, and cholelithiasis at a relatively young age [Eber & Lux 2004].

Genotype-Phenotype Correlations

Homozygosity for p.Ala142Thr has been found most commonly in individuals of Japanese descent and was reported to lead to moderately severe hereditary spherocytosis, with Hgb as low as 6.1 g/dL [Bouhassira et al 1992]. An Italian individual with the same genotype was reported with moderate hemolytic anemia from birth and splenomegaly [Perrotta et al 1999].

Homozygosity for p.Ala142Thr or homozygosity for p.Asp175Tyr results in atypical hereditary spherocytosis with the presence of ovalostomatocytes in addition to few spherocytes in the blood smear. Hemolysis may be mild to moderately severe and improves after splenectomy [Bouhassira et al 1992, Kanzaki et al 1995].

Compound heterozygosity for p.Ala142Thr with another *EPB42* pathogenic variant causes typical hereditary spherocytosis with microspherocytes in the blood smear and increased osmotic fragility [Takaoka et al 1994, Kanzaki et al 1995]. Case reports of individuals with other *EPB42* pathogenic variants also indicate mild-to-moderate hereditary spherocytosis with only occasional need for blood transfusion [Hayette et al 1995, van den Akker et al 2010, Hammill et al 2011].

One individual homozygous for the null c.950delG variant (resulting in premature termination of the transcript and lack of production of any viable erythrocyte membrane protein 4.2) developed a strong antibody response against protein 4.2 after multiple red blood cell transfusions for gastrointestinal bleeding, causing alloimmune hemolytic anemia [Beauchamp-Nicoud et al 2000]. To date, antibody development has not been described following red blood cell transfusion in persons with other *EPB42* pathogenic variants, although in most individuals with EPB42-HS no protein 4.2 is detectable in the RBC membrane [Satchwell et al 2009].

Prevalence

Hereditary spherocytosis is the most common inherited anemia in individuals of northern European ancestry and is present worldwide, with a prevalence of 1:1,000-1:2,500 [Risinger & Kalfa 2020].

EPB42-HS is responsible for 40%-50% of hereditary spherocytosis in Japan, where the carrier frequency of p.Ala142Thr among healthy persons is as high as 3% [Yawata 1994, Yawata et al 2000].

In other populations, EPB42-HS accounts for 5% or less of hereditary spherocytosis [Eber & Lux 2004, Perrotta et al 2008].

Genetically Related (Allelic) Disorders

No phenotypes other than those discussed in this *GeneReview* are known to be associated with germline pathogenic variants in *EPB42*.

Differential Diagnosis

The **initial evaluation of a person with hemolytic anemia** typically includes:

- Complete blood count and reticulocyte count;
- Blood smear review;
- Direct and indirect anti-globulin test (DAT and IAT, traditionally called direct and indirect Coombs, respectively) to evaluate for autoimmune (or, in an infant, alloimmune) hemolytic anemia;
- Hemoglobin electrophoresis;
- G6PD enzyme activity (especially in males).

Osmotic fragility testing and/or ektacytometry can identify erythrocyte membrane disorders. Figure 1 demonstrates ektacytometry results typical of hereditary spherocytosis.

For the individual with **nonimmune hemolytic anemia**, the differential diagnosis includes other forms of hereditary spherocytosis (see Table 3a) and other causes of hereditary hemolytic anemia (see Table 3b).

Table 3a. Genes Associated With Hereditary Spherocytosis

Gene	Protein	MOI	Severity [1]	Comment	OMIM
ANK1	Ankyrin-1	AD	Mild to moderate		182900
		AR	Moderately severe to severe	Often transfusion dependent	
EPB42	Protein 4.2 [2]	AR	Mild to moderate [3]	1 person reported w/ moderately severe HS	612690
SLC4A1	Band 3 anion transport protein	AD	Mild to moderate		612653
		AR	Severe [2]	Rare; persons present w/ life-threatening hydrops fetalis & remain transfusion dependent even after splenectomy.	
SPTA1	Spectrin alpha chain, erythrocytic 1	AR	Severe	Very frequently transfusion dependent	270970
SPTB	Spectrin beta chain, erythrocytic	AD	Mild to moderate		616649
		AR	Severe	1 person reported: infant w/fatal HS	

AD = autosomal dominant; AR = autosomal recessive; HS = hereditary spherocytosis; MOI = mode of inheritance
1. Defined in Table 1.
2. Significant decrease or absence of erythrocyte membrane protein 4.2 in erythrocytes of persons with HS may also be secondary to biallelic *SLC4A1* pathogenic variants by either decreasing band 3 in the red blood cell membrane [Toye et al 2008] or affecting the band 3 binding site for protein 4.2 [Kanzaki et al 1997].
3. *EPB42*-related HS is typically milder than the other forms of HS inherited in an AR manner (i.e., autosomal recessive *ANK1*-related HS and *SPTA1*-related HS) [Kalfa 2021].

Table 3b. Other Causes of Hereditary Hemolytic Anemia

Gene	Disorder	MOI	Comment
EPB41 *SPTA1* *SPTB*	Hereditary elliptocytosis (OMIM 130600, 611804, 617948)	AR AD	Persons homozygous for either *EPB42* p.Ala142Thr or p.Asp175Tyr also have ovalocytes & stomatocytes in blood smear. Note: Splenectomy has been assoc w/significant & life-threatening thrombotic events in persons w/hereditary stomatocytosis (overhydrated or dehydrated/xerocytosis); thus, differentiation between hereditary stomatocytosis & EPB42-HS is necessary if splenectomy is contemplated.
PIEZO1	Hereditary stomatocytosis (OMIM 194380)	AD	
SLC4A1	Southeast Asian ovalocytosis (OMIM 166900)	AD	
HBA1 *HBA2* *HBZ*	HbH disease (See Alpha-Thalassemia.)	See footnote 1.	EPB42-HS is usually easily distinguished from HbH disease & beta-thalassemia, which are characterized by microcytosis & hypochromia.
HBB	Beta-thalassemia	AR	
G6PD	Glucose-6-phospate dehydrogenase (G6PD) deficiency (OMIM 300908)	XL	Erythrocyte enzymopathies, such as G6PD deficiency & PK deficiency, are typically distinguished from EPB42-HS by absence of spherocytic red blood cell morphology & normal ektacytometry or osmotic fragility. [2]
PKLR	Pyruvate kinase (PK) deficiency (OMIM 266200)	AR	
CDAN1 *CDIN1* *KIF23* *KLF1* *SEC23B*	Congenital dyserythropoietic anemia (CDA) (See CDA I.)	AR AD [3]	CDA should be considered, esp CDA II when it presents w/mild phenotype (i.e., mild anemia, reticulocytosis [although suboptimal], jaundice, & splenomegaly). These disorders may be distinguished from EPB42-HS based on findings of inadequate reticulocytosis, dyserythropoiesis (i.e., binucleated & multinucleated erythroblasts in bone marrow studies) & tendency to cause iron overload disproportionate to history of red cell transfusions.

AD = autosomal dominant; AR = autosomal recessive; EPB42-HS = *EPB42*-related hereditary spherocytosis; HS = hereditary spherocytosis; MOI = mode of inheritance; XL = X-linked

1. See Alpha-Thalassemia, Genetic Counseling.

2. Some erythrocyte enzyme disorders (e.g., triose phosphate isomerase deficiency [OMIM 615512] or phosphoglycerate kinase 1 deficiency [OMIM 300653]) also have neurologic and musculoskeletal manifestations.

3. CDA I (caused by pathogenic variants in *CDAN1* or *CDIN1*) and CDA II (caused by pathogenic variants in *SEC23B*) are inherited in an autosomal recessive manner. CDA III (caused by pathogenic variants in *KIF23*) and CDA IV (caused by pathogenic variants in *KLF1*) are inherited in an autosomal dominant manner.

Management

Evaluations Following Initial Diagnosis

To establish the extent of disease and needs in an individual diagnosed with *EPB42*-related hereditary spherocytosis (EPB42-HS), the evaluations summarized in Table 4 (if not performed as part of the evaluation that led to the diagnosis) are recommended.

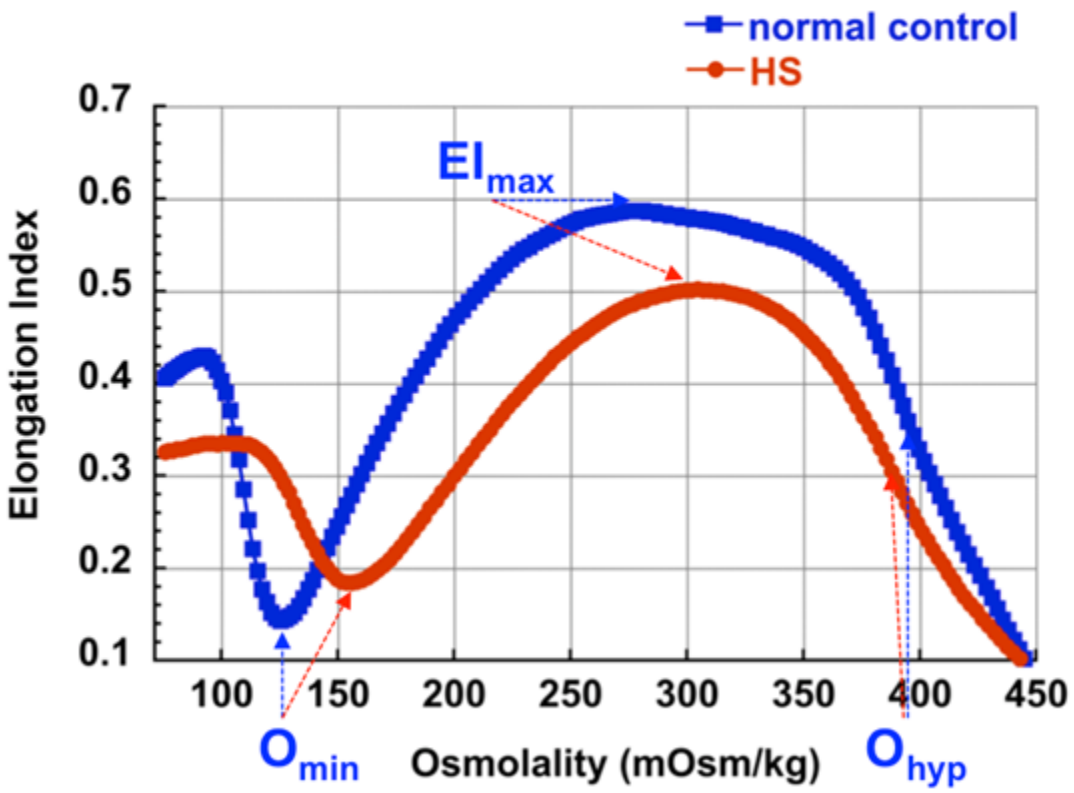

Figure 1. Ektacytometry indicating a typical curve for hereditary spherocytosis (red), characterized by increased O_{min} and decreased EI_{max} and O_{hyp} in comparison to normal control (blue). O_{min} corresponds to the osmolality where 50% of the cells hemolyze in the osmotic fragility test and its value is affected by the surface area-to-volume ratio. EI_{max} is the maximum elongation that the RBCs can achieve under shear stress and relates especially to the mechanical properties of the red cell membrane skeleton. O_{hyp} is the osmolality value at which the EI is 50% of its maximum value and decreases as the intracellular viscosity increases [Mohandas et al 1982].

Table 4. Recommended Evaluations Following Initial Diagnosis in Individuals with *EPB42*-Related Hereditary Spherocytosis

System/Concern	Evaluation	Comment
Hyperbilirubinemia	Serum bilirubin concentration	
Anemia	• Hemoglobin • Reticulocyte count • Transfusion history	To evaluate disease severity
Iron overload	Serum ferritin concentration	
Cholelithiasis	Abdominal ultrasound exam to assess for cholelithiasis	In those w/signs/symptoms of cholelithiasis or beginning at age 10-12 yrs in those w/significant hemolysis
Splenomegaly	Abdominal ultrasound exam to evaluate spleen size	If physical exam is not conclusive due to body habitus or if contact sports are contemplated
Genetic counseling	By genetics professionals [1]	To inform affected persons & their families re nature, MOI, & implications of EPB42-HS to facilitate medical & personal decision making

EPB42-HS = *EPB42*-related hereditary spherocytosis; MOI = mode of inheritance
1. Medical geneticist, certified genetic counselor, certified advanced genetic nurse

Treatment of Manifestations

Detailed management guidelines for hereditary spherocytosis have been published [Eber & Lux 2004, Bolton-Maggs et al 2012]. However, increased information on genotype-phenotype correlation along with the current wider availability of partial splenectomy calls for a new consensus statement of experts in the field on updated management guidelines [Iolascon et al 2017, Rothman et al 2020, Kalfa 2021].

Table 5. Treatment of Manifestations in Individuals with *EPB42*-Related Hereditary Spherocytosis

Manifestation/ Concern	Treatment	Considerations/Other
Hyperbilirubinemia	• **Neonatal unconjugated hyperbilirubinemia** may require treatment w/phototherapy &/or exchange transfusion, depending on level of bilirubin & age & weight of neonate. [1] • **Conjugated hyperbilirubinemia** (obstructive jaundice) requires eval for cholestasis & appropriate treatment.	Rarely, obstructive jaundice may develop in neonates due to excessive hemolysis → secondary liver damage (to date, not reported in EPB42-HS; more likely in severe hereditary hemolytic anemia); in such instances, consider overtransfusion to suppress endogenous erythropoiesis & interrupt continuing hemolysis & liver insult. [2]
Anemia	• Folic acid supplementation (400 µg 1x/d until age 1 yr; 1 mg 1x/d thereafter) • Red blood cell transfusion as needed for hemolytic or aplastic crisis • Routine immunizations (incl annual influenza vaccine) to prevent infections & precipitation of hemolytic or aplastic crisis	
	• Supplemental iron only in those w/confirmed iron deficiency • Carefully monitor iron status w/ferritin & transferrin or TIBC saturation. • Discontinue iron therapy after iron stores are repleted to avoid iron overload.	Avoidance of iron supplementation unless concurrent iron deficiency is confirmed w/ iron studies
Iron overload	Strongly consider treatment w/iron chelator if child remains transfusion dependent after 1st yr of life. Monitor ferritin & obtain T_2*-weighted MRI to determine hepatic iron levels if ferritin remains steadily ↑ (>300-500 ng/mL).	
Splenomegaly	Immunizations recommended **before splenectomy**: • 23-valent pneumococcal polysaccharide vaccine (PPSV23) for *S pneumoniae* given ≥2 wks before splenectomy • Meningococcal conjugate vaccine for *N meningitidis* against serogroups A, C, W, & Y (MenACWY) given ≥2 wks before splenectomy • Prevnar-13® • *H influenzae* type b	• A 2-dose primary series of MenACWY given 8-12 wks apart [3] • Prevnar-13® & *H influenzae* type b vaccines given during infancy per general pediatric guidelines
	Partial splenectomy is assoc w/lower risk for post-splenectomy sepsis & ↓ hemolysis; may be preferable for young children if done by experienced surgeon.	Antibiotic prophylaxis may be discontinued 1 yr after partial splenectomy if immune splenic function is adequate as assessed by pit count (% of pitted or pocked red cells). [4]

Table 5. continued from previous page.

Manifestation/ Concern	Treatment	Considerations/Other
	Splenectomy only in those w/severe disease & only after age 5 yrs	Rarely indicated in EPB42-HS, as disease severity is usually mild or moderate; splenectomy is curative but entails long-term risk for life-threatening infections. [5]
Immune deficiency (following splenectomy)	PPSV23 booster dose 5 yrs after 1st dose	No more than 2 doses of PPSV23 are recommended. [6]
	Meningococcal conjugate vaccine booster dose: • 3 yrs after primary series if 2-dose primary series was given between ages 2-6 yrs • Every 5 yrs if 2-dose primary series or booster dose was given at age 7 yrs or older [7]	Serogroup B meningococcal vaccines recommended for those age ≥10 yrs w/ history of splenectomy
	Prophylactic antibiotics. Penicillin V-K 250 mg 2x/dy OR erythromycin for those allergic to penicillin	Controversy exists re duration of prophylactic antibiotics post splenectomy: some hematologists recommend for 3 yrs post splenectomy, others for life. [4]
	Treatment of fever. Immediate medical attn & IV antibiotics w/good coverage for encapsulated organisms (typically ceftriaxone in doses adequate to treat meningitis: 100 mg/kg/d ≤2 g/d in single daily dose)	Incidence of post-splenectomy sepsis, a life-threatening complication, is higher than in general population.
Cholelithiasis	**Cholecystectomy** • In those w/signs/symptoms of cholelithiasis • In those w/history of cholelithiasis undergoing splenectomy • Consider in asymptomatic persons when cholelithiasis is identified on screening ultrasound to prevent complications incl obstructive jaundice &/or pancreatitis.	In children who require cholecystectomy, concurrent splenectomy is no longer recommended; need for splenectomy should be assessed on a case-by-case basis & the indication of splenectomy justified independently. [8]

EPB42-HS = *EPB42*-related hereditary spherocytosis; TIBC = total iron-binding capacity

1. American Academy of Pediatrics Subcommittee on Hyperbilirubinemia [2004]
2. Mizukawa et al [2011]
3. Committee on Infectious Diseases [2011]
4. Eber & Lux [2004]
5. Casale & Perrotta [2011]
6. Nuorti et al [2010]
7. Cohn et al [2013]
8. Bolton-Maggs et al [2012], Ruparel et al [2014]

Surveillance

Table 6. Recommended Surveillance for Individuals with *EPB42*-Related Hereditary Spherocytosis

System/Concern	Evaluation	Frequency
Hyperbilirubinemia	Serum bilirubin concentration	• Monitor in neonates during 1st wk of life. • Monitor every 2-5 yrs later in life. • If persistently ↑, consider possibility of concurrent Gilbert syndrome, which ↑s risk for early development of cholelithiasis.

Table 6. continued from previous page.

System/Concern	Evaluation	Frequency
Anemia	Hemoglobin	Monitor in infants in 1st 2-4 mos of life, then as needed depending on degree of anemia & disease severity.
Iron overload	Serum ferritin concentration	• At least annually in those requiring frequent transfusions • In those on chelation, monitor ferritin values every 3-4 mos.
	T_2*-weighted MRI or FerriScan®	Annually to monitor efficacy of chelation & adjust appropriately
Cholelithiasis	Abdominal ultrasound exam	When signs/symptoms of cholelithiasis develop or every 5-10 yrs beginning at age 10-12 yrs in those w/significant hemolysis

Agents/Circumstances to Avoid

Any preparations containing iron should be avoided except in those with iron deficiency documented with appropriate studies (see Treatment of Manifestations).

Contact sports are not advisable in those with splenomegaly; of note, acute or excessive splenomegaly is a greater risk than chronic mild splenomegaly.

Evaluation of Relatives at Risk

It is appropriate to evaluate apparently asymptomatic older and younger sibs of an affected individual in order to identify as early as possible those who would benefit from prompt initiation of treatment and preventive measures. Evaluations include:

- Laboratory evaluation of the phenotype (complete blood count and reticulocyte count, blood smear, osmotic fragility, or ektacytometry);
- Molecular genetic testing for the *EPB42* pathogenic variants in the family.

Neonates require monitoring of serum bilirubin concentration during the first week of life so that treatment for hyperbilirubinemia can be instituted promptly to avoid complications such as kernicterus. Infants require monitoring in the first two to four months of life for significant anemia, which may require red blood cell transfusion. Initiation of folate supplementation should be considered in individuals with chronic hemolytic anemia with significant reticulocytosis.

See Genetic Counseling for issues related to testing of at-risk relatives for genetic counseling purposes.

Pregnancy Management

Folic acid supplementation (800-1,000 µg daily) is recommended in pregnant women with EPB42-HS.

Monitoring for exacerbation of anemia with complete blood count and reticulocyte count is recommended in pregnant women, as hemolytic crisis and persistent anemia have been reported during pregnancy in women with hemolytic anemia, especially in women who have not undergone splenectomy [Pajor et al 1993].

Therapies Under Investigation

Search ClinicalTrials.gov in the US and EU Clinical Trials Register in Europe for access to information on clinical studies for a wide range of diseases and conditions. Note: There may not be clinical trials for this disorder.

Genetic Counseling

Genetic counseling is the process of providing individuals and families with information on the nature, mode(s) of inheritance, and implications of genetic disorders to help them make informed medical and personal decisions. The following section deals with genetic risk assessment and the use of family history and genetic testing to clarify genetic status for family members; it is not meant to address all personal, cultural, or ethical issues that may arise or to substitute for consultation with a genetics professional. —ED.

Mode of Inheritance

EPB42-related hereditary spherocytosis (EPB42-HS) is inherited in an autosomal recessive manner.

Risk to Family Members

Parents of a proband

- The parents of an affected child are presumed to be heterozygous for an *EPB42* pathogenic variant.
- Molecular genetic testing is recommended for the parents of a proband to confirm that both parents are heterozygous for an *EPB42* pathogenic variant and to allow reliable recurrence risk assessment. If a pathogenic variant is detected in only one parent and parental identity testing has confirmed biological maternity and paternity, the following possibilities should be considered:
  - One of the pathogenic variants identified in the proband occurred as a *de novo* event in the proband or as a postzygotic *de novo* event in a mosaic parent [Jónsson et al 2017].
  - Uniparental isodisomy for the parental chromosome with the pathogenic variant resulted in homozygosity for the pathogenic variant in the proband.
- Heterozygotes (carriers) are asymptomatic and are not at risk of developing the disorder.

Sibs of a proband

- If both parents are known to be heterozygous for an *EPB42* pathogenic variant, each sib of an affected individual has at conception a 25% chance of being affected, a 50% chance of being an asymptomatic carrier, and a 25% chance of inheriting neither of the familial *EPB42* pathogenic variants.
- Heterozygotes (carriers) are asymptomatic and are not at risk of developing the disorder.

Offspring of a proband. The offspring of an individual with EPB42-HS are obligate heterozygotes (carriers) for an *EPB42* pathogenic variant.

Other family members. Each sib of the proband's parents is at a 50% risk of being a carrier of an *EPB42* pathogenic variant.

Carrier Detection

Carrier testing for at-risk relatives requires prior identification of the *EPB42* pathogenic variants in the family.

Related Genetic Counseling Issues

See Management, Evaluation of Relatives at Risk for information on evaluating at-risk relatives for the purpose of early diagnosis and treatment.

Family planning

- The optimal time for determination of genetic risk and discussion of the availability of prenatal/preimplantation genetic testing is before pregnancy.

- It is appropriate to offer genetic counseling (including discussion of potential risks to offspring and reproductive options) to young adults who are affected, are carriers, or are at risk of being carriers.

Prenatal Testing and Preimplantation Genetic Testing

Once the *EPB42* pathogenic variants have been identified in an affected family member, prenatal testing for a pregnancy at increased risk and preimplantation genetic testing for EPB42-HS are possible.

Differences in perspective may exist among medical professionals and within families regarding the use of prenatal testing. While most centers would consider use of prenatal testing to be a personal decision, discussion of these issues may be helpful.

Resources

GeneReviews staff has selected the following disease-specific and/or umbrella support organizations and/or registries for the benefit of individuals with this disorder and their families. GeneReviews is not responsible for the information provided by other organizations. For information on selection criteria, click here.

- **MedlinePlus**
  Hereditary spherocytosis

Molecular Genetics

Information in the Molecular Genetics and OMIM tables may differ from that elsewhere in the GeneReview: tables may contain more recent information. —ED.

Table A. EPB42-Related Hereditary Spherocytosis: Genes and Databases

Gene	Chromosome Locus	Protein	Locus-Specific Databases	HGMD	ClinVar
EPB42	15q15.2	Protein 4.2	EPB42 database	EPB42	EPB42

Data are compiled from the following standard references: gene from HGNC; chromosome locus from OMIM; protein from UniProt. For a description of databases (Locus Specific, HGMD, ClinVar) to which links are provided, click here.

Table B. OMIM Entries for EPB42-Related Hereditary Spherocytosis (View All in OMIM)

177070	PROTEIN 4.2, ERYTHROCYTIC; EPB42
612690	SPHEROCYTOSIS, TYPE 5; SPH5

Molecular Pathogenesis

Erythrocyte membrane protein band 4.2 (also known as protein 4.2), encoded by *EPB42*, is a major component of the red blood cell (RBC) cytoskeleton and maintains the stability and flexibility of red blood cells through interactions with other key RBC proteins, many of which (in their pathogenic forms) also cause hereditary spherocytosis.

Protein 4.2 is a part of the ankyrin-band 3 complex, connecting band 3 anion transport protein (encoded by *SLC4A1*; see Table 3a) with the CD47 and Rhesus protein complex antigens. Protein 4.2 supports physical associations between the cytoskeleton and the membrane lipid bilayer [Bruce et al 2003]. Protein 4.2 interacts with spectrin, a tetramer comprising an alpha subunit and a beta subunit (see Table 3a), which is the largest protein in the RBC cytoskeleton [Mandal et al 2002, Korsgren et al 2010].

Mechanism of disease causation. Loss of function

Table 7. Notable *EPB42* Pathogenic Variants

Reference Sequences	DNA Nucleotide Change	Predicted Protein Change (Alias [1])	Comment [Reference]
NM_000119.3 NP_000110.2	c.424G>A	p.Ala142Thr (4.2 Nippon)	Founder variant in Japanese population w/carrier frequency of ~3% [Bouhassira et al 1992]; see Genotype-Phenotype Correlations.
	c.523G>T	p.Asp175Tyr (4.2 Komatsu)	See Genotype-Phenotype Correlations.
	c.950delG	p.Arg317ProfsTer3 (4.2 Nancy)	

Variants listed in the table have been provided by the authors. *GeneReviews* staff have not independently verified the classification of variants.
GeneReviews follows the standard naming conventions of the Human Genome Variation Society (varnomen.hgvs.org). See Quick Reference for an explanation of nomenclature.
1. Variant designation that does not conform to current naming conventions

Chapter Notes

Author Notes

Theodosia Kalfa, MD, PhD

Kalfa Lab

Acknowledgments

The authors' work related to this review was supported by the National Institutes of Health, National Center for Advancing Translational Sciences (award 1UL1TR001425-01), and National Heart, Lung, and Blood Institute grant R01 HL152099. The content is solely the responsibility of the authors and does not necessarily represent the official views of the National Institutes of Health.

Author History

Amber H Begtrup, PhD, FACMG (2014-present)
Jessica A Connor, MS; Counsyl, Inc (2014-2022)
Theodosia A Kalfa, MD, PhD (2014-present)

Revision History

- 7 April 2022 (sw) Comprehensive update posted live
- 10 November 2016 (ma) Comprehensive update posted live
- 13 March 2014 (me) Review posted live
- 20 October 2013 (tk) Original submission

References

Published Guidelines / Consensus Statements

Iolascon A, Andolfo I, Barcellini W, Corcione F, Garçon L, De Franceschi L, Pignata C, Graziadei G, Pospisilova D, Rees DC, de Montalembert M, Rivella S, Gambale A, Russo R, Ribeiro L, Vives-Corrons J, Martinez PA,

Kattamis A, Gulbis B, Cappellini MD, Roberts I, Tamary H, et al. Recommendations regarding splenectomy in hereditary hemolytic anemias. Available online. 2017. Accessed 3-30-22.

Literature Cited

American Academy of Pediatrics Subcommittee on Hyperbilirubinemia. Management of hyperbilirubinemia in the newborn infant 35 or more weeks of gestation. Pediatrics. 2004;114:297–316. PubMed PMID: 15231951.

Beauchamp-Nicoud A, Morle L, Lutz HU, Stammler P, Agulles O, Petermann-Khder R, Iolascon A, Perrotta S, Cynober T, Tchernia G, Delaunay J, Baudin-Creuza V. Heavy transfusions and presence of an anti-protein 4.2 antibody in 4. 2(-) hereditary spherocytosis (949delG). Haematologica. 2000;85:19–24. PubMed PMID: 10629586.

Bolton-Maggs PH, Langer JC, Iolascon A, Tittensor P, King MJ. Guidelines for the diagnosis and management of hereditary spherocytosis--2011 update. Br J Haematol. 2012;156:37–49. PubMed PMID: 22055020.

Bouhassira EE, Schwartz RS, Yawata Y, Ata K, Kanzaki A, Qiu JJ, Nagel RL, Rybicki AC. An alanine-to-threonine substitution in protein 4.2 cDNA is associated with a Japanese form of hereditary hemolytic anemia (protein 4.2NIPPON). Blood. 1992;79:1846–54. PubMed PMID: 1558976.

Bruce LJ, Beckmann R, Ribeiro ML, Peters LL, Chasis JA, Delaunay J, Mohandas N, Anstee DJ, Tanner MJ. A band 3-based macrocomplex of integral and peripheral proteins in the RBC membrane. Blood. 2003;101:4180–8. PubMed PMID: 12531814.

Casale M, Perrotta S. Splenectomy for hereditary spherocytosis: complete, partial or not at all? Expert Rev Hematol. 2011;4:627–35. PubMed PMID: 22077527.

Clark MR, Mohandas N, Shohet SB. Osmotic gradient ektacytometry: comprehensive characterization of red cell volume and surface maintenance. Blood. 1983;61:899–910. PubMed PMID: 6831052.

Cohn AC, MacNeil JR, Clark TA, Ortega-Sanchez IR, Briere EZ, Meissner HC, Baker CJ, Messonnier NE, et al. Prevention and control of meningococcal disease: recommendations of the Advisory Committee on Immunization Practices (ACIP). MMWR Recomm Rep. 2013;62:1–28. PubMed PMID: 23515099.

Committee on Infectious Diseases. Meningococcal conjugate vaccines policy update: booster dose recommendations. Pediatrics. 2011;128:1213–8. PubMed PMID: 22123893.

Eber S, Lux SE. Hereditary spherocytosis--defects in proteins that connect the membrane skeleton to the lipid bilayer. Semin Hematol. 2004;41:118–41. PubMed PMID: 15071790.

Hammill AM, Risinger MA, Joiner CH, Keddache M, Kalfa TA. Compound heterozygosity for two novel mutations in the erythrocyte protein 4.2 gene causing spherocytosis in a Caucasian patient. Br J Haematol. 2011;152:780–3. PubMed PMID: 21275958.

Hayette S, Dhermy D, dos Santos ME, Bozon M, Drenckhahn D, Alloisio N, Texier P, Delaunay J, Morlé L. A deletional frameshift mutation in protein 4.2 gene (allele 4.2 Lisboa) associated with hereditary hemolytic anemia. Blood. 1995;85:250–6. PubMed PMID: 7803799.

Iolascon A, Andolfo I, Barcellini W, Corcione F, Garçon L, De Franceschi L, Pignata C, Graziadei G, Pospisilova D, Rees DC, de Montalembert M, Rivella S, Gambale A, Russo R, Ribeiro L, Vives-Corrons J, Martinez PA, Kattamis A, Gulbis B, Cappellini MD, Roberts I, Tamary H, et al. Recommendations regarding splenectomy in hereditary hemolytic anemias. Haematologica. 2017;102:1304–13. PubMed PMID: 28550188.

Jónsson H, Sulem P, Kehr B, Kristmundsdottir S, Zink F, Hjartarson E, Hardarson MT, Hjorleifsson KE, Eggertsson HP, Gudjonsson SA, Ward LD, Arnadottir GA, Helgason EA, Helgason H, Gylfason A, Jonasdottir A, Jonasdottir A, Rafnar T, Frigge M, Stacey SN, Th Magnusson O, Thorsteinsdottir U, Masson G, Kong A, Halldorsson BV, Helgason A, Gudbjartsson DF, Stefansson K. Parental influence on human germline de novo mutations in 1,548 trios from Iceland. Nature. 2017;549:519–22. PubMed PMID: 28959963.

Kalfa TA. Diagnosis and clinical management of red cell membrane disorders. Hematology Am Soc Hematol Educ Program. 2021;2021:331–40. PubMed PMID: 34889366.

Kanzaki A, Hayette S, Morle L, Inoue F, Matsuyama R, Inoue T, Yawata A, Wada H, Vallier A, Alloisio N, Yawata Y, Delaunay J. Total absence of protein 4.2 and partial deficiency of band 3 in hereditary spherocytosis. Br J Haematol. 1997;99:522–30. PubMed PMID: 9401060.

Kanzaki A, Yawata Y, Yawata A, Inoue T, Okamoto N, Wada H, Harano T, Harano K, Wilmotte R, Hayette S. Band 4.2 Komatsu: 523 GAT-->TAT (175 Asp-->Tyr) in exon 4 of the band 4.2 gene associated with total deficiency of band 4.2, hemolytic anemia with ovalostomatocytosis and marked disruption of the cytoskeletal network. Int J Hematol. 1995;61:165–78. PubMed PMID: 8547605.

Korsgren C, Peters LL, Lux SE. Protein 4.2 binds to the carboxyl-terminal EF-hands of erythroid alpha-spectrin in a calcium- and calmodulin-dependent manner. J Biol Chem. 2010;285:4757–70. PubMed PMID: 20007969.

Mandal D, Moitra PK, Basu J. Mapping of a spectrin-binding domain of human erythrocyte membrane protein 4.2. Biochem J. 2002;364:841–7. PubMed PMID: 12049649.

Mizukawa B, George A, Pushkaran S, Weckbach L, Kalinyak K, Heubi JE, Kalfa TA. Cooperating G6PD mutations associated with severe neonatal hyperbilirubinemia and cholestasis. Pediatr Blood Cancer. 2011;56:840–2. PubMed PMID: 20949590.

Mohandas N, Clark MR, Health BP, Rossi M, Wolfe LC, Lux SE, Shohet SB. A technique to detect reduced mechanical stability of red cell membranes: relevance to elliptocytic disorders. Blood. 1982;59:768–74. PubMed PMID: 7059678.

Nuorti JP, Whitney CG, et al. Prevention of pneumococcal disease among infants and children--use of 13-valent pneumococcal conjugate vaccine and 23-valent pneumococcal polysaccharide vaccine. Recommendations of the Advisory Committee on Immunization Practices (ACIP). MMWR Recomm Rep. 2010;59:1–18. PubMed PMID: 21150868.

Pajor A, Lehoczky D, Szakacs Z. Pregnancy and hereditary spherocytosis. Report of 8 patients and a review. Arch Gynecol Obstet. 1993;253:37–42. PubMed PMID: 8328819.

Perrotta S, Gallagher PG, Mohandas N. Hereditary spherocytosis. Lancet. 2008;372:1411–26. PubMed PMID: 18940465.

Perrotta S, Iolascon A, Polito R, d'Urzo G, Conte ML, Miraglia del Giudice E. 4.2 Nippon mutation in a non-Japanese patient with hereditary spherocytosis. Haematologica. 1999;84:660–2. PubMed PMID: 10406914.

Risinger M, Kalfa TA. Red cell membrane disorders: structure meets function. Blood. 2020;136:1250–61. PubMed PMID: 32702754.

Rothman JA, Stevens JL, Gray FL, Kalfa TA. How I approach hereditary hemolytic anemia and splenectomy. Pediatr Blood Cancer. 2020;67:e28337. PubMed PMID: 32391969.

Ruparel RK, Bogert JN, Moir CR, Ishitani MB, Khan SP, Rodriguez V, Zarroug AE. Synchronous splenectomy during cholecystectomy for hereditary spherocytosis: is it really necessary? J Pediatr Surg. 2014;49:433–5. PubMed PMID: 24650472.

Satchwell TJ, Shoemark DK, Sessions RB, Toye AM. Protein 4.2: a complex linker. Blood Cells Mol Dis. 2009;42:201–10. PubMed PMID: 19269200.

Stenson PD, Mort M, Ball EV, Chapman M, Evans K, Azevedo L, Hayden M, Heywood S, Millar DS, Phillips AD, Cooper DN. The Human Gene Mutation Database (HGMD®): optimizing its use in a clinical diagnostic or research setting. Hum Genet. 2020;139:1197–207. PubMed PMID: 32596782.

Takaoka Y, Ideguchi H, Matsuda M, Sakamoto N, Takeuchi T, Fukumaki Y. A novel mutation in the erythrocyte protein 4.2 gene of Japanese patients with hereditary spherocytosis (protein 4.2 Fukuoka). Br J Haematol. 1994;88:527–33. PubMed PMID: 7819064.

Toye AM, Williamson RC, Khanfar M, Bader-Meunier B, Cynober T, Thibault M, Tchernia G, Dechaux M, Delaunay J, Bruce LJ. Band 3 Courcouronnes (Ser667Phe): a trafficking mutant differentially rescued by wild-type band 3 and glycophorin A. Blood. 2008;111:5380–9. PubMed PMID: 18174378.

van den Akker E, Satchwell TJ, Pellegrin S, Flatt JF, Maigre M, Daniels G, Delaunay J, Bruce LJ, Toye AM. Investigating the key membrane protein changes during in vitro erythropoiesis of protein 4.2 (-) cells (mutations Chartres 1 and 2). Haematologica. 2010;95:1278–86. PubMed PMID: 20179084.

Yawata Y, Kanzaki A, Yawata A, Doerfler W, Ozcan R, Eber SW. Characteristic features of the genotype and phenotype of hereditary spherocytosis in the Japanese population. Int J Hematol. 2000;71:118–35. PubMed PMID: 10745622.

Yawata Y. Red cell membrane protein band 4.2: phenotypic, genetic and electron microscopic aspects. Biochim Biophys Acta. 1994;1204:131–48. PubMed PMID: 8142452.

License

GeneReviews® chapters are owned by the University of Washington. Permission is hereby granted to reproduce, distribute, and translate copies of content materials for noncommercial research purposes only, provided that (i) credit for source (http://www.genereviews.org/) and copyright (© 1993-2024 University of Washington) are included with each copy; (ii) a link to the original material is provided whenever the material is published elsewhere on the Web; and (iii) reproducers, distributors, and/or translators comply with the GeneReviews® Copyright Notice and Usage Disclaimer. No further modifications are allowed. For clarity, excerpts of GeneReviews chapters for use in lab reports and clinic notes are a permitted use.

For more information, see the GeneReviews® Copyright Notice and Usage Disclaimer.

For questions regarding permissions or whether a specified use is allowed, contact: admasst@uw.edu.