U.S. National Library of Medicine
National Center for Biotechnology Information

NLM Citation: Richmond CM, Savarirayan R. Schmid Metaphyseal Chondrodysplasia. 2019 Oct 21 [Updated 2024 May 9]. In: Adam MP, Feldman J, Mirzaa GM, et al., editors. GeneReviews® [Internet]. Seattle (WA): University of Washington, Seattle; 1993-2024.
Bookshelf URL: https://www.ncbi.nlm.nih.gov/books/

Schmid Metaphyseal Chondrodysplasia

Synonyms: Metaphyseal Chondrodysplasia Type Schmid (MCDS); Metaphyseal Dysplasia Schmid (MCS), *COL10A1*-Related

Christopher Mark Richmond, BBiomedSc, MBBS, FRACP[1,2] and Ravi Savarirayan, MBBS, MD, FRACP, ARCPA (Hon)[3]

Created: October 21, 2019; Updated: May 9, 2024.

Summary

Clinical characteristics

Schmid metaphyseal chondrodysplasia (SMCD) is characterized by progressive short stature that develops by age two years. The clinical and radiographic features are usually not present at birth, but manifest in early childhood with short limbs, genu varum, and waddling gait. Facial features and head size are normal. Radiographs show metaphyseal irregularities of the long bones (e.g., splaying, flaring, cupping); shortening of the tubular bones; widened growth plates; coxa vara; and anterior cupping, sclerosis, and splaying of the ribs. Mild hand involvement often includes shortening of the tubular bones and metaphyseal cupping of the metacarpals and proximal phalanges. Platyspondyly and vertebral end plate irregularities are less common. Hand and vertebral involvement can resolve with age. Early motor milestones may be delayed due to orthopedic complications. Intelligence is normal. Joint pain in the knees and hips is common and may limit physical activity. Adult height is typically more than 3.5 standard deviations below the mean, although a wide spectrum that overlaps normal height has been reported. There are no extraskeletal manifestations.

Diagnosis/testing

The diagnosis of SMCD is established in a proband with characteristic clinical and radiographic features and/or identification of a heterozygous pathogenic variant in *COL10A1* by molecular genetic testing.

Management

Treatment of manifestations: Management of orthopedic complications by an orthopedist, physiotherapist, occupational therapist, and pain specialist as indicated; joint-friendly exercise, weight management; mobility device as needed; corrective osteotomy by guided growth surgery or valgus osteotomy may be considered in late childhood / adolescence in those with progressive or symptomatic varus deformity, significant coxa vara,

Author Affiliations: 1 Genetic Health Queensland, Royal Brisbane & Women's Hospital Herston, Queensland, Australia; Email: chris.richmond@health.qld.gov.au. 2 School of Medicine, Griffith University, Southport, Queensland, Australia; Email: chris.richmond@health.qld.gov.au. 3 Victorian Clinical Genetics Service, Murdoch Children's Research Institute, Parkville, Victoria, Australia; Email: ravi.savarirayan@vcgs.org.au.

Copyright © 1993-2024, University of Washington, Seattle. GeneReviews is a registered trademark of the University of Washington, Seattle. All rights reserved.

triangular fragment in the interior femoral neck, or poor or deteriorating function; exercise and support from nutritionist to maintain healthy weight; psychosocial support; environmental or occupational modifications as needed for short stature with recommendations from occupational therapist as needed.

Surveillance: Annual growth assessment; clinical evaluation for orthopedic manifestations; psychosocial evaluation.

Agents/circumstances to avoid: Obesity; physical activities that cause excessive joint strain.

Genetic counseling

SMCD is inherited in an autosomal dominant manner. Approximately half of individuals diagnosed with SMCD have an affected parent (the heterozygous parent almost always exhibits features of the condition; however, considerable intrafamilial phenotypic variability is observed). Approximately half of individuals diagnosed with SMCD have the disorder as the result of a *de novo COL10A1* pathogenic variant. Each child of an individual with SMCD has a 50% chance of inheriting the *COL10A1* pathogenic variant. If the proband and the proband's reproductive partner are affected with different dominantly inherited skeletal dysplasias, genetic counseling becomes more complicated because of the risk of inheriting two dominantly inherited bone growth disorders. Once the *COL10A1* pathogenic variant has been identified in an affected family member, prenatal testing for a pregnancy at increased risk for SMCD and preimplantation genetic testing are possible.

Diagnosis

No formal diagnostic criteria for Schmid metaphyseal chondrodysplasia (SMCD) have been established.

Suggestive Findings

SMCD **should be suspected** in individuals with the following clinical, laboratory, radiographic, and family history findings.

Clinical findings

- Short-limbed short stature by age two years (in >60%)
- Genu varum (bowed legs) (>60%)
- Waddling gait (>80%)
- Lumbar lordosis by age three to five years
- Normal craniofacies and absence of extraskeletal manifestations

Laboratory findings. Normal serum calcium, phosphate, vitamin D, and alkaline phosphatase

Radiographic findings (See Figure 1.)

- Shortening of the tubular bones (>60%)
- Metaphyseal irregularities of the long bones (e.g., splaying, flaring, cupping), especially the proximal and distal femora (~100%)
- Widening of the growth plates
- Coxa vara (>80%)
- Anterior cupping, sclerosis, and splaying of the ribs (>90%)
- Mild hand involvement including shortening of the tubular bones and metaphyseal cupping of the metacarpals and proximal phalanges (~50%). Radiographic phalangeal and metacarpal findings may resolve with age.
- Vertebral involvement including platyspondyly and end plate irregularities (~10%)

Family history is consistent with autosomal dominant inheritance (e.g., affected males and females in multiple generations). Absence of a known family history does not preclude the diagnosis, as approximately half of individuals have a *de novo* pathogenic variant, and in those with an inherited pathogenic variant, considerable intrafamilial variability can be present.

Establishing the Diagnosis

The diagnosis of SMCD is established in a proband with characteristic clinical and radiographic features (see Suggestive Findings) and/or a heterozygous pathogenic (or likely pathogenic) variant in *COL10A1* identified by molecular genetic testing (see Table 1).

Note: (1) Per ACMG/AMP variant interpretation guidelines, the terms "pathogenic variant" and "likely pathogenic variant" are synonymous in a clinical setting, meaning that both are considered diagnostic and can be used for clinical decision making [Richards et al 2015]. Reference to "pathogenic variants" in this *GeneReview* is understood to include likely pathogenic variants. (2) Identification of a heterozygous *COL10A1* variant of uncertain significance does not establish or rule out the diagnosis.

Molecular genetic testing approaches can include a combination of **gene-targeted testing** (single gene testing, multigene panel) and **comprehensive genomic testing** (exome sequencing, genome sequencing). Gene-targeted testing requires that the clinician determine which gene(s) are likely involved (see Option 1), whereas comprehensive genomic testing does not (see Option 2).

Option 1

When the phenotypic and radiographic findings suggest a diagnosis of SMCD, molecular genetic testing approaches can include **single-gene testing** or use of a **multigene panel**:

- **Single-gene testing.** Perform sequence analysis of *COL10A1* to detect missense, nonsense, and splice site variants and small intragenic deletions/insertions; typically, exon or whole-gene deletions/duplications are not detected. Note: All pathogenic variants reported to date are missense or truncating variants (including small intragenic deletions) in *COL10A1*; thus, testing for larger deletions or duplications is expected to be of low yield.

- **A multigene panel** that includes *COL10A1* and other genes of interest (see Differential Diagnosis) may be considered to identify the genetic cause of the condition while limiting identification of variants of uncertain significance and pathogenic variants in genes that do not explain the underlying phenotype. Note: (1) The genes included in the panel and the diagnostic sensitivity of the testing used for each gene vary by laboratory and are likely to change over time. (2) Some multigene panels may include genes not associated with the condition discussed in this *GeneReview*. (3) In some laboratories, panel options may include a custom laboratory-designed panel and/or custom phenotype-focused exome or genome analysis that includes genes specified by the clinician. (4) Methods used in a panel may include sequence analysis, deletion/duplication analysis, and/or other non-sequencing-based tests.

  For an introduction to multigene panels click here. More detailed information for clinicians ordering genetic tests can be found here.

Option 2

When the phenotype overlaps other inherited disorders characterized by metaphyseal dysplasia, **comprehensive genomic testing** is the best option. **Exome sequencing** is most commonly used; **genome sequencing** is also possible.

For an introduction to comprehensive genomic testing click here. More detailed information for clinicians ordering genomic testing can be found here.

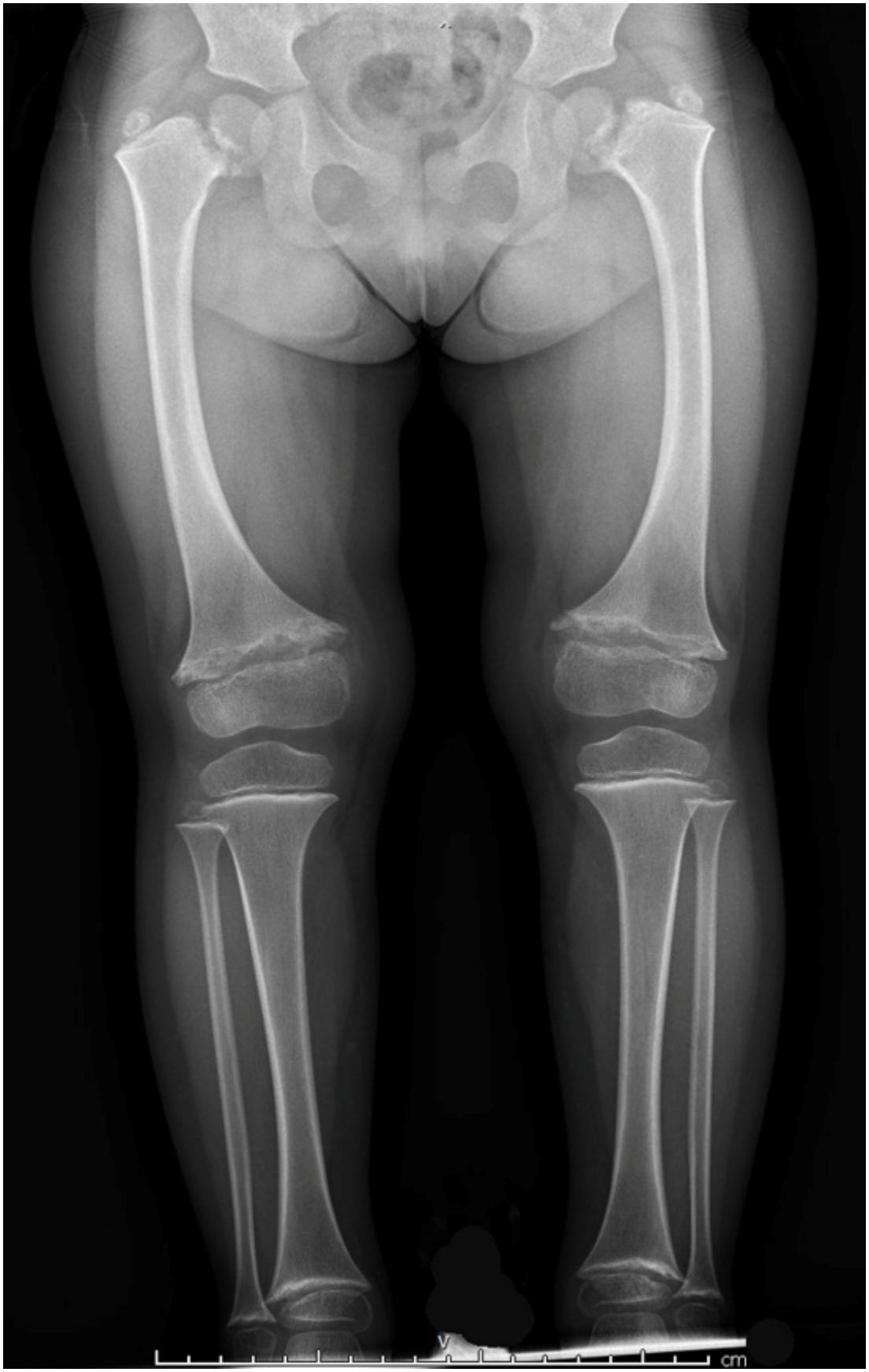

Figure 1. Standing lower-limb radiograph of a girl age four years with Schmid metaphyseal chondrodysplasia. Note severe bilateral coxa vara with marked metaphyseal widening at proximal femurs, and metaphyseal widening and irregularity of the distal femurs with femoral bowing.

Table 1. Molecular Genetic Testing Used in Schmid Metaphyseal Chondrodysplasia

Gene [1]	Method	Proportion of Pathogenic Variants [2] Identified by Method
COL10A1	Sequence analysis [3]	~100% [4]
	Gene-targeted deletion/duplication analysis [5]	None reported [6]

1. See Table A. Genes and Databases for chromosome locus and protein.
2. See Molecular Genetics for information on variants detected in this gene.
3. Sequence analysis detects variants that are benign, likely benign, of uncertain significance, likely pathogenic, or pathogenic. Variants may include missense, nonsense, and splice site variants and small intragenic deletions/insertions; typically, exon or whole-gene deletions/duplications are not detected. For issues to consider in interpretation of sequence analysis results, click here.
4. Data derived from the subscription-based professional view of Human Gene Mutation Database [Stenson et al 2020] and ClinVar [Landrum et al 2014]. All reported SMCD-related *COL10A1* pathogenic varinats were missense, frameshift, or nonsense variants or small intragenic deletions, duplications, or insertion-deletions.
5. Gene-targeted deletion/duplication analysis detects intragenic deletions or duplications. Methods used may include a range of techniques such as quantitative PCR, long-range PCR, multiplex ligation-dependent probe amplification (MLPA), and a gene-targeted microarray designed to detect single-exon deletions or duplications.
6. Review of all published reports, ClinVar [Landrum et al 2014], and HGMD [Stenson et al 2020] revealed no reports of large deletions or duplications causing SMCD to date [C Richmond, personal observation].

Clinical Characteristics

Clinical Description

Schmid metaphyseal chondrodysplasia (SMCD) is typically diagnosed in early childhood and is the most common and least severe metaphyseal chondrodysplasia [Al Kaissi et al 2018]. It results from disrupted calcification of metaphyseal cartilage and consequent restricted longitudinal growth of bones with preservation of the epiphyses. The clinical and radiographic features are usually not present at birth, but manifest in early childhood with limb shortening, genu varum, and a waddling gait [Bateman et al 2005]. The pattern of radiographic features is generally similar across individuals with SMCD, but clinical severity varies considerably [Mäkitie et al 2005]. There are no extraskeletal manifestations.

A comprehensive review of the published reports and clinical databases identified at least 150 published unrelated individuals with SMCD and a confirmed pathogenic variant in *COL10A1*. The following description of the phenotypic features associated with this condition is based on these reports and author observations in a multidisciplinary skeletal dysplasia clinic.

Table 2. Schmid Metaphyseal Chondrodysplasia: Frequency of Select Clinical and Radiographic Features

Features		% of Persons w/Feature	Comment
Clinical	Waddling gait	>80%	
	Genu varum	>80% [1]	Genu valgum less commonly reported
	Short stature	>60%	Typically apparent by age 2 yrs
	Lumbar lordosis	>60% [1]	Scoliosis less commonly reported

Table 2. continued from previous page.

Features		% of Persons w/Feature	Comment
Radiographic	Metaphyseal dysplasia of proximal/distal femora, proximal tibiae	~100%	Splaying, flaring, widening, cupping
	Cupped &/or sclerotic anterior rib ends	>90%	
	Coxa vara	50%-80% [1, 2]	Angle head & shaft of femur <120 degrees
	Short long bones	>60%	Typically apparent by age 2 yrs
	Metaphyseal dysplasia of hands	33%-47% [1, 3]	Metaphyseal cupping, short proximal phalanges/ metacarpals
	Vertebral dysplasia	9% [2]	Usually mild; platyspondyly, anterior rounding, indentations, & posterior wedging

1. Tüysüz et al [2023)
2. Savarirayan et al [2000]
3. Elliott et al [2005]

Growth. Most neonates with SMCD have normal growth parameters. Progressive growth failure typically begins in the second year of life, with individuals coming to medical attention after age two years with short-limbed short stature and bowed legs [Mäkitie et al 2005]. Adult height is typically more than 3.5 standard deviations (SD) below the mean, although a wide spectrum that overlaps normal height has been reported [Mäkitie et al 2005]. No standardized growth curves for SMCD are available.

Musculoskeletal. Most individuals with SMCD have genu varum (outward bowing at the knees), although valgus deformity has been reported. Waddling gait due to coxa vara is common by age two years and may require surgical correction. Joint pain in the knees and hips is common in children and adults with SMCD and may limit physical activity. Chronic joint pain may develop and limit mobility for some individuals. Lumbar lordosis is common, with typical onset by age three to five years. Scoliosis is less commonly reported [Park et al 2015, Cammarata-Scalisi et al 2019].

Radiographic findings. The metaphyses of the long bones become flared or widened. The proximal and distal femoral and proximal tibial metaphyses are consistently affected (ragged, cupped, sclerotic, or splayed) with widening of the growth plates. Enlarged capital femoral epiphyses are commonly reported and typically resolve between age 11 and 14 years [Tüysüz et al 2023]. Coxa vara (reduced angle to <120 degrees between the head and the shaft of the femur) is seen in a majority of individuals and is more prominent after age five years [Tüysüz et al 2023]. Coxa vara distinguishes SMCD from other forms of metaphyseal chondrodysplasia. Tibial and femoral bowing is typical. Metaphyseal irregularities of the distal ulnae and radii, and proximal and distal humeral metaphyses are less commonly reported [Lachman et al 1988, Al Kaissi et al 2018, de França et al 2020]. The anterior rib ends are often cupped or sclerotic [Bateman et al 2005].

Hand involvement is present in fewer than half of individuals and is usually mild. Metaphyseal cupping of the distal metacarpals and proximal phalanges and shortening of the phalanges may be seen and are more pronounced in the fifth ray. Hand features may become less apparent with age [Elliott et al 2005].

Vertebral involvement is less common and, when present, is usually mild. Reported findings include platyspondyly and vertebral end plate anomalies (e.g., rounding of the anterior aspects of the vertebral bodies, superior and inferior indentations of the vertebral bodies, posterior wedging of the vertebrae) [Hasegawa et al 1994, Savarirayan et al 2000]. Vertebral changes may become less apparent with age.

Obesity. Limited mobility due to chronic joint pain may contribute to the development of obesity and associated comorbidities.

Craniofacial. The craniofacial bones and facial appearance are normal [Bateman et al 2005].

Neurodevelopment. Intelligence is normal. Attainment of early motor milestones is usually preserved in infancy; however, mild gross and fine motor delays may accompany orthopedic complications in early childhood.

Other. Hypothyroidism, growth hormone deficiency, celiac disease, hypospadias, and mild microcephaly have been rarely reported [de França et al 2020, Chreitah et al 2023]; however, these may represent coincidental occurrences and may be unrelated to SMCD.

Homozygotes. Biallelic pathogenic variants in *COL10A1* have been associated with a more severe phenotype [Ain et al 2018, Tüysüz et al 2023] and in some instances embryonic lethality [Zhang et al 2018].

Genotype-Phenotype Correlations

A more severe phenotype has been observed in individuals with missense pathogenic variants in the signal peptide domain at the N-terminal end of the protein and in the NC1 domain compared to truncating pathogenic variants [Tüysüz et al 2023]; however, no established genotype-phenotype correlations have been identified.

Penetrance

Penetrance approaches 100%; however, there is wide inter- and intrafamilial phenotypic variation [Kong et al 2019]. Males and females are equally represented in published reports. Normal stature has been reported, but radiographic features are usually still present. Age-dependent phenotypic manifestations are suggested by apparent reduction in hand and spine features [Savarirayan et al 2000, Elliott et al 2005] and resolution of enlarged capital femoral epiphyses with age [Tüysüz et al 2023].

Nomenclature

In the 2023 revision of the Nosology of Genetic Skeletal Disorders [Unger et al 2023], SMCD is referred to as metaphyseal dysplasia Schmid (MCS), *COL10A1*-related.

Spondylometaphyseal dysplasia (SMD) Japanese type. Affected individuals from one reported family had bowed legs, short stature, coxa vara, metaphyseal changes, and mild platyspondyly [Hasegawa et al 1994]. A heterozygous *COL10A1* pathogenic variant was identified in affected individuals [Ikegawa et al 1998]. Expansion of the clinical phenotype of SMCD to include spinal changes led to the conclusion that SMD Japanese type and SMCD are the same disorder [Savarirayan et al 2000].

Prevalence

The exact prevalence of SMCD is unknown. Incidence has historically been estimated at between three and six individuals per million [Gokhale & Mehta 2005]; however, these figures may be an underestimate [Al Kaissi et al 2018]. More than 150 unrelated individuals with SMCD and a confirmed pathogenic variant in *COL10A1* have been reported.

Genetically Related (Allelic) Disorders

No phenotypes other than SMCD are known to be associated with germline pathogenic variants in *COL10A1*.

Differential Diagnosis

Table 3. Genes of Interest in the Differential Diagnosis of Schmid Metaphyseal Chondrodysplasia

Gene	Disorder	MOI	Clinical Features of Disorder	
			Overlapping w/SMCD	Distinguishing from SMCD
DNAJC21 *EFL1* *SBDS* *SRP54*	Shwachman-Diamond syndrome	AD AR [1]	• Short stature • Metaphyseal widening & irregularities	• Skeletal changes usually milder • Metaphyseal changes usually greatest in ribs • Extraskeletal features: exocrine pancreatic insufficiency, neutropenia, ↑ infections, anemia
MMP9	Metaphyseal anadysplasia, *MMP9*-related [2] (OMIM 613073)	AR	• Genu varum • Metaphyseal dysplasia • Short limbs, limb disproportion	• Apparent in 1st few mos of life but resolves spontaneously w/age • Epiphyseal dysplasia • Generalized osteopenia • Normal stature by adolescence
MMP13	Metaphyseal anadysplasia, *MMP13*-related [2] (OMIM 602111)	AD	• Genu varum • Short limbs, limb disproportion • Severe metaphyseal changes in long bones (irregularities, widening, marginal blurring)	• Apparent in 1st few mos of life but resolves spontaneously w/age • Epiphyseal dysplasia • Generalized osteopenia • Normal stature by adolescence
	Metaphyseal dysplasia Spahr, *MMP13*-related [2] (OMIM 250400)	AR	• Genu varum • Metaphyseal dysplasia • Moderate short stature	• Abnormal ribs • Carpal bone hypoplasia • Iliac crest irregularity in childhood
PTH1R (*PTHR1*)	Metaphyseal dysplasia, Jansen type, *PTH1R*-related [2] (OMIM 156400)	AD	• Genu varum • Short stature • Metaphyseal dysplasia • Waddling gait	• ± dysmorphic features: prominent superciliary arches, exophthalmos • Hypercalcemia, hypercalciuria • Metaphyseal changes more severe • Sclerosis of skull in late adulthood
RMRP	Cartilage-hair hypoplasia (CHH; metaphyseal dysplasia, McKusick type), *RMRP*-related [2] (OMIM 250250)	AR	• Genu varum • Short-limbed short stature • Variable metaphyseal dysplasia	• Coxa vara rarely seen • Extraskeletal features: fine/sparse hair, immune dysfunction, transient macrocytic anemia, Hirschsprung disease • Ligament laxity
RUNX2	Metaphyseal dysplasia w/ maxillary hypoplasia, *RUNX2*-related [2] (OMIM 156510)	AD	• Metaphyseal flaring of long bones • Short stature	• Broad clavicles • Maxillary hypoplasia • Variable brachydactyly

AD = autosomal dominant; AR = autosomal recessive; SMCD = Schmid metaphyseal chondrodysplasia; MOI = mode of inheritance
1. Shwachman-Diamond syndrome (SDS) caused by pathogenic variants in *DNAJC21*, *EFL1*, or *SBDS* is inherited in an autosomal recessive manner. SDS caused by pathogenic variants in *SRP54* is inherited in an autosomal dominant manner.
2. Terminology per 2023 revision of the Nosology of Genetic Skeletal Disorders [Unger et al 2023]

Rickets. Many individuals with SMCD receive an initial diagnosis of vitamin D-deficient rickets, due to a similar age of onset and overlapping clinical features, including genu varum or valgum, waddling gait, and nonspecific metaphyseal and epiphyseal irregularities. In rickets, coxa vara is usually absent and the distal femoral metaphyses are typically more affected. SMCD is distinguished from vitamin D-deficient rickets and metabolic bone disease on the basis of nutritional history and biochemical investigations (see Table 4).

Table 4. Biochemical Findings in Schmid Metaphyseal Chondrodysplasia Compared with Vitamin D-Deficient Rickets and Metabolic Bone Diseases

Disorder	Serum Calcium	Serum Phosphate	Serum PTH	Serum 25-OH Cholecalciferol	Serum 1,25(OH)$_2$ Cholecalciferol
SMCD	Normal	Normal	Normal	Normal	Normal
Vitamin D-deficient rickets	↓	↓	Normal or ↑	↓	Normal or ↑
Hypophosphatemic rickets	Normal	↓ [1]	Normal or ↑	Normal	Normal or ↓
Vitamin D-dependent rickets [2]	Normal or ↓	↓	Normal or ↑	Normal	↓

SMCD = Schmid metaphyseal chondrodysplasia; PTH = parathyroid stimulating hormone
1. Urinary phosphates may be increased.
2. Caused by deficient 25-OHD-1-α-hydroxylase activity

Management

No clinical practice management guidelines for Schmid metaphyseal chondrodysplasia (SMCD) have been published. In the absence of published guidelines, the following recommendations are based on the authors' personal experience managing individuals with this disorder. Management should emphasize multidisciplinary care and a considered approach to surgical intervention when appropriate.

Evaluations Following Initial Diagnosis

To establish the extent of disease and needs in an individual diagnosed with SMCD, the evaluations summarized in Table 5 (if not performed as part of the evaluation that led to the diagnosis) are recommended.

Table 5. Schmid Metaphyseal Chondrodysplasia: Recommended Evaluations Following Initial Diagnosis

System/Concern	Evaluation	Comment
Constitutional	Growth assessment	Consider referral to nutritionist if needed for weight mgmt.
Musculoskeletal	Complete radiographic skeletal survey incl lateral spine radiographs	To assess extent of skeletal malformations & evaluate for lumbar lordosis & scoliosis
	Orthopedic consultation	Eval by specialist experienced in skeletal dysplasia if possible
	Functional & pain assessment	Consider: • Qualification of functional limitations / activities of daily living; • Referral to PT &/or OT.
Psychosocial	• Assessment for adaptive needs due to short stature • Referral to support resources	Environmental modifications to accommodate short stature may be needed, such as: • In school: step stools, lowered light switches, appropriate-height toilets or other means to make them accessible, lower desks, & foot support in front of chairs. All children need to be able to independently escape the building in an emergency. • In adults: pedal extenders for driving, workplace modification (e.g., lower desks, smaller keyboards, step stools, & toilet access)
Genetic counseling	By genetics professionals [1]	To obtain a pedigree & inform affected persons & their families re nature, MOI, & implications of SMCD to facilitate medical & personal decision making

MOI = mode of inheritance; OT = occupational therapist; PT = physical therapist; SMCD = Schmid metaphyseal chondrodysplasia
1. Medical geneticist, certified genetic counselor, certified advanced genetic nurse

Treatment of Manifestations

Supportive care to improve quality of life, maximize function, and reduce complications is recommended. This ideally involves multidisciplinary care by specialists in relevant fields (see Table 6).

Table 6. Schmid Metaphyseal Chondrodysplasia: Treatment of Manifestations

Manifestation/ Concern	Treatment	Considerations/Other
Joint pain, functional limitation	• Referral to orthopedic surgeon for eval • Referral to PT • Referral to OT if indicated • Analgesics, pain specialist referral if appropriate	• Advice on joint-friendly activities (e.g., swimming, cycling) • Counseling re weight optimization where appropriate • Consider need for a mobility device. • Avoidance of physical activities that strain joints, when possible
Lower-limb malalignment, coxa vara, varus deformity [1]	• Referral to orthopedic surgeon • Guided growth surgery • Valgus osteotomy	Varus deformity alone, w/o symptoms, does not usually warrant surgical correction. Corrective osteotomy may be considered in late childhood / adolescence w/indications of: • Progressive or symptomatic varus deformity (e.g., varus angulation >120 degrees) or significant coxa vara; • Triangular fragment in the inferior femoral neck; • Poor or deteriorating function. Surgical options incl: • Guided growth using 8-plates, hemiepiphysiodesis, stapling; • Valgus-producing & derotational osteotomies. No controlled studies comparing outcomes of treatment options have been completed.
Obesity	Referral to nutritionist	• Anticipatory guidance for maintenance of healthy weight • Advice re regular low-impact exercise
Psychosocial	• Referral to support resources • Referral to psychologist	
Short stature	• Environmental or occupational modifications may be needed (e.g., step stools, lower desks). • Consultation w/OT may be beneficial.	Evidence for treatment w/recombinant growth hormone has not been evaluated in children w/SMCD.

OT = occupational therapist; PT = physical therapist; SMCD = Schmid metaphyseal chondrodysplasia
1. Adapted from Al Kaissi et al [2018]

Surveillance

To monitor existing manifestations, the individual's response to supportive care, and the emergence of new manifestations, the evaluations summarized in Table 7 are recommended.

Table 7. Schmid Metaphyseal Chondrodysplasia: Recommended Surveillance

System/Concern	Evaluation	Frequency
Constitutional	Measurement of linear growth, proportions, & weight	Annually or as indicated
Musculoskeletal	• Clinical exam • Referral for orthopedic assessment if indicated • Referral to PT if indicated • Monitoring for surgical complications if indicated	
Psychosocial concerns	Specific attention to mood, affect, & psychosocial stressors when taking history & during physical exam	

PT = physical therapist

Agents/Circumstances to Avoid

Individuals with SMCD should maintain an appropriate weight for height, as obesity increases stress on the joints and may exacerbate joint pain and worsen the impact of genu varum and waddling gait on mobility. Education should include advice regarding weight loss (when appropriate), maintenance of a healthy diet, and regular low-impact exercise.

High-impact exercise or exercise that causes repetitive strain on affected joints should be avoided in favor of joint-friendly low-impact activities, including swimming and biking.

Evaluation of Relatives at Risk

See Genetic Counseling for issues related to testing of at-risk relatives for genetic counseling purposes.

Therapies Under Investigation

Carbamazepine is an FDA-approved medication for use in epilepsy and bipolar affective disorder. Its additional action as a stimulator of autophagy and proteasomal degradation pathways have led to its repurposing as a candidate therapy for conditions caused by retention of misfolded mutated structural proteins, such as SMCD [Hidvegi et al 2010]. In preclinical studies, carbamazepine alleviates endoplasmic reticulum stress (unfolded protein response) caused by the presence of structurally abnormal and misfolded type X collagen in prehypertrophic chondrocytes, restoring growth and improving coxa vara in a validated mouse model of SMCD [Hidvegi et al 2010]. Carbamazepine received orphan drug designation by the European Commission for the treatment of SMCD in September 2016 (EMA/OD/148/16 and EMA/COMP/513538/2016).

Search ClinicalTrials.gov in the US and EU Clinical Trials Register in Europe for access to information on clinical studies for a wide range of diseases and conditions.

Genetic Counseling

Genetic counseling is the process of providing individuals and families with information on the nature, mode(s) of inheritance, and implications of genetic disorders to help them make informed medical and personal decisions. The following section deals with genetic risk assessment and the use of family history and genetic testing to clarify genetic status for family members; it is not meant to address all personal, cultural, or ethical issues that may arise or to substitute for consultation with a genetics professional. —ED.

Mode of Inheritance

Schmid metaphyseal chondrodysplasia (SMCD) is inherited in an autosomal dominant manner.

Risk to Family Members

Parents of a proband

- Approximately half (45%-57%) of individuals diagnosed with SMCD inherited the condition from a parent. The heterozygous parent almost always exhibits features of the condition; however, considerable intrafamilial phenotypic variability is observed in SMCD, and the heterozygous parent may only have mild features [Wu et al 2021, Tüysüz et al 2023].
- Approximately half (43%-55%) of individuals diagnosed with SMCD represent simplex cases (i.e., a single occurrence in a family) and have the disorder as the result of a *de novo COL10A1* pathogenic variant.
- If the proband appears to be the only affected family member, recommendations for the parents of the proband include physical examination and measurement of proportions. Recommendations may also include radiographs (as isolated asymptomatic individuals have been reported with radiographic changes only) and, if a molecular diagnosis has been established in the proband, molecular genetic testing.
- If a molecular diagnosis has been established in the proband, the pathogenic variant identified in the proband is not identified in either parent, and parental identity testing has confirmed biological maternity and paternity, the following possibilities should be considered:
  - The proband has a *de novo* pathogenic variant.
  - The proband inherited a pathogenic variant from a parent with germline (or somatic and germline) mosaicism. Note: Testing of parental leukocyte DNA may not detect all instances of somatic mosaicism and will not detect a pathogenic variant that is present in the germ (gonadal) cells only.
- The family history of some individuals diagnosed with SMCD may appear to be negative because of failure to recognize the disorder in family members, reduced penetrance (reported in rare, isolated cases), or mild radiographic features in an affected parent that have not previously come to medical attention. Therefore, an apparently negative family history cannot be confirmed unless molecular genetic testing has established that neither parent is heterozygous for the pathogenic variant identified in the proband.

Sibs of a proband. The risk to the sibs of the proband depends on the clinical/genetic status of the proband's parents:

- If a parent of the proband is affected and/or is known to have the *COL10A1* pathogenic variant identified in the proband, the risk to the sibs is 50%. Because considerable intrafamilial phenotypic variability is observed in SMCD, a heterozygous sib may have milder or more severe manifestations of SMCD.
- If the proband has a known SMCD-causing variant that cannot be detected in the leukocyte DNA of either parent, the recurrence risk to sibs is estimated to be 1% because of the possibility of parental germline mosaicism [Rahbari et al 2016]. (Note: Recurrence of SMCD in sibs of a proband with an apparently *de novo COL10A1* pathogenic variant has not been reported to date.)
- If the parents are clinically unaffected (based on physical examination, measurement of proportions, and radiographs) but their genetic status is unknown, the risk to the sibs of a proband appears to be low. However, sibs of a proband with clinically unaffected parents are still presumed to be at increased risk for SMCD because of the possibility of reduced penetrance in a heterozygous parent or the possibility of parental germline mosaicism.

Offspring of a proband

- Each child of an individual with SMCD has a 50% chance of inheriting the *COL10A1* pathogenic variant.
- Because many individuals with short stature have reproductive partners with short stature, offspring of individuals with SMCD may be at risk of having double heterozygosity for two dominantly inherited bone growth disorders. The phenotypes of these individuals are distinct from those of the parents, and the affected individuals have serious sequelae and poor outcomes [Flynn & Pauli 2003].

- If the proband and the proband's reproductive partner are both affected with SMCD, each child has a 25% likelihood of average stature (unaffected), a 50% likelihood of having SMCD due to a heterozygous pathogenic variant, and a 25% likelihood of having a more severe SMCD phenotype due to inheritance of biallelic pathogenic variants.
  - Two individuals with biallelic SMCD-causing pathogenic variants and more severe presentations have been reported [Ain et al 2018, Tüysüz et al 2023].
  - Multiple miscarriages have been reported in a large consanguineous family segregating SMCD, suggesting that some homozygous *COL10A1* pathogenic variants may result in early fetal demise [Zhang et al 2018].
- If the proband and the proband's reproductive partner are affected with different dominantly inherited skeletal dysplasias, each child has at conception a 25% likelihood of average stature, a 25% likelihood of having the same skeletal dysplasia as the father, a 25% likelihood of having the same skeletal dysplasia as the mother, and a 25% likelihood of inheriting a pathogenic variant from both parents and being at risk for a more severe blended skeletal phenotype, including fetal demise.

Other family members. The risk to other family members depends on the status of the proband's parents: if a parent has the *COL10A1* pathogenic variant, the parent's family members may be at risk.

Related Genetic Counseling Issues

Family planning

- The optimal time for determination of genetic risk and discussion of the availability of prenatal/preimplantation genetic testing is before pregnancy.
- It is appropriate to offer genetic counseling (including discussion of potential risks to offspring and reproductive options) to young adults who are affected.

Prenatal Testing and Preimplantation Genetic Testing

Once the *COL10A1* pathogenic variant has been identified in an affected family member, prenatal and preimplantation genetic testing are possible.

Differences in perspective may exist among medical professionals and within families regarding the use of prenatal and preimplantation genetic testing. While most health care professionals would consider use of prenatal and preimplantation genetic testing to be a personal decision, discussion of these issues may be helpful.

Resources

GeneReviews staff has selected the following disease-specific and/or umbrella support organizations and/or registries for the benefit of individuals with this disorder and their families. GeneReviews is not responsible for the information provided by other organizations. For information on selection criteria, click here.

- **Genetic and Rare Diseases Information Center (GARD)**
  Metaphyseal chondrodysplasia, Schmid type
- **Little People UK**
  Metaphyseal Chondrodysplasia Schmid Type
- **Short Statured People of Australasia**
  sspa.org.au
- **UCLA International Skeletal Dysplasia Registry (ISDR)**
  Phone: 310-825-8998

International Skeletal Dysplasia Registry

Molecular Genetics

Information in the Molecular Genetics and OMIM tables may differ from that elsewhere in the GeneReview: tables may contain more recent information. —ED.

Table A. Schmid Metaphyseal Chondrodysplasia: Genes and Databases

Gene	Chromosome Locus	Protein	Locus-Specific Databases	HGMD	ClinVar
COL10A1	6q22.1	Collagen alpha-1(X) chain	COL10A1 @ LOVD	COL10A1	COL10A1

Data are compiled from the following standard references: gene from HGNC; chromosome locus from OMIM; protein from UniProt. For a description of databases (Locus Specific, HGMD, ClinVar) to which links are provided, click here.

Table B. OMIM Entries for Schmid Metaphyseal Chondrodysplasia (View All in OMIM)

120110	COLLAGEN, TYPE X, ALPHA-1; COL10A1
156500	METAPHYSEAL CHONDRODYSPLASIA, SCHMID TYPE; MCDS

Molecular Pathogenesis

Type X collagen, encoded by *COL10A1*, is a homotrimer non-fibrillar collagen protein consisting of three α-1(X) chains. Type X collagen is present in the extracellular matrix and expressed exclusively by hypertrophic chondrocytes in the cartilage growth plates of growing bones undergoing endochondral ossification.

Pathogenic variants in *COL10A1* are clustered in the C-terminal non-collagenous (NC1) domain, which contains motifs required for normal assembly of the collagen trimer. Both missense and truncating (frameshift and nonsense) variants in *COL10A1* cause collagen X protein misfolding during protein synthesis, resulting in a failure of trimerization and aggregation within the endoplasmic reticulum (ER) of hypertrophic chondrocytes. Resultant ER stress, activation of the unfolded protein response, and reduced levels of functional type X collagen in the growth plate cause chondrodysplasia and development of the SMCD phenotype [Rajpar et al 2009].

Mechanism of disease causation. Both haploinsufficiency [Bateman et al 2003] and dominant-negative [Chan et al 1998, Wilson et al 2005] mechanisms have been proposed. Recognition of the central role of the unfolded protein response in molecular pathogenesis suggests a neomorphic, dominant-negative model in which the misfolding and accumulation of mutated type X collagen is responsible for the SMCD phenotype.

Chapter Notes

Author Notes

Dr Richmond and Prof Savarirayan are actively involved in clinical research regarding individuals with SMCD. They would be happy to communicate with persons who have any questions regarding diagnosis of SMCD or other considerations.

Acknowledgments

The authors wish to acknowledge the patients, their families, and the clinicians of the multidisciplinary bone dysplasia clinics at the Victorian Clinical Genetics Services, Royal Children's Hospital, Genetic Health Queensland, and Queensland Children's Hospital.

Revision History

- 9 May 2024 (sw) Comprehensive updated posted live
- 21 October 2019 (sw) Review posted live
- 5 July 2019 (rs) Original submission

References

Literature Cited

Ain NU, Mäkitie O, Naz S. Autosomal recessive chondrodysplasia with severe short stature caused by a biallelic COL10A1 variant. J Med Genet. 2018;55:403-7. PubMed PMID: 28830906.

Al Kaissi A, Ghachem MB, Nabil NM, Kenis V, Melchenko E, Morenko E, Grill F, Ganger R, Kircher SG. Schmid's type of metaphyseal chondrodysplasia: diagnosis and management. Orthop Surg. 2018;10:241-6. PubMed PMID: 30027601.

Bateman JF, Freddi S, Nattrass G, Savarirayan R. Tissue-specific RNA surveillance? Nonsense-mediated mRNA decay causes collagen X haploinsufficiency in Schmid metaphyseal chondrodysplasia cartilage. Hum Mol Genet. 2003;12:217-25. PubMed PMID: 12554676.

Bateman JF, Wilson R, Freddi S, Lamandé SR, Savarirayan R. Mutations of COL10A1 in Schmid metaphyseal chondrodysplasia. Hum Mutat. 2005;25:525-34. PubMed PMID: 15880705.

Cammarata-Scalisi F, Matysiak U, Velten T, Callea M, Araque D, Willoughby CE, Galeotti A, Avendaño A. A Venezuelan case of Schmid-type metaphyseal chondrodysplasia with a novel mutation in COL10A1. Mol Syndromol. 2019;10:167-70. PubMed PMID: 31191206.

Chan D, Weng YM, Graham HK, Sillence DO, Bateman JF. A nonsense mutation in the carboxyl-terminal domain of type X collagen causes haploinsufficiency in chmid metaphyseal chondrodysplasia. J Clin Invest. 1998;101:1490-9. PubMed PMID: 9525992.

Chreitah A, Bress F, Aljanati O, Alkilany Z, Mohammed A, Kherbek F. A rare case of SCHMID metaphyseal chondrodysplasia associated with hypothyroidism, growth hormone deficiency and celiac disease: case report. Ann Med Surg (Lond). 2023;85:4045-9. PubMed PMID: 37554853.

de França M, de Faria Soares MF, Luce ALP, Perrone E. Schmid metaphyseal chondrodysplasia: an example of radiology guidance to molecular diagnosis. Radiol Case Rep. 2020;15:2554-6. PubMed PMID: 33082897.

Elliott AM, Field FM, Rimoin DL, Lachman RS. Hand involvement in Schmid metaphyseal chondrodysplasia. Am J Med Genet A. 2005;132A:191-3. PubMed PMID: 15578582.

Flynn MA, Pauli RM. Double heterozygosity in bone growth disorders: four new observations and review. Am J Med Genet A. 2003;121A:193-208. PubMed PMID: 12923858.

Gokhale S, Mehta S. Schmid type metaphyseal chondrodysplasia. Indian Pediatr. 2005;42:1252. PubMed PMID: 16424569.

Hasegawa T, Kozlowski K, Nishimura G, Hara H, Hasegawa Y, Aso T, Koto S, Nagai T, Tsuchiya Y. Japanese type of spondylo-metaphyseal dysplasia. Pediatr Radiol. 1994;24:194-7. PubMed PMID: 7936797.

Hidvegi T, Ewing M, Hale P, Dippold C, Beckett C, Kemp C, Maurice N, Mukherjee A, Goldbach C, Watkins S, Michalopoulos G, Perlmutter DH. An autophagy-enhancing drug promotes degradation of mutant alpha1-antitrypsin Z and reduces hepatic fibrosis. Science. 2010;329:229-32. PubMed PMID: 20522742.

Ikegawa S, Nishimura G, Nagai T, Hasegawa T, Ohashi H, Nakamura Y. Mutation of the type X collagen gene (COL10A1) causes spondylometaphyseal dysplasia. Am J Hum Genet. 1998;63:1659-62. PubMed PMID: 9837818.

Kong L, Shi L, Wang W, Zuo R, Wang M, Kang Q. Identification of two novel COL10A1 heterozygous mutations in two Chinese pedigrees with Schmid-type metaphyseal chondrodysplasia. BMC Med Genet. 2019;20:200. PubMed PMID: 31856751.

Lachman RS, Rimoin DL, Spranger J. Metaphyseal chondrodysplasia, Schmid type. Clinical and radiographic delineation with a review of the literature. Pediatr Radiol. 1988;18:93-102. PubMed PMID: 3281118.

Landrum MJ, Lee JM, Riley GR, Jang W, Rubinstein WS, Church DM, Maglott DR. ClinVar: public archive of relationships among sequence variation and human phenotype. Nucleic Acids Res. 2014;42:D980-5. PubMed PMID: 24234437.

Mäkitie O, Susic M, Ward L, Barclay C, Glorieux FH, Cole WG. Schmid type of metaphyseal chondrodysplasia and COL10A1 mutations--findings in 10 patients. Am J Med Genet A. 2005:137A:241-8. PubMed PMID: 16088909.

Park H, Hong S, Cho SI, Cho TJ, Choi IH, Jin DK, Sohn YB, Park SW, Cho HH, Cheon JE, Kim SY, Kim JY, Park SS, Seong MW. Case of mild Schmid-type metaphyseal chondrodysplasia with novel sequence variation involving an unusual mutational site of the COL10A1 gene. Eur J Med Genet. 2015;58:175-9. PubMed PMID: 25542771.

Rahbari R, Wuster A, Lindsay SJ, Hardwick RJ, Alexandrov LB, Turki SA, Dominiczak A, Morris A, Porteous D, Smith B, Stratton MR, Hurles ME, et al. Timing, rates and spectra of human germline mutation. Nat Genet. 2016;48:126-33. PubMed PMID: 26656846.

Rajpar MH, McDermott B, Kung L, Eardley R, Knowles L, Heeran M, Thornton DJ, Wilson R, Bateman JF, Poulsom R, Arvan P, Kadler KE, Briggs MD, Boot-Handford RP. Targeted induction of endoplasmic reticulum stress induces cartilage pathology. PLoS Genet. 2009;5:e1000691. PubMed PMID: 19834559.

Richards S, Aziz N, Bale S, Bick D, Das S, Gastier-Foster J, Grody WW, Hegde M, Lyon E, Spector E, Voelkerding K, Rehm HL; ACMG Laboratory Quality Assurance Committee. Standards and guidelines for the interpretation of sequence variants: a joint consensus recommendation of the American College of Medical Genetics and Genomics and the Association for Molecular Pathology. Genet Med. 2015;17:405-24. PubMed PMID: 25741868.

Savarirayan R, Cormier-Daire V, Lachman RS, Rimoin DL. Schmid type metaphyseal chondrodysplasia: a spondylometaphyseal dysplasia identical to the "Japanese" type. Pediatr Radiol. 2000;30:460-3. PubMed PMID: 10929364.

Stenson PD, Mort M, Ball EV, Chapman M, Evans K, Azevedo L, Hayden M, Heywood S, Millar DS, Phillips AD, Cooper DN. The Human Gene Mutation Database (HGMD®): optimizing its use in a clinical diagnostic or research setting. Hum Genet. 2020;139:1197-207. PubMed PMID: 32596782.

Tüysüz B, Kasap B, Sarıtaş M, Alkaya DU, Bozlak S, Kıykım A, Durmaz A, Yıldırım T, Akpınar E, Apak H, Vural M. Natural history and genetic spectrum of the Turkish metaphyseal dysplasia cohort, including rare types caused by biallelic COL10A1, COL2A1, and LBR variants. Bone. 2023;167:116614. PubMed PMID: 36400164.

Unger S, Ferreira CR, Mortier GR, Ali H, Bertola DR, Calder A, Cohn DH, Cormier-Daire V, Girisha KM, Hall C, Krakow D, Makitie O, Mundlos S, Nishimura G, Robertson SP, Savarirayan R, Sillence D, Simon M, Sutton VR, Warman ML, Superti-Furga A. Nosology of genetic skeletal disorders: 2023 revision. Am J Med Genet A. 2023;191:1164-209. PubMed PMID: 36779427.

Wilson R, Freddi S, Chan D, Cheah KS, Bateman JF. Misfolding of collagen X chains harboring Schmid metaphyseal chondrodysplasia mutations results in aberrant disulfide bond formation, intracellular retention, and activation of the unfolded protein response. J Biol Chem. 2005;280:15544-52. PubMed PMID: 15695517.

Wu H, Wang S, Li G, Yao Y, Wang N, Sun X, Fang L, Jiang X, Zhao J, Wang Y, Xu C. Characterization of a novel COL10A1 variant associated with Schmid-type metaphyseal chondrodysplasia and a literature review. Mol Genet Genomic Med. 2021;9:e1668. PubMed PMID: 33764685.

Zhang C, Liu J, Iqbal F, Lu Y, Mustafa S, Bukhari F, Lou H, Fu R, Wu Z, Yang X, Bukhari I, Aslam M, Xu S. A missense point mutation in COL10A1 identified with whole-genome deep sequencing in a 7-generation Pakistan dwarf family. Heredity (Edinb). 2018;120:83-9. PubMed PMID: 29234170.

License

GeneReviews® chapters are owned by the University of Washington. Permission is hereby granted to reproduce, distribute, and translate copies of content materials for noncommercial research purposes only, provided that (i) credit for source (http://www.genereviews.org/) and copyright (© 1993-2024 University of Washington) are included with each copy; (ii) a link to the original material is provided whenever the material is published elsewhere on the Web; and (iii) reproducers, distributors, and/or translators comply with the GeneReviews® Copyright Notice and Usage Disclaimer. No further modifications are allowed. For clarity, excerpts of GeneReviews chapters for use in lab reports and clinic notes are a permitted use.

For more information, see the GeneReviews® Copyright Notice and Usage Disclaimer.

For questions regarding permissions or whether a specified use is allowed, contact: admasst@uw.edu.