



Molybdenum Cofactor Deficiency

Albert Misko, MD, PhD,¹ Karishma Mahtani, BSc,² Jessica Abbott,² Guenter Schwarz,³ and Paldeep Atwal, MD²

Created: December 2, 2021; Revised: February 2, 2023.

Summary

Clinical characteristics

Molybdenum cofactor deficiency (MoCD) represents a spectrum, with some individuals experiencing significant signs and symptoms in the neonatal period and early infancy (termed early-onset or severe MoCD) and others developing signs and symptoms in childhood or adulthood (termed late-onset or mild MoCD). Individuals with early-onset MoCD typically present in the first days of life with severe encephalopathy, including refractory seizures, opisthotonos, axial and appendicular hypotonia, feeding difficulties, and apnea. Head imaging may demonstrate loss of gray and white matter differentiation, gyral swelling, sulci injury (typically assessed by evaluating the depth of focal lesional injury within the sulci), diffusely elevated T₂-weighted signal, and panlobar diffusion restriction throughout the forebrain and midbrain with relative sparing of the brain stem. Prognosis for early-onset MoCD is poor, with about 75% succumbing in infancy to secondary complications of their neurologic disability (i.e., pneumonia).

Late-onset MoCD is typically characterized by milder symptoms, such as acute neurologic decompensation in the setting of infection. Episodes vary in nature but commonly consist of altered mental status, dystonia, choreoathetosis, ataxia, nystagmus, and fluctuating hypotonia and hypertonia. These features may improve after resolution of the inciting infection or progress in a gradual or stochastic manner over the lifetime. Brain imaging may be normal or may demonstrate T₂-weighted hyperintense or cystic lesions in the globus pallidus, thinning of the corpus callosum, and cerebellar atrophy.

Diagnosis/testing

The diagnosis of molybdenum cofactor deficiency is established by identification of biallelic pathogenic variants in *GPHN*, *MOCS1*, *MOCS2*, or *MOCS3*, or when unavailable, of significantly reduced activity of the enzyme sulfite oxidase in cultured fibroblasts. However, due to low expression of sulfite oxidase in fibroblasts, differentiation between total and partial loss of enzyme activity is difficult to discern.

Author Affiliations: 1 Department of Neurology, Massachusetts General Hospital, Harvard Medical School, Boston, Massachusetts; Email: amisko@mgh.harvard.edu. 2 Atwal Clinic: Genomic & Personalized Medicine Palm Beach, Florida; Email: k.mahtani@smd18.qmul.ac.uk; Email: jessicaabbott113@gmail.com; Email: dra@atwalclinic.com. 3 Institute of Biochemistry, Department of Chemistry & Center for Molecular Medicine Cologne University, Cologne, Germany; Email: gschwarz@uni-koeln.de.

Management

Targeted therapies: In those with *MOCS1*-related MoCD (MoCD type A), fosdenopterin (NULIBRY®) daily infusion through an indwelling catheter (dose based on weight and age; each vial contains 9.5 mg) may be considered, but must be initiated in a very short window after symptom manifestation to achieve maximum benefit. Affected individuals (all subtypes) are often placed on a cysteine-restricted diet, which typically includes low protein intake with restriction of whole natural protein.

Supportive care: Feeding therapy and consideration of gastrostomy tube placement in those with concerns about aspiration and/or persistent feeding issues. Thiamine supplementation (1.2 mg/day for infants; 50 mg/1x/day to 100 mg/2x/day for children/adolescents) for those with thiamine deficiency. Magnesium supplementation and standardized migraine prophylactics for those with headaches. Standard treatment for seizures, developmental delay / intellectual disability, spasticity/dystonia, and ectopia lentis.

Surveillance: Routine measurement of essential amino acids in those on a low-cysteine low-protein diet. Assessment for new or progressive neurologic manifestations, measurement of growth parameters and head circumference, monitoring of developmental milestones, and assessment of mobility and self-help skills at each visit. At least annual ophthalmology evaluations. Neuropsychological testing and standardized quality-of-life assessments as clinically indicated.

Agents/circumstances to avoid: Valproate should be avoided if possible, as sulfite intoxication impairs mitochondrial function in vitro. For individuals on fosdenopterin (NULIBRY®), direct sunlight and artificial UV light exposure (i.e., UVA or UVB phototherapy) should be avoided.

Evaluation of relatives at risk: For at-risk newborn sibs in whom prenatal testing was not performed, metabolic treatment should be initiated immediately and continued until such a time as the diagnosis has been excluded through molecular genetic testing or by measurement of serum uric acid and urinary: sulfite, s-sulfocysteine, xanthine, hypoxanthine, and uric acid.

Genetic counseling

Molybdenum cofactor deficiency (MoCD) is inherited in an autosomal recessive manner. If both parents are known to be heterozygous for an MoCD-causing pathogenic variant, each sib of an affected individual has at conception a 25% chance of being affected, a 50% chance of being an asymptomatic carrier, and a 25% chance of being unaffected and not a carrier. Once the MoCD-causing pathogenic variants have been identified in an affected family member, carrier testing for at-risk relatives, prenatal testing for a pregnancy at increased risk, and preimplantation genetic testing are possible.

Diagnosis

Formal clinical diagnostic criteria for molybdenum cofactor deficiency have not been established.

Suggestive Findings

Molybdenum cofactor deficiency (MoCD) typically manifests in the neonatal period and **should be suspected** in individuals with the following clinical, supportive laboratory, brain MRI, and family history findings.

Clinical findings

- Acute encephalopathy
- Intractable seizures
- Poor feeding
- Hyperekplexia (excessive startle reaction to loud noises, touch, or movement)

- Apnea
- Pyramidal and extrapyramidal dysfunction
- Severe developmental delay / intellectual disability
- Acquired microcephaly
- Nonspecific craniofacial dysmorphic features (See Clinical Characteristics.)
- Ophthalmologic manifestations (e.g., ectopia lentis)
- Variable course of stochastic regression, sometimes around infection

Suggestive laboratory findings

- Elevated taurine and decreased cystine concentrations on plasma amino acid analysis
- Decreased plasma total homocysteine concentration
- Elevated xanthine and hypoxanthine concentrations on urine pyrimidine analysis
- Decreased plasma uric acid concentration
- Elevated urine levels of S-sulfocysteine and thiosulfate on targeted measurement

Note: Because elevations of these metabolites individually are not entirely specific to molybdenum cofactor deficiency, follow-up testing is required to establish or rule out the diagnosis of molybdenum cofactor deficiency (see Establishing the Diagnosis).

Brain MRI findings

- **Acute**
 - Diffusion restriction and elevated T₂-weighted signal throughout the cortical ribbon, subcortical white matter, basal ganglia, midbrain, and to a lesser extent the pons and medulla
 - Gyral swelling
 - In some affected individuals in the first days of life, imaging features suggestive of prenatal-associated injury
- **Chronic**
 - Atrophy of the cortex, subcortical white matter, basal ganglia, corpus callosum, and/or cerebellum
 - High T₁-weighted signal in the basal ganglia
 - Cavitary leukomalacia
 - Ulegyria (mushroom-shaped morphology of gyri resulting from injury and contraction of sulci; also seen in neonatal hypoxic ischemic injury)
- **MR spectroscopy**
 - Lactate doublet
 - Glutamine-glutamate (Glx) peak

Family history is consistent with autosomal recessive inheritance (e.g., affected sibs and/or parental consanguinity). Absence of a positive family history does not preclude the diagnosis.

Establishing the Diagnosis

The diagnosis of molybdenum cofactor deficiency **is established** by identification of biallelic pathogenic (or likely pathogenic) variants in *GPHN*, *MOCS1*, *MOCS2*, or *MOCS3* (Table 1), or when unavailable, of significantly reduced activity of the enzyme sulfite oxidase in cultured fibroblasts. However, due to low expression of sulfite oxidase in fibroblasts, differentiation between total and partial loss of enzyme activity is difficult to discern. Because of its high sensitivity, molecular genetic testing typically obviates the need for enzymatic testing and thus is the preferred diagnostic test for MoCD.

Note: (1) Per ACMG/AMP variant interpretation guidelines, the terms "pathogenic variant" and "likely pathogenic variant" are synonymous in a clinical setting, meaning that both are considered diagnostic and can

be used for clinical decision making [Richards et al 2015]. Reference to "pathogenic variants" in this *GeneReview* is understood to include any likely pathogenic variants. (2) Identification of biallelic variants of uncertain significance (or of one known pathogenic variant and one variant of uncertain significance) does not establish or rule out the diagnosis.

Molecular genetic testing approaches can include **gene-targeted testing** (multigene panel) and **comprehensive genomic testing** (exome sequencing, exome array, genome sequencing) depending on the phenotype.

Gene-targeted testing requires that the clinician determine which gene(s) are likely involved, whereas genomic testing does not. Individuals with the distinctive findings described in Suggestive Findings are likely to be diagnosed using gene-targeted testing (see Option 1), whereas those in whom the diagnosis of MoCD has not been considered are more likely to be diagnosed using genomic testing (see Option 2).

Option 1

When the phenotypic and laboratory findings suggest the diagnosis of MoCD, molecular genetic testing typically includes use of a **multigene panel**.

A neonatal seizure, epilepsy, or neurodegenerative multigene panel that includes *GPHN*, *MOCS1*, *MOCS2*, *MOCS3*, and other genes of interest (see Differential Diagnosis) is most likely to identify the genetic cause of the condition while limiting identification of variants of uncertain significance and pathogenic variants in genes that do not explain the underlying phenotype. Note: (1) The genes included in the panel and the diagnostic sensitivity of the testing used for each gene vary by laboratory and are likely to change over time. (2) Some multigene panels may include genes not associated with the condition discussed in this *GeneReview*. (3) In some laboratories, panel options may include a custom laboratory-designed panel and/or custom phenotype-focused exome analysis that includes genes specified by the clinician. (4) Methods used in a panel may include sequence analysis, deletion/duplication analysis, and/or other non-sequencing-based tests.

For an introduction to multigene panels click [here](#). More detailed information for clinicians ordering genetic tests can be found [here](#).

Option 2

When the phenotype is indistinguishable from other inherited disorders characterized by neonatal seizures, epilepsy, or neurodegeneration, **comprehensive genomic testing** (which does not require the clinician to determine which gene is involved) may be considered. **Exome sequencing** is most commonly used; **genome sequencing** is also possible.

For an introduction to comprehensive genomic testing click [here](#). More detailed information for clinicians ordering genomic testing can be found [here](#).

Table 1. Molecular Genetic Testing Used in Molybdenum Cofactor Deficiency (MoCD)

Gene ^{1, 2}	Proportion of MoCD Attributed to Pathogenic Variants in Gene	Proportion of Pathogenic Variants ³ Detectable by Method	
		Sequence analysis ⁴	Gene-targeted deletion/duplication analysis ⁵
<i>GPHN</i> ⁶	~4%	>95% ⁷	Unknown ⁸
<i>MOCS1</i> ⁹	~49%	>95% ⁷	Unknown ¹⁰
<i>MOCS2</i> ¹¹	~45%	>95% ⁷	Unknown ¹⁰

Table 1. continued from previous page.

Gene ^{1, 2}	Proportion of MoCD Attributed to Pathogenic Variants in Gene	Proportion of Pathogenic Variants ³ Detectable by Method	
		Sequence analysis ⁴	Gene-targeted deletion/duplication analysis ⁵
<i>MOCS3</i> ¹²	2%	>95% ⁷	Unknown ¹⁰

1. Genes are listed in alphabetic order.

2. See Table A. Genes and Databases for chromosome locus and protein.

3. See Molecular Genetics for information on variants detected in this gene.

4. Sequence analysis detects variants that are benign, likely benign, of uncertain significance, likely pathogenic, or pathogenic. Variants may include missense, nonsense, and splice site variants and small intragenic deletions/insertions; typically, exon or whole-gene deletions/duplications are not detected. For issues to consider in interpretation of sequence analysis results, click [here](#).

5. Gene-targeted deletion/duplication analysis detects intragenic deletions or duplications. Methods used may include a range of techniques such as quantitative PCR, long-range PCR, multiplex ligation-dependent probe amplification (MLPA), and a gene-targeted microarray designed to detect single-exon deletions or duplications.

6. Phenotype is sometimes referred to as molybdenum cofactor deficiency type C.

7. Percentages based on number of individuals reported in the literature; see also Misko et al [2020].

8. A common deleted area within exons 3-5 in the G domain of the protein encoded by *GPHN*, suggesting this area as key to protein function; however, no data on detection rate of gene-targeted deletion/duplication analysis for this gene are available.

9. Sometimes referred to as molybdenum cofactor deficiency type A

10. No data on detection rate of gene-targeted deletion/duplication analysis are available.

11. Sometimes referred to as molybdenum cofactor deficiency type B

12. To date, the only individual with pathogenic variants in this gene had mild features of MoCD (see Phenotype Correlations by Gene). Because of the rarity of this cause of MoCD, disease related to this gene has not been given a further phenotypic letter designation.

Clinical Characteristics

Clinical Description

More than 100 individuals with a molybdenum cofactor deficiency have been identified [Misko et al 2020; Authors, personal observations]. As is the case for many inborn errors of metabolism, MoCD represents a spectrum, with some individuals experiencing significant signs and symptoms in the neonatal period and early infancy (termed early-onset or severe MoCD) and others developing signs and symptoms in childhood or adulthood (termed late-onset or mild MoCD).

Early-Onset or Severe MoCD

Affected individuals typically present in the first days of life (median 1 day; range 1-50 days) with severe encephalopathy, including refractory seizures, opisthotonos, axial hypotonia and appendicular hypertonia, feeding difficulties, and apnea [Misko et al 2020]. Prenatal and birth histories are usually unremarkable, though up to 40% of affected individuals have Apgar scores <7 at one minute with subsequent improvement at five and ten minutes. Lack of a sentinel event in the perinatal period and a delay between birth and the onset of symptoms help distinguish MoCD from neonatal hypoxic ischemic injury. Table 2 lists the most common findings of early-onset MoCD.

Table 2. Select Features of Early-Onset or Severe Molybdenum Cofactor Deficiency

Feature	% of Persons w/Feature	Comment
Encephalopathy	100%	
DD/ID	100%	
Neonatal seizures	93%	Multiple semiologies, incl epileptic spasms in ~4% of affected persons; often refractory to ASM

Table 2. continued from previous page.

Feature	% of Persons w/Feature	Comment
Feeding difficulties	66%	At onset of symptoms
Craniofacial dysmorphic features	61%	May incl enophthalmos, prominent cheeks, coarse facies, & bitemporal narrowing
Appendicular hypertonia	59%	Rigidity may be present at onset of symptoms & persist throughout disease course; spasticity emerges later & progressively worsens.
Acquired microcephaly	45%	
Axial hypotonia	41%	Presents early in disease course w/head lag & axial hypotonia
Ectopia lentis	16%	Typically develops later in disease course
Hyperekplexia	9%	In classic hyperekplexia, affected newborns can have significant hypertonia.

ASM = anti-seizure medication; DD = developmental delay; ID = intellectual disability

Neurologic signs. MoCD primarily affects the central nervous system without involvement of the peripheral nervous system. Affected individuals develop severe psychomotor impairment, spastic quadriplegia, and extrapyramidal rigidity over the first months of life. The severity of cognitive and motor impairment is consistent with the catastrophic degeneration of the cortical and subcortical structures in virtually all affected individuals. Affected individuals may also display nystagmus, myoclonic jerks, or hyperekplexia (excessive startle reaction to loud noises, touch, or movement) with or without concurrent seizures [Macaya et al 2005, Zaki et al 2016]. Manifestations of neonatal hyperekplexia include abnormal responses to auditory, visual, and somatosensory stimuli such as exaggerated startle response and tonic spasms. The tonic spasms may mimic generalized tonic seizures, resulting in apnea without electrographic seizure.

Brain MRI findings. Acute findings in the neonatal period closely resemble those observed in individuals with hypoxic-ischemic injury. Loss of gray and white matter differentiation, gyral swelling, sulci injury (typically assessed by evaluating the depth of the focal lesion within the sulci), diffusely elevated T₂-weighted signal, and panlobar diffusion restriction are present throughout the forebrain and midbrain, with relative sparing of the brain stem. Prominent lactate doublets and a glutamine/glutamate peak are frequently observed on MR spectroscopy in affected areas. Over the course of several weeks, severe cortical atrophy, cystic leukomalacia, and degeneration of the basal ganglia develop. In contrast to hypoxic-ischemic injury, diffusion restriction is still present in areas of remaining parenchyma through the chronic phase of disease. Progressive thinning of the corpus callosum and cerebellar atrophy also develop with time [Vijayakumar et al 2011]. See also Suggestive Findings, **Brain MRI findings**.

It is particularly important to distinguish those with MoCD from those with hypoxic ischemic encephalopathy (HIE) because of the potential use of fosdenopterin (NULIBRY®) for treatment of *MOCS1*-related MoCD (see Management, Targeted Therapies). Radiographic features present in those with MoCD but typically absent in those with HIE include the following:

- Mega cisterna magna or Dandy-Walker malformation
- Hypoplastic/atrophic corpus callosum or cerebellum
- Evidence of prenatal brain degeneration present at the time of birth (cortical atrophy, cystic leukomalacia, or basal ganglia degeneration).

While these features are inconsistently present across all individuals with early-onset or severe MoCD, their presence should suggest MoCD in the right clinical setting. Absence of these findings does not exclude the diagnosis of MoCD.

Seizures and EEG findings. Seizures are the most frequent initial cardinal sign in infants with early-onset MoCD. Affected individuals typically develop seizures within two weeks of birth. Seizures are typically refractory to anti-seizure medication, but gradually decrease in frequency over time [Macaya et al 2005, Zaki et al 2016].

- A variety of seizure semiologies have been reported including subtle, clonic, tonic myoclonic, multifocal, and partial migrating.
- A case of epileptic spasms diagnosed at 26 days of life has also been described [Stence et al 2013]. Accompanying EEG changes for those with infantile spasms may include burst suppression, multifocal epileptiform discharges, unilateral discharges, generalized or focal slowing, and hypsarrhythmia.
- The diversity of reported semiologies suggests that seizures in those with typical MoCD are secondary to the diffuse cortical degeneration seen on ancillary brain imaging and not specific to the underlying pathophysiology.

Developmental findings. All affected individuals develop severe cognitive impairment and spastic quadriplegia that parallels progressive degeneration of the forebrain and cerebellum. Affected individuals typically demonstrate minimal cognitive function or interaction with their environment. Gross and fine motor development are severely impaired, with most affected individuals unable to maintain head or truncal posture. Affected individuals typically do not develop verbal language and have limited or no receptive language capacity. As the brain stem is relatively preserved, brain stem function typically remains intact.

Respiratory. Apneic episodes during the first days of life have been frequently reported in individuals with typical MoCD. Though the duration and severity of episodes are largely unknown, they are likely consistent with episodes of central apnea secondary to the severe neurodegenerative phenotype. Alternatively, apneic episodes could be a manifestation of seizures. As commonly encountered in other severe neurodegenerative disorders, individuals with severe motor impairments may develop aspiration pneumonia as a consequence of the inability to protect the airway. Aspiration pneumonia may also occur secondary to gastroesophageal reflux disease or pyloric stenosis.

Growth/feeding. Head circumference is typically normal at birth but acquired microcephaly develops as a result of progressive brain degeneration. Dysphagia and aspiration may develop, and a swallow study should be pursued if clinical suspicion arises. Given the progressive neurodegenerative course of MoCD, a gastrostomy tube may be necessary on a permanent basis to prevent aspiration and to support feeding and nutrition.

Although structural malformations of the gastrointestinal tract are not typically seen in association with MoCD, pyloric stenosis has been diagnosed in two individuals with MoCD and in two individuals with isolated sulfite oxidase deficiency, suggesting a possible connection with sulfite intoxication [Parini et al 1997, Tezel et al 2012].

Ophthalmologic findings. Approximately 16% of affected individuals develop ectopia lentis, which presents later in the course of disease (age at identification: median 1 year; range 3 months to 8 years). Other rarer findings may include enophthalmos, microphthalmia, and spherophakia.

Nonspecific dysmorphic features. Affected individuals have dysmorphic facial features that include coarse facial features, bitemporal narrowing, long face, prominent cheeks, widely spaced eyes, enophthalmos, frontal bossing, long palpebral fissures, long philtrum, small nose, and thick vermilion of the upper and lower lips. These features are usually evident in the neonatal period.

Prognosis is poor: about 75% of affected individuals succumb in infancy to secondary complications of their neurologic disability (i.e., pneumonia). Fosdenopterin (NULIBRY[®]) or recombinant cyclic pyranopterin monophosphate was reported to reduce the risk of death in individuals with *MOCS1*-related MoCD by 82% compared to untreated, genotype-matched, historical controls (HR = 0.18, 95% CI 0.04, 0.72) (see NULIBRY[®],

[prescribing information](#); see also Table 6 and Management, Targeted Therapies). Fosdenopterin is the first FDA-approved drug that alters mortality in individuals with *MOCS1*-related MoCD.

Late-Onset or Mild MoCD

A less severe phenotype with late-onset presentation (1 year; range 4 months to 23 years) and milder symptoms has been recognized (see Table 3).

Table 3. Select Features of Late-Onset or Mild Molybdenum Cofactor Deficiency

Feature	Frequency of Feature	Comment
Appendicular hypertonia	67%	
Axial hypotonia	58%	
Ectopia lentis	42%	Develops later in disease course
Choreoathetosis	25%	
Dystonia	33%	
Seizures	33%	
Ataxia	17%	

Neurologic findings. Acute neurologic decompensation in the setting of infection may be the first sign of MoCD and may prompt an evaluation that leads to the diagnosis. Episodes vary in nature but commonly consist of altered mental status, dystonia, choreoathetosis, ataxia, nystagmus, and fluctuating hypotonia and hypertonia. These features may improve after resolution of the inciting infection or progress in a gradual or stochastic manner over the lifetime [Misko et al 2020]. Headaches have also been observed and anecdotally reported; the nature of these headaches is poorly understood [Authors, personal observation].

Brain imaging. T₂-weighted hyperintense or cystic lesions in the globus pallidus, thinning of the corpus callosum, and cerebellar atrophy are frequently reported in milder phenotypic variants, even outside of an inciting event; however, brain MRI may also be normal. Those who experience progressive neurologic symptoms may also show accompanying cerebral atrophy. Similar to what has been described in the early-onset or severe form, atrophy of the corpus callosum and mega cisterna magna may also be present.

Seizures are less common compared to those who have early-onset or severe MoCD. Reported semiologies include tonic-clonic, partial, and atonic. The natural history of seizures and response to anti-seizure medication is poorly understood in those with late-onset or mild MoCD.

Developmental. These individuals may have a history of normal cognitive development or mild developmental delay with hypotonia before first coming to medical attention, which frequently occurs as a result of acute neurologic deterioration.

Growth/feeding. Dysphagia has been reported in a few individuals with late-onset MoCD; a detailed understanding of the onset, duration, and severity of dysphagia is not available.

Ophthalmologic findings. Ectopia lentis may develop. The timing of onset is uncertain; reports have ranged from age six months to eight years at the time of diagnosis.

Prognosis for this form of MoCD is poorly understood. Longitudinal natural history studies are needed to better define outcomes.

Phenotype Correlations by Gene

No clear phenotype correlations have been observed. However, to date the only individuals described with a pathogenic variant in *MOCS3* had the late-onset or mild form of MoCD due to partial loss of *MOCS3* function.

Nomenclature

Sometimes MoCD is divided into subtypes based on the causative gene. This has become more important now that a targeted treatment is available for one subtype (see Management, Targeted Therapies). The subtypes are denoted as follows: *MOCS1*-related MoCD is type A, *MOCS2*-related MoCD is type B, and *GPHN*-related MoCD is type C. Because of the paucity of known affected individuals with *MOCS3*-related MoCD, this has not yet been given another subtype designation.

Genotype-Phenotype Correlations

No genotype-phenotype correlations are known to be associated with biallelic pathogenic variants in any gene associated with MoCD.

Prevalence

The global incidence of MoCD is estimated at 1:100,000-1:200,000 live births. Like many other rare diseases, the true incidence remains uncertain, as MoCD is likely underdiagnosed.

Genetically Related (Allelic) Disorders

At present, no phenotypes other than those discussed in this *GeneReview* are known to be associated with biallelic pathogenic variants in *GPHN*, *MOCS1*, *MOCS2*, or *MOCS3*.

Differential Diagnosis

Early-Onset or Severe Molybdenum Cofactor Deficiency

Table 4. Genes of Interest in the Differential Diagnosis of Early-Onset or Severe Molybdenum Cofactor Deficiency

Gene(s)	Disorder	MOI	Clinicoradiographic Findings	Laboratory Findings / Comment
<i>SUOX</i>	Isolated sulfite oxidase deficiency (ISOD)	AR	Identical to MoCD	<ul style="list-style-type: none"> • ↑ plasma taurine • ↑ urinary thiosulfate & S-sulfocysteine • ↓↓ plasma levels of total homocysteine & cystine <p>Unlike MoCD, serum uric acid levels are normal in ISOD – as are urine xanthine & hypoxanthine levels.</p>
<i>ALDH7A1</i>	Pyridoxine-dependent epilepsy (PDE)	AR	<ul style="list-style-type: none"> • Neonates w/pyridoxine-responsive seizures refractory to ASM & encephalopathy • Thinning of corpus callosum & mega cisterna magna on brain MRI <p>Unlike MoCD, PDE is not assoc w/ widespread diffusion restriction on brain MRI.</p>	<ul style="list-style-type: none"> • ↑ alpha-amino adipic semialdehyde in urine & plasma¹ • ↑ pipelicolic acid in urine & CSF <p>Unlike MoCD, sulfur metabolite labs are normal in PDE.</p>

Table 4. continued from previous page.

Gene(s)	Disorder	MOI	Clinicoradiographic Findings	Laboratory Findings / Comment
<i>PNPO</i>	Pyridoxal phosphate-responsive epilepsy (See PNPO Deficiency .)	AR	Neonates w/pyridoxal-5' phosphate-responsive seizures refractory to ASM & encephalopathy	<ul style="list-style-type: none"> • ↑ plasma lactate • Hypoglycemia • Normal to ↑ plasma glycine • Normal to ↑ plasma threonine • ↓ plasma arginine
<i>PLPBP</i> (<i>PROSC</i>)	Early-onset vitamin B ₆ -dependent epilepsy (See PLPBP Deficiency .)	AR	Neonates w/pyridoxine-responsive seizures refractory to ASM & encephalopathy	<ul style="list-style-type: none"> • ↑ plasma lactate • Metabolic acidosis

AD = autosomal dominant; AR = autosomal recessive; ASM = anti-seizure medication; ID = intellectual disability; MoCD = molybdenum cofactor deficiency; MOI = mode of inheritance; XL = X-linked

1. It should be noted that alpha-amino adipic semialdehyde excretion has been detected in some individuals with molybdenum cofactor deficiency and isolated sulfite oxidase deficiency [Mills et al 2012, Struys et al 2012].

Late-Onset or Mild Molybdenum Cofactor Deficiency

The differential diagnosis of late onset or mild molybdenum cofactor deficiency includes acquired conditions (e.g., cerebral palsy) and hereditary disorders of basal ganglia and development with extrapyramidal signs and developmental delay including juvenile-onset [Huntington disease](#), early-onset [Parkinson disease](#), Lesch-Nyan disease (see [HPRT1 Disorders](#)), progressive supranuclear palsy (OMIM 601104), and [Wilson disease](#).

Management

When molybdenum cofactor deficiency (MoCD) is suspected during the diagnostic evaluation (i.e., due to laboratory findings consistent with the condition), metabolic treatment should be initiated immediately. If laboratory findings and/or clinical presentation are highly suggestive, treatment should be initiated prior to the availability of confirmatory genetic testing.

No consensus clinical treatment guidelines have been published.

Evaluations Following Initial Diagnosis

To establish the extent of disease and needs in an individual diagnosed with MoCD, the evaluations summarized in Table 5 (if not performed as part of the evaluation that led to the diagnosis) are recommended.

Table 5. Recommended Evaluations Following Initial Diagnosis of Molybdenum Cofactor Deficiency

Evaluation	Comment
Consultation w/metabolic physician / biochemical geneticist ¹	Transfer to specialist center w/experience in mgmt of inherited metabolic diseases (strongly recommended).
Consultation w/neurologist	To evaluate & manage seizures
Consultation w/gastroenterologist, nutritionist, feeding team	To evaluate: <ul style="list-style-type: none"> • Aspiration risk & nutritional status; • Gastrostomy tube placement in those w/dysphagia &/or aspiration risk.
Polysomnogram	To assess for central apnea in those w/apnea after a long-term EEG excludes seizures as the primary cause.
Consultation w/ophthalmologist	To assess for ↓ vision, abnormal ocular movement, strabismus
Consultation w/psychologist &/or social worker	To ensure understanding of the diagnosis & assess parental / affected person's coping skills & resources

Table 5. continued from previous page.

Evaluation	Comment
Consultation w/PT, OT, & speech therapist	To aid in developmental deficiencies
Developmental assessment	Consider referral to developmental pediatrician.
Genetic counseling ²	To inform affected persons & families re nature, MOI, & implications of molybdenum cofactor deficiency in order to facilitate medical & personal decision making

MOI = mode of inheritance; OT = occupational therapist; PT = physical therapist

1. After a new diagnosis of molybdenum cofactor deficiency in an infant, the closest hospital and local pediatrician should also be informed.

2. Medical geneticist, certified genetic counselor, certified advanced genetic nurse

Treatment of Manifestations

Targeted Therapies

In GeneReviews, a targeted therapy is one that addresses the specific underlying mechanism of disease causation (regardless of whether the therapy is significantly efficacious for one or more manifestation of the genetic condition); would otherwise not be considered without knowledge of the underlying genetic cause of the condition; or could lead to a cure. —ED

There is no cure for MoCD. However, targeted therapies for individuals with all subtypes of MoCD and specifically for *MOCS1*-related MoCD (MoCD type A) are available (see Table 6).

Table 6. Targeted Therapies for Molybdenum Cofactor Deficiency

MoCD Subtype	Treatment	Dosage/Description	Mechanism	Comments
<i>MOCS1</i>-related MoCD (MoCD type A)	Fosdenopterin (NULIBRY®) ^{1, 2}	<ul style="list-style-type: none"> Dose is dependent on weight & age; each vial contains 9.5 mg of fosdenopterin. Fosdenopterin is administered as a daily IV infusion that requires an indwelling catheter (port) for parents to administer outside of a health care setting. 	Restoration of molybdenum cofactor synthesis ³	<ul style="list-style-type: none"> Fosdenopterin must be initiated in a very short window after manifestations of symptoms to have maximum therapeutic benefit. The most common adverse reactions are infusion catheter-related complications, pyrexia, viral infection, pneumonia, otitis media, vomiting, cough/sneezing, viral upper respiratory infection, gastroenteritis, bacteremia, & diarrhea. Persons treated w/ fosdenopterin or their caregivers should avoid or minimize exposure to direct sunlight or artificial UV light (i.e., UVA or UVB phototherapy) & adopt precautionary measures.⁴

Table 6. continued from previous page.

MoCD Subtype	Treatment	Dosage/Description	Mechanism	Comments
All subtypes	Cysteine-restricted diet ⁵	Accomplished via low-protein diet ⁶ w/restriction of whole natural protein ⁷	To ↓ oxidative cysteine catabolism & downstream sulfite production	<ul style="list-style-type: none"> In severely affected persons diet modification may ↓ irritability but does not affect disease course. In mildly affected persons diet may promote neurodevelopment & ↓ frequency of episodic decompensations.

1. In individuals with MoCD type A, the first of the four synthetic steps in the formation of molybdenum cofactor is interrupted, and GTP cannot be converted into cyclic pyranopterin monophosphate (cPMP). Fosdenopterin is a synthetic version of cPMP (see Molecular Pathogenesis).

2. The efficacy of fosdenopterin (NULIBRY®) was established based on data from three clinical studies compared to data from a natural history study. Affected individuals treated with fosdenopterin (or cPMP) had an improvement in overall survival compared to the untreated, genotype-matched, historical control group (see NULIBRY®, [prescribing information](#)).

3. Replacement therapy with fosdenopterin in individuals with MoCD type A permits the remaining molybdenum cofactor synthesis steps to proceed, with activation of the apoenzyme SOUX resulting in restored mitochondrial-associated sulfite elimination.

4. Precautionary measures may include wearing protective clothing and hats, using broad-spectrum sunscreen with high sun protection factor (SPF) in those greater than age six months, and wearing sunglasses when exposed to the sun.

5. There is limited evidence to support the use of a cysteine-restricted diet in persons with this condition.

6. For example, initial treatment in a neonate may include 1.75g/kg/day protein (with gradual reduction in g/kg protein as the child ages) and protein-free formula/milk.

7. Often requires monitoring of essential amino acids; see Surveillance (Table 8).

Supportive Care

Supportive care to improve quality of life, maximize function, and reduce complications is recommended, ideally involving multidisciplinary care by specialists in relevant fields (see Table 7).

Table 7. Supportive Treatment of Manifestations in Individuals with Molybdenum Cofactor Deficiency

Manifestation	Treatment	Consideration/Other
Seizures/ Epilepsy	Standardized treatment w/ASM by experienced neurologist.	<ul style="list-style-type: none"> Many ASMs may be effective; none has been demonstrated effective specifically for this disorder. Avoid valproate, as sulfite intoxication impairs mitochondrial function in vitro. Education of parents/caregivers ¹
	Consider pyridoxine supplementation.	Because ASAA is ↑ in some persons w/MoCD ² , pyridoxine supplementation has been used, but w/mixed results.
DD/ID	See Developmental Delay / Intellectual Disability Management Issues.	
Poor weight gain / FTT	Feeding therapy; gastrostomy tube placement may be required for concerns re aspiration &/or persistent feeding issues.	Low threshold for clinical feeding eval &/or radiographic swallowing study if clinical signs or symptoms of dysphagia
Thiamine deficiency	Thiamine supplementation: <ul style="list-style-type: none"> Infants: 1.2 mg/day Children & adolescents: 50 mg/1x/day - 100 mg/2x/day 	Based on ability of sulfite to degrade thiamine in vitro & low risk of toxicity, supplementation is recommended.

Table 7. continued from previous page.

Manifestation	Treatment	Consideration/Other
Spasticity & dystonia	Standardized treatment w/oral medications, targeted botulinum toxin/phenol injections, bracing, PT	See Motor Dysfunction.
Headaches	Magnesium supplementation & standardized migraine prophylactics	Anecdotally, the authors have had good success w/ magnesium supplementation in mildly affected persons. ³
Central apnea	Tracheostomy tube placement may be considered in severe cases but is not typically necessary.	Brain stem function typically preserved; frequency of life-threatening apnea unknown
Ectopia lentis	Standard treatment per ophthalmologist	
Family/Community	<ul style="list-style-type: none"> • Ensure appropriate social work involvement to connect families w/local resources, respite, & support. • Coordinate care to manage multiple subspecialty appointments, equipment, medications, & supplies. 	Ongoing assessment of need for palliative care involvement &/or home nursing

ASAA = alpha-aminoadipic semialdehyde; ASM = anti-seizure medication; DD = developmental delay; FTT = failure to thrive; ID = intellectual disability; OT = occupational therapy; PT = physical therapy

1. Education of parents/caregivers regarding common seizure presentations is appropriate. For information on non-medical interventions and coping strategies for children diagnosed with epilepsy, see [Epilepsy Foundation Toolbox](#).

2. It should be noted that alpha-aminoadipic semialdehyde excretion has been detected in some persons with molybdenum cofactor deficiency [Mills et al 2012, Struys et al 2012].

3. Magnesium is also an N-methyl D-aspartate (NMDA) receptor blocker and could have added benefit in the setting of S-sulfocysteine mediated NMDA receptor overactivation.

Developmental Delay / Intellectual Disability Management Issues

The following information represents typical management recommendations for individuals with developmental delay / intellectual disability in the United States. Standard recommendations may vary from country to country.

Ages 0-3 years. Referral to an early intervention program is recommended for access to occupational, physical, speech, and feeding therapy as well as infant mental health services, special educators, and sensory impairment specialists. In the US, early intervention is a federally funded program available in all states that provides in-home services to target individual therapy needs.

Ages 3-5 years. In the US, developmental preschool through the local public school district is recommended. Before placement, an evaluation is made to determine needed services and therapies and an individualized education plan (IEP) is developed for those who qualify based on established motor, language, social, or cognitive delay. The early intervention program typically assists with this transition. Developmental preschool is center based; for children too medically unstable to attend, home-based services are provided.

All ages. Consultation with a developmental pediatrician is recommended to ensure the involvement of appropriate community, state, and educational agencies (US) and to support parents in maximizing quality of life. Some issues to consider:

- IEP services:
 - An IEP provides specially designed instruction and related services to children who qualify.
 - IEP services will be reviewed annually to determine whether any changes are needed.
 - Special education law requires that children participating in an IEP be in the least restrictive environment feasible at school and included in general education as much as possible, when and where appropriate.
 - Vision and hearing consultants should be a part of the child's IEP team to support access to academic material.

- PT, OT, and speech services will be provided in the IEP to the extent that the need affects the child's access to academic material. Beyond that, private supportive therapies based on the affected individual's needs may be considered. Specific recommendations regarding type of therapy can be made by a developmental pediatrician.
- As a child enters the teen years, a transition plan should be discussed and incorporated in the IEP. For those receiving IEP services, the public school district is required to provide services until age 21.
- A 504 plan (Section 504: a US federal statute that prohibits discrimination based on disability) can be considered for those who require accommodations or modifications such as front-of-class seating, assistive technology devices, classroom scribes, extra time between classes, modified assignments, and enlarged text.
- Developmental Disabilities Administration (DDA) enrollment is recommended. DDA is a US public agency that provides services and support to qualified individuals. Eligibility differs by state but is typically determined by diagnosis and/or associated cognitive/adaptive disabilities.
- Families with limited income and resources may also qualify for supplemental security income (SSI) for their child with a disability.

Motor Dysfunction

Gross motor dysfunction

- Physical therapy is recommended to maximize mobility and to reduce the risk for later-onset orthopedic complications (e.g., contractures, scoliosis, hip dislocation).
- Consider use of durable medical equipment and positioning devices as needed (e.g., wheelchairs, walkers, bath chairs, orthotics, adaptive strollers).
- For muscle tone abnormalities including hypertonia or dystonia, consider involving appropriate specialists to aid in management of baclofen, tizanidine, Botox[®], anti-parkinsonian medications, or orthopedic procedures.

Fine motor dysfunction. Occupational therapy is recommended for difficulty with fine motor skills that affect adaptive function such as feeding, grooming, dressing, and writing.

Oral motor dysfunction should be assessed at each visit and clinical feeding evaluations and/or radiographic swallowing studies should be obtained for choking/gagging during feeds, poor weight gain, frequent respiratory illnesses, or feeding refusal that is not otherwise explained. Assuming that the child is safe to eat by mouth, feeding therapy (typically from an occupational or speech therapist) is recommended to help improve coordination or sensory-related feeding issues. Feeds can be thickened or chilled for safety. When feeding dysfunction is severe, a nasogastric or gastrostomy tube may be necessary.

Communication issues. Consider evaluation for alternative means of communication (e.g., [augmentative and alternative communication](#) [AAC]) for individuals who have expressive language difficulties. An AAC evaluation can be completed by a speech-language pathologist who has expertise in the area. The evaluation will consider cognitive abilities and sensory impairments to determine the most appropriate form of communication. AAC devices can range from low-tech, such as picture exchange communication, to high-tech, such as voice-generating devices. Contrary to popular belief, AAC devices do not hinder verbal development of speech, but rather support optimal speech and language development.

Social/Behavioral Concerns

Children may qualify for and benefit from interventions used in treatment of autism spectrum disorder, including applied behavior analysis (ABA). ABA therapy is targeted to the individual child's behavioral, social,

and adaptive strengths and weaknesses and typically performed one on one with a board-certified behavior analyst.

Consultation with a developmental pediatrician may be helpful in guiding parents through appropriate behavior management strategies or providing prescription medications, such as medication used to treat attention-deficit/hyperactivity disorder (ADHD), when necessary.

Concerns about serious aggressive or destructive behavior can be addressed by a pediatric psychiatrist.

Surveillance

In addition to regular evaluations by a metabolic specialist, the following are recommended.

Table 8. Recommended Surveillance for Individuals with Molybdenum Cofactor Deficiency

Manifestation	Evaluation	Frequency/Comment
Essential amino acid deficiency	Measurement of essential amino acids ¹	Routinely in those on cysteine-restricted low-protein diet w/ restriction of whole natural protein
Neurologic signs/symptoms	<ul style="list-style-type: none"> Monitor those w/seizures as clinically indicated. Assess for new manifestations incl seizures, changes in tone, mvmt disorders, & headaches. 	At each visit
Delayed acquisition of developmental milestones	Monitor developmental milestones. <ul style="list-style-type: none"> Neuropsychological testing using age-appropriate standardized assessment batteries Standardized quality-of-life assessment tools for affected persons & parents/caregivers 	As needed
Poor growth	Measurement of growth & head circumference	At each visit
Motor dysfunction	Physical medicine, OT/PT assessment of mobility, self-help skills	As clinically indicated or at least annually
Ectopia lentis	Ophthalmology eval	At each visit
Miscellaneous/Other	Assess family need for social work support (e.g., palliative / respite care, home nursing, other local resources) & care coordination.	

OT = occupational therapy; PT = physical therapy

1. Which may include phenylalanine, valine, threonine, tryptophan, methionine, leucine, isoleucine, lysine, and histidine

Agents/Circumstances to Avoid

Valproate should be avoided if possible, as sulfite intoxication impairs mitochondrial function in vitro.

For individuals on fosdenopterin (NULIBRY[®]), direct sunlight and artificial UV light exposure (i.e., UVA or UVB phototherapy) should be avoided (see Table 6).

Evaluation of Relatives at Risk

For at-risk newborn sibs when prenatal testing was not performed, metabolic treatment should be initiated immediately and continued until such a time as the diagnosis has been excluded. Postnatal diagnostic evaluations can include the following:

- Molecular genetic testing if the pathogenic variants in the family are known

- If the pathogenic variants in the family are not known, measure serum uric acid and urinary: sulfite, s-sulfocysteine, xanthine, hypoxanthine, and uric acid.

See Genetic Counseling for issues related to testing of at-risk relatives for genetic counseling purposes.

Therapies Under Investigation

Search [ClinicalTrials.gov](https://clinicaltrials.gov) in the US and [EU Clinical Trials Register](https://clinicaltrialsregister.eu) in Europe for access to information on clinical studies for a wide range of diseases and conditions. Note: There may not be clinical trials for this disorder.

Genetic Counseling

Genetic counseling is the process of providing individuals and families with information on the nature, mode(s) of inheritance, and implications of genetic disorders to help them make informed medical and personal decisions. The following section deals with genetic risk assessment and the use of family history and genetic testing to clarify genetic status for family members; it is not meant to address all personal, cultural, or ethical issues that may arise or to substitute for consultation with a genetics professional. —ED.

Mode of Inheritance

Molybdenum cofactor deficiency (MoCD) is inherited in an autosomal recessive manner.

Risk to Family Members

Parents of a proband

- The parents of an affected child are obligate heterozygotes (i.e., presumed to be carriers of one *GPHN*, *MOCS1*, *MOCS2*, or *MOCS3* pathogenic variant based on family history).
- If a molecular diagnosis has been established in the proband, molecular genetic testing is recommended for the parents of a proband to confirm that both parents are heterozygous for an MoCD-causing pathogenic variant and to allow reliable recurrence risk assessment. If a pathogenic variant is detected in only one parent and parental identity testing has confirmed biological maternity and paternity, the following possibilities should be considered:
 - One of the pathogenic variants identified in the proband occurred as a *de novo* event in the proband or as a postzygotic *de novo* event in a mosaic parent [Jónsson et al 2017].
 - Uniparental isodisomy for the parental chromosome with the pathogenic variant resulted in homozygosity for the pathogenic variant in the proband.
- Heterozygotes (carriers) are asymptomatic and are not at risk of developing the disorder.

Sibs of a proband

- If both parents are known to be heterozygous for an MoCD-causing pathogenic variant, each sib of an affected individual has at conception a 25% chance of being affected, a 50% chance of being an asymptomatic carrier, and a 25% chance of being unaffected and not a carrier.
- Heterozygotes (carriers) are asymptomatic and are not at risk of developing the disorder.

Offspring of a proband. To date, individuals with MoCD are not known to reproduce.

Other family members. Each sib of the proband's parents is at a 50% risk of being a carrier of an MoCD-causing pathogenic variant.

Carrier Detection

Carrier testing for at-risk relatives requires prior identification of the MoCD-causing pathogenic variants in the family.

Related Genetic Counseling Issues

See Management, Evaluation of Relatives at Risk for information on evaluating at-risk relatives for the purpose of early diagnosis and treatment.

Family planning

- The optimal time for determination of genetic risk and discussion of the availability of prenatal/preimplantation genetic testing is before pregnancy.
- It is appropriate to offer genetic counseling (including discussion of potential risks to offspring and reproductive options) to young adults who are carriers or are at risk of being carriers.

DNA banking. Because it is likely that testing methodology and our understanding of genes, pathogenic mechanisms, and diseases will improve in the future, consideration should be given to banking DNA from probands in whom a molecular diagnosis has not been confirmed (i.e., the causative pathogenic mechanism is unknown). For more information, see Huang et al [2022].

Prenatal Testing and Preimplantation Genetic Testing

Once the MoCD-causing pathogenic variants have been identified in an affected family member, prenatal and preimplantation genetic testing are possible.

Differences in perspective may exist among medical professionals and within families regarding the use of prenatal testing. While most centers would consider use of prenatal testing to be a personal decision, discussion of these issues may be helpful.

Resources

GeneReviews staff has selected the following disease-specific and/or umbrella support organizations and/or registries for the benefit of individuals with this disorder and their families. GeneReviews is not responsible for the information provided by other organizations. For information on selection criteria, click [here](#).

- **MedlinePlus**
Molybdenum cofactor deficiency

Molecular Genetics

Information in the Molecular Genetics and OMIM tables may differ from that elsewhere in the GeneReview: tables may contain more recent information. —ED.

Table A. Molybdenum Cofactor Deficiency: Genes and Databases

Gene	Chromosome Locus	Protein	Locus-Specific Databases	HGMD	ClinVar
<i>GPHN</i>	14q23.3-q24.1	Gephyrin	GPHN database	GPHN	GPHN
<i>MOCS1</i>	6p21.2	Molybdenum cofactor biosynthesis protein 1	MOCS1 database	MOCS1	MOCS1

Table A. continued from previous page.

MOCS2	5q11.2	Molybdopterin synthase catalytic subunit	MOCS2	MOCS2
MOCS3	20q13.13	Adenylyltransferase and sulfurtransferase MOCS3	MOCS3	MOCS3

Data are compiled from the following standard references: gene from [HGNC](#); chromosome locus from [OMIM](#); protein from [UniProt](#). For a description of databases (Locus Specific, HGMD, ClinVar) to which links are provided, click [here](#).

Table B. OMIM Entries for Molybdenum Cofactor Deficiency (View All in OMIM)

252150	MOLYBDENUM COFACTOR DEFICIENCY, COMPLEMENTATION GROUP A; MOCODA
252160	none found
603707	MOLYBDENUM COFACTOR SYNTHESIS GENE 1; MOCS1
603708	MOLYBDENUM COFACTOR SYNTHESIS GENE 2; MOCS2
603930	GEPHYRIN; GPHN
609277	MOLYBDENUM COFACTOR SYNTHESIS 3; MOCS3
615501	MOLYBDENUM COFACTOR DEFICIENCY, COMPLEMENTATION GROUP C; MOCODC

Molecular Pathogenesis

The molybdenum cofactor (Moco) is synthesized from guanosine triphosphate (GTP) via a biochemical pathway that can be divided into four steps according to four intermediates: cyclic pyranopterin monophosphate (cPMP; also known previously as precursor Z), MPT, adenylated MPT (MPT-AMP), and Moco. See Figure 1 for an illustration of the pathway and how *MOCS1*, *MOCS2*, *MOCS3*, and *GPHN* are involved in Moco synthesis.

Although four human enzymes are dependent on Moco for catalytic function (sulfite oxidase, the mitochondrial amidoxime reducing component, xanthine oxidase, and aldehyde oxidase), the loss of sulfite oxidase activity alone is necessary and sufficient to give rise to the phenotype of MoCD. Sulfite oxidase catalyzes the oxidation of sulfite to sulfate in the last step of methionine and cysteine catabolism (the sulfur-containing amino acids). In the absence of sulfite oxidase, sulfite accumulates in the blood, urine, and CSF of affected individuals. Because the enzyme is highly expressed in liver and kidney, these organs may be responsible for the generation of sulfite in affected individuals.

Data suggest that sulfite and S sulfocysteine (the reaction product of sulfite and cystine) are the toxic metabolites responsible for neurodegeneration in individuals with MoCD and isolated sulfite oxidase deficiency. Sulfite depletes intracellular ATP in cultured neuronal cell lines and impairs mitochondrial respiration. S sulfocysteine is stereochemically similar to glutamate and activates NMDA receptors [Kumar et al 2017]. The proposed pathomechanisms associated with these metabolites fit well with the brain MRI features which suggest critical energy failure and excitotoxic injury.

Xanthine oxidase requires Moco for the breakdown of nucleotides to uric acid. Aldehyde oxidase requires Moco to catalyze a number of hydroxylation reactions. Mitochondrial amidoxime-reducing component, together with NADH-cytochrome b5 reductase and cytochrome b5, is thought to require Moco for catalyzation detoxification of mutagenic N-hydroxylated bases, although the exact function is as yet unclear.

Mechanism of disease causation. Loss of function

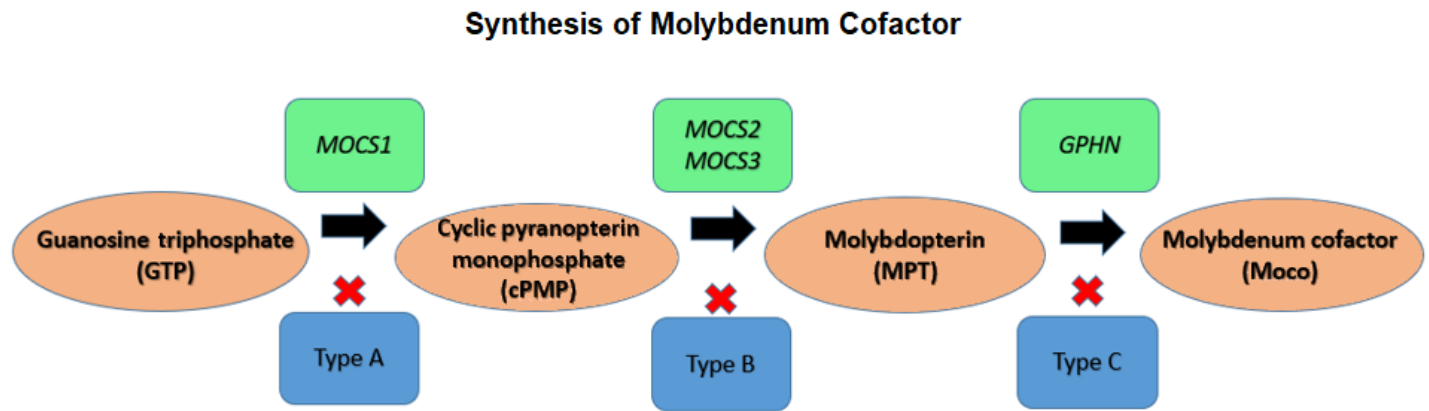


Figure 1. Synthesis of molybdenum cofactor (Moco). GTP is converted to cPMP by *MOCS1*. cPMP is converted to MPT by *MOCS2* and *MOCS3*. The final step is conversion of MPT to Moco by *GPHN*.

Chapter Notes

Revision History

- 2 February 2023 (pa/ma) Revision: fosdenopterin added as targeted treatment for *MOCS1*-related MoCD (MoCD type A) (Targeted Therapies)
- 2 December 2021 (ma) Review posted live
- 4 January 2021 (pa) Original submission

References

Literature Cited

- Huang SJ, Amendola LM, Stern DL. Variation among DNA banking consent forms: points for clinicians to bank on. *J Community Genet.* 2022;13:389-97. PubMed PMID: 35834113.
- Jónsson H, Sulem P, Kehr B, Kristmundsdóttir S, Zink F, Hjartarson E, Hardarson MT, Hjorleifsson KE, Eggertsson HP, Gudjonsson SA, Ward LD, Arnadóttir GA, Helgason EA, Helgason H, Gylfason A, Jonasdóttir A, Jonasdóttir A, Rafnar T, Frigge M, Stacey SN, Th Magnusson O, Thorsteinsdóttir U, Masson G, Kong A, Halldorsson BV, Helgason A, Gudbjartsson DF, Stefansson K. Parental influence on human germline de novo mutations in 1,548 trios from Iceland. *Nature.* 2017;549:519-22. PubMed PMID: 28959963.
- Kumar A, Dejanovic B, Hetsch F, Semtner M, Fusca D, Arjune S, Santamaria-Araujo JA, Winkelmann A, Ayton S, Bush AI, Kloppenburg P, Meier JC, Schwarz G, Belaidi AA. S-sulfocysteine/NMDA receptor-dependent signaling underlies neurodegeneration in molybdenum cofactor deficiency. *J Clin Invest.* 2017;127:4365-78. PubMed PMID: 29106383.
- Macaya A, Brunso L, Fernández-Castillo N, Arranz JA, Ginjaar HB, Cuenca-León E, Corominas R, Roig M, Cormand B. Molybdenum cofactor deficiency presenting as neonatal hyperekplexia: a clinical, biochemical and genetic study. *Neuropediatrics.* 2005;36:389-94. PubMed PMID: 16429380.
- Mills PB, Footitt EJ, Ceyhan S, Waters PJ, Jakobs C, Clayton PT, Struys EA. Urinary AASA excretion is elevated in patients with molybdenum cofactor deficiency and isolated sulphite oxidase deficiency. *J Inher Metab Dis.* 2012;35:1031-6. PubMed PMID: 22403017.
- Misko AL, Liang Y, Kohl JB, Eichler F. Delineating the phenotypic spectrum of sulfite oxidase and molybdenum cofactor deficiency. *Neurol Genet.* 2020;6:e486. PubMed PMID: 32802950.

- Parini R, Briscioli V, Caruso U, Dorche C, Fortuna R, Minniti G, Selicorni A, Vismara E, Mancini G. Spherophakia associated with molybdenum cofactor deficiency. *Am J Med Genet.* 1997;73:272-5. PubMed PMID: 9415683.
- Richards S, Aziz N, Bale S, Bick D, Das S, Gastier-Foster J, Grody WW, Hegde M, Lyon E, Spector E, Voelkerding K, Rehm HL, et al. Standards and guidelines for the interpretation of sequence variants: a joint consensus recommendation of the American College of Medical Genetics and Genomics and the Association for Molecular Pathology. *Genet Med.* 2015;17:405-24. PubMed PMID: 25741868.
- Stence NV, Coughlin CR 2nd, Fenton LZ, Thomas JA. Distinctive pattern of restricted diffusion in a neonate with molybdenum cofactor deficiency. *Pediatr Radiol.* 2013;43:882-5. PubMed PMID: 23250031.
- Struys EA, Nota B, Bakkali A, Al Shahwan S, Salomons GS, Tabarki B. Pyridoxine-dependent epilepsy with elevated urinary α -amino adipic semialdehyde in molybdenum cofactor deficiency. *Pediatrics.* 2012;130:e1716-9. PubMed PMID: 23147983.
- Tezel G, Oztekin O, Kalay S, Aslan A, Akçakuş M, Oygür N. The association of molybdenum cofactor deficiency and pyloric stenosis. *J Perinatol.* 2012;32:896-8. PubMed PMID: 23128059.
- Vijayakumar K, Gunny R, Grunewald S, Carr L, Chong KW, DeVile C, Robinson R, McSweeney N, Prabhakar P. Clinical neuroimaging features and outcome in molybdenum cofactor deficiency. *Pediatr Neurol.* 2011;45:246-52. PubMed PMID: 21907887.
- Zaki MS, Selim L, El-Bassyouni HT, Issa MY, Mahmoud I, Ismail S, Girgis M, Sadek AA, Gleeson JG, Abdel Hamid MS. Molybdenum cofactor and isolated sulphite oxidase deficiencies: clinical and molecular spectrum among Egyptian patients. *Eur J Paediatr Neurol.* 2016;20:714-22. PubMed PMID: 27289259.

License

GeneReviews® chapters are owned by the University of Washington. Permission is hereby granted to reproduce, distribute, and translate copies of content materials for noncommercial research purposes only, provided that (i) credit for source (<http://www.genereviews.org/>) and copyright (© 1993-2024 University of Washington) are included with each copy; (ii) a link to the original material is provided whenever the material is published elsewhere on the Web; and (iii) reproducers, distributors, and/or translators comply with the [GeneReviews® Copyright Notice and Usage Disclaimer](#). No further modifications are allowed. For clarity, excerpts of GeneReviews chapters for use in lab reports and clinic notes are a permitted use.

For more information, see the [GeneReviews® Copyright Notice and Usage Disclaimer](#).

For questions regarding permissions or whether a specified use is allowed, contact: admasst@uw.edu.