



## Oculocutaneous Albinism and Ocular Albinism Overview

Mervyn G Thomas, MBChB, PhD, FRCOphth,<sup>1</sup> Jonathan Zippin, MD, PhD,<sup>2</sup> and Brian P Brooks, MD, PhD<sup>3</sup>

Created: April 13, 2023.

### Summary

The purpose of this overview is to increase the awareness of clinicians regarding oculocutaneous albinism and ocular albinism, and their genetic causes, management, and genetic counseling.

The following are the goals of this overview.

#### Goal 1

Briefly describe the clinical characteristics of oculocutaneous albinism and ocular albinism.

#### Goal 2

Review the genetic causes of oculocutaneous albinism and ocular albinism.

#### Goal 3

Review the differential diagnosis of oculocutaneous albinism and ocular albinism with a focus on genetic conditions.

#### Goal 4

Provide an evaluation strategy to identify the genetic cause of oculocutaneous albinism or ocular albinism in a proband (when possible).

#### Goal 5

Inform genetic counseling of an individual with oculocutaneous albinism or ocular albinism and their family members.

**Author Affiliations:** 1 Ulverscroft Eye Unit, College of Life Sciences, School of Psychology and Vision Sciences, University of Leicester, Leicester, UK; Email: mt350@le.ac.uk. 2 Department of Dermatology, Joan and Sanford I Weill Medical College of Cornell University, New York, New York; Email: jhzippin@med.cornell.edu. 3 Ophthalmic Genetics and Visual Function Branch, National Eye Institute, National Institutes of Health, Bethesda, Maryland; Email: brooksb@nei.nih.gov.

## Goal 6

Review management of oculocutaneous albinism and ocular albinism.

# 1. Clinical Characteristics of Oculocutaneous Albinism and Ocular Albinism

Albinism is a genetically heterogeneous hypopigmentary disorder characterized by cutaneous and ocular hypopigmentation [Liu et al 2021]. In oculocutaneous albinism (OCA), impaired melanin biosynthesis leads to hypopigmentation in the skin, hair, and eyes with characteristic ocular abnormalities; in ocular albinism (OA), only the visual pathway is clinically affected.

## Eyes/Vision

The ophthalmic manifestations associated with albinism can include the following:

- **Iris transillumination defect (TID)** is the loss of iris pigment epithelium. Iris TIDs are reported to be present in 91% [Kruijt et al 2018] to 100% [Sheth et al 2013] of individuals with albinism. The presence of an iris TID is generally associated with photophobia [Sjödell et al 1996].

To identify iris TIDs it is recommended that a retroillumination technique (thin axial light beam) on slit lamp biomicroscopy be performed in a dark room.

Optical coherence tomography (OCT) examination to assess iris morphology often identifies a significantly thinner posterior epithelium layer in individuals with albinism compared to controls [Sheth et al 2013].

Iris TIDs can be graded using classification systems for objectively documenting iris involvement [Summers et al 1988, Kruijt et al 2018, Adams et al 2019].

- **Nystagmus** associated with albinism is generally conjugate and in the horizontal plane with an accelerating slow phase; however, a small vertical component has also previously been described [Kumar et al 2011].

Jerk waveforms are most frequently observed in albinism. Periodic alternating nystagmus is reported to be more common in albinism compared to other etiologies associated with infantile nystagmus [Abadi & Bjerre 2002, Kumar et al 2011] (see Differential Diagnosis).

Individuals with albinism have a null zone where the nystagmus is the least intense.

Assessment of nystagmus can be observational (e.g., while carrying out ocular movement assessment) or documented using a graphic representation with eye movement recordings (EMRs).

Although nystagmus is generally considered a common characteristic of albinism, absence of nystagmus has been reported in up to 7.7% of individuals with albinism [Kruijt et al 2018].

Nystagmus associated with albinism demonstrates similar characteristics to idiopathic infantile nystagmus both with and without *FRMD7* variants [Kumar et al 2011] (see [FRMD7-Related Infantile Nystagmus](#)).

Anomalous head posture (AHP) is more severe in albinism compared to [FRMD7-related infantile nystagmus](#) (a major cause of idiopathic infantile nystagmus).

- **Fundus hypopigmentation** results from reduced pigmentation of the retinal pigment epithelium and/or choroid and often leads to visible prominent choroidal vessels within the posterior pole. Fundus hypopigmentation is reported to be present in more than 94% of individuals with albinism [Kruijt et al 2018].

Fundus examination can be performed with direct or indirect ophthalmoscopy, posterior slit lamp examination, or fundus photography.

Fundus hypopigmentation associated with albinism varies in severity and can be graded using a classification system for objectively documenting degree of fundal involvement [Summers et al 1988, Kruijt et al 2018].

Unaffected female carriers of *GPR143* pathogenic variants / X-linked OA have also demonstrated a "mud-splattered" fundus appearance, with patches of hypopigmentation and normal pigmentation.

- **Foveal hypoplasia** is characterized by the continuation of inner retinal layers posterior to the foveola and reduced cone photoreceptor specialization [Thomas et al 2011b], visualized on OCT. This can also be identified on fundoscopy as a blunting or lack of the foveal reflex. In albinism, foveal hypoplasia has been reported to be present in between 94% [Kruijt et al 2018, Kuht et al 2022a] and 100% of individuals [Mohammad et al 2011, Thomas et al 2011b].

Foveal hypoplasia can be graded using a system devised by Thomas et al [2011b] (see Figure 1). This grading system can be used for both diagnosis [Kuht et al 2020, Kuht et al 2022a, Kruijt et al 2022] and predicting future visual acuity in preverbal children [Thomas et al 2011b, Rufai et al 2020].

A spectrum of the severity of foveal hypoplasia has been reported in individuals with albinism [Kruijt et al 2018, Kuht et al 2022a]: in nonsyndromic OCA, foveal hypoplasia ranges from grades 1 to 4 [Kuht et al 2022a]. In [Hermansky-Pudlak syndrome](#), a syndromic OCA, foveal hypoplasia ranges from grades 3 to 4.

- **Optic nerve abnormalities** associated with albinism include the following:
  - Smaller cup-to-disc ratios are frequently observed.
  - Often there is elongation in the horizontal plane, possibly related to decussation defects [Mohammad et al 2015].
  - Reduction of the thickness of the peripapillary retinal nerve fiber layer (the temporal quadrant being most significantly affected) is a highly consistent finding [Mohammad et al 2015].
  - An appearance of elevation, as a small cupless disc or oblique cup with situs inversus [Charles et al 1993, Schatz & Pollock 1994, Chong et al 2009], can be observed.
- **Chiasmal misrouting** describes the abnormal decussation of retinal ganglion cell axons at the optic chiasm. In individuals with albinism a portion of temporal retinal fibers cross over onto the contralateral hemisphere [Hoffmann et al 2005], whereas in normal controls nasal retinal fibers cross over at the chiasm.
 

Visual evoked potentials (VEPs) can be used to aid in diagnosis by identifying chiasmal misrouting. Chiasmal misrouting has been reported in between 84% [Kruijt et al 2018] and 100% [Kumar et al 2011] of individuals with albinism. Diagnostic sensitivity of VEP testing varies with age and type of VEP stimulus used [Kruijt et al 2019].
- **Anomalous head posture (AHP)** is more severe and common in albinism compared to other forms of infantile nystagmus [Kumar et al 2011]. An eccentric null zone can contribute to developing an AHP. An alternating head posture should raise the possibility of periodic alternating nystagmus (PAN), in which the nystagmus direction and intensity changes over time. Careful examination of nystagmus characteristics over an extended period of time (5-7 minutes with central fixation) helps determine whether PAN is present.
- **Refractive errors** are often associated with albinism. Hypermetropia is more common than myopia [Yahalom et al 2012]; with-the-rule astigmatism is common [Wildsoet et al 2000].

- **Strabismus** is observed in approximately 71% of individuals with albinism [Kumar et al 2011]. However, in OCA1 (see Table 2), prevalence of strabismus is as high as 100%.  
Esotropia is most frequently observed in albinism [Kumar et al 2011].
- **Positive angle kappa.** Angle kappa describes the difference between the pupillary axis and the visual axis. A positive angle kappa exists when the fovea is situated slightly temporal to the intersection of the pupillary axis to the posterior portion of the globe. Positive angle kappa occasionally gives the appearance of an exotropia. Positive angle kappa is commonly associated with albinism, whereas it is usually absent in individuals with idiopathic infantile nystagmus [Brodsky & Fray 2004].
- **Visual acuity.** Due to a combination of ocular manifestations in albinism, visual acuity is commonly reduced to varying degrees. In albinism, visual acuity is strongly correlated to the grade of foveal hypoplasia and measurements of photoreceptor thickness [Mohammad et al 2011, Thomas et al 2011b, Wilk et al 2017, Rufai et al 2020].

Visual acuity is assessed using age-appropriate visual acuity charts.

- **For literate adults/children,** Snellen or logMAR charts are used. Each chart is different and may be produced for a certain distance – Snellen charts are produced for six meters, and logMAR charts are produced for four meters. The individual being tested reads letters from a standardized chart from the appropriate distance using only one eye at a time.

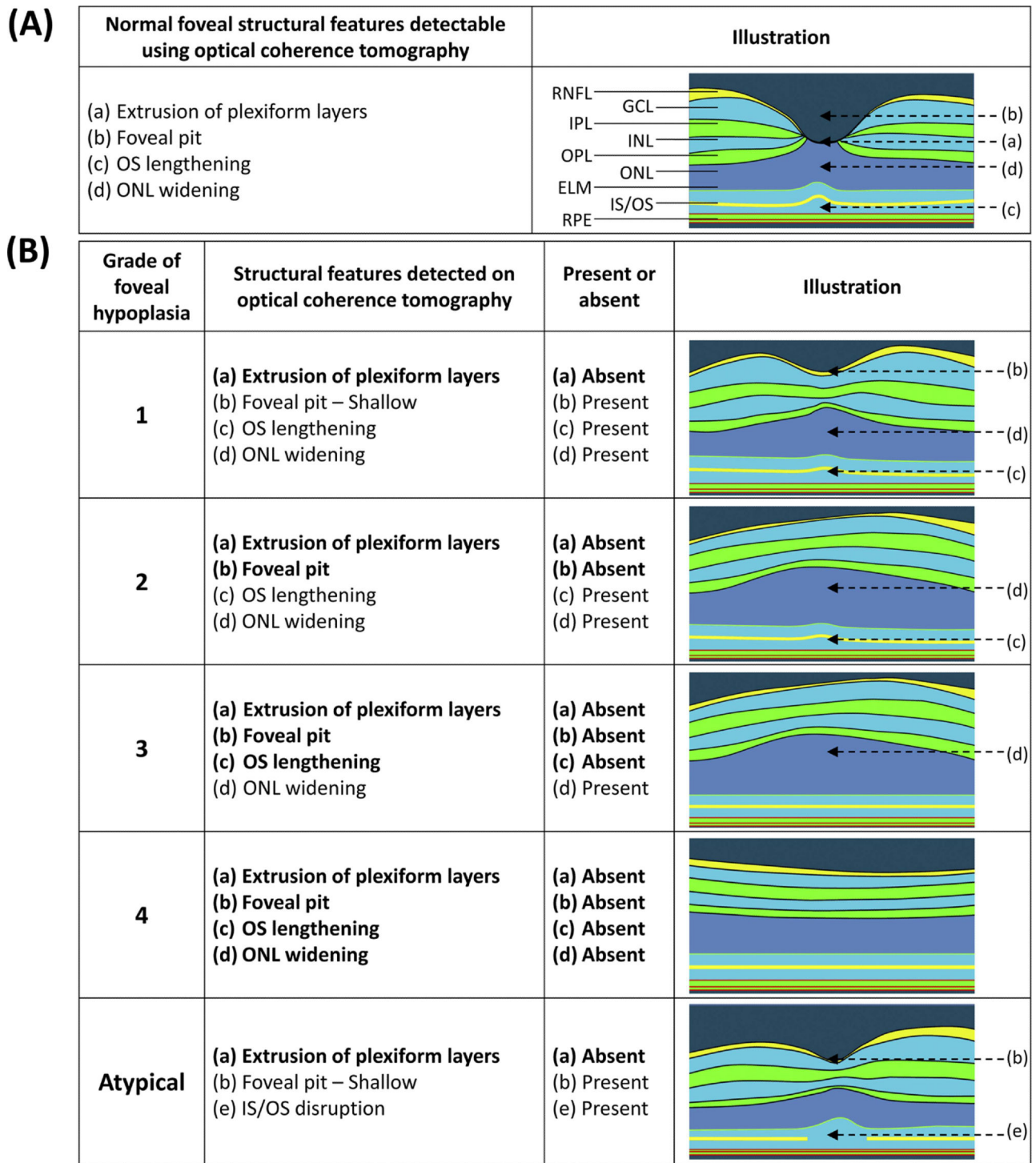
Visual acuity is expressed as a fraction in which the numerator represents the distance at which the test was conducted. For example, visual acuity of 20/80 means that the individual can read at 20 feet what a person with normal vision can read at 80 feet. Visual acuity of 20/80 in the United States would correspond to visual acuity of 6/24 in the United Kingdom, where meters are the unit of measurement.

In persons with albinism, visual acuity can range between -0.10 to 1.60 logMAR acuity [Kruijt et al 2018, Kuht et al 2022a], which equates to 20/15 to 20/800 in Snellen acuity. The median visual acuity tends to be 0.60 logMAR acuity (equivalent to Snellen visual acuity of 20/80) [Kuht et al 2022a].

- **For babies and infants,** behavioral tests are used, including assessment of fixing and following, objection to occlusion, and tests of preferential looking.

## Cutaneous Manifestations

The skin and hair color of an individual with albinism may change with age (see Table 1). Since evaluating skin hypopigmentation can be subjective and assessment of reduced pigmentation can vary by ethnicity, assessing skin pigmentation in relation to unaffected family members and inquiring about whether the skin tans or burns with sun exposure is helpful. Skin and hair pigmentation scores help to objectively determine effects of hypopigmentation and may guide skin protection recommendations. Note that while these scales are useful, they are not always implemented in busy clinics, where questions are often confined to whether skin tans versus burns.



**Figure 1.** (A) Illustration of the unique features of a normal fovea detectable on optical coherence tomography. (B) Illustration of typical and atypical grades of foveal hypoplasia. All grades of foveal hypoplasia have incursion of inner retinal layers. Atypical foveal hypoplasia also has incursion of the inner retinal layers. In OCA all four grades of foveal hypoplasia are observed; however, in OA and *Hermansky-Pudlak syndrome*, only grades 3 and 4 have been observed [Kuht et al 2022a].

Grade 1: shallow foveal pit (near-normal pit in grade 1a vs shallow indent in grade 1b), outer nuclear layer (ONL) widening, and outer segment (OS) lengthening relative to the parafoveal ONL and OS length, respectively

Grade 2: all the features of grade 1 present except the presence of a foveal pit

Grade 3: all the features of grade 2 present except the widening of the cone OS

Grade 4: all the features of grade 3 are present except no widening of the ONL at the fovea



Atypical foveal hypoplasia: shallower foveal pit with disruption of the inner segment ellipsoid (Note: Not observed in albinism, but seen in other retinal disorders such as [achromatopsia](#) [Thomas et al 2011a, Thomas et al 2011b].)

Adapted with permission from Thomas et al [2011b]

**Table 1.** Skin and Hair Pigmentation Scores

Skin and Hair Pigmentation Scores			
<b>Skin pigmentation score</b>			
Score	Color	Tanning	Other
1	White	None	
2	White	Some	May have pigmented nevi
3	Pale	Some visible tanning	
4	Pale	Visible tanning	
5	Normal	Good tanning	
<b>Hair pigmentation score</b>			
Score	Color		
1	Completely white		
2	Silvery white		
3	White with yellowish touch		
4	Whitish blond		
5	Pale blond		
6	Medium blond		
7	Dark blond		
8	Red, reddish blond		
9	Medium brown		
10	Dark brown, black		

Based on Schmitz et al [2003]

Loss of pigmentation in the skin leads to a variety of psychosocial morbidities and susceptibility to diseases of the skin.

**Diseases of the skin.** Regardless of their skin tone, all individuals with albinism are at increased risk of skin diseases associated with ultraviolet (UV) light exposure [Ma et al 2023]. The most significant of these is skin cancer, which includes all of the UV light-driven cancers, including squamous cell carcinoma, basal cell carcinoma, melanoma, and less commonly Merkel cell carcinoma [Ma et al 2023]. Individuals with OCA are also at higher risk for sunburns and general sun sensitivity, which can limit outdoor activities where use of sun-protective clothing or sunscreen is not possible. With inappropriate sun exposure, freckles, nevi, and lentigines, which can have cosmetic implications, can develop. Excess UV light exposure can also increase the rate of cutaneous signs of aging [Krutmann et al 2021].

**Psychosocial morbidities.** The loss of pigmentation tends to have a greater psychosocial effect on individuals with darker skin tone, as the loss of pigmentation is more dramatic [Franklin et al 2018, Marçon & Maia 2019, Anshelevich et al 2021]. In certain African communities, for example, albinism can lead to social isolation [Franklin et al 2018, Marçon & Maia 2019, Nakkazi 2019, Anshelevich et al 2021].

## Nomenclature

It is appropriate to classify nonsyndromic OCA according to the gene involved rather than by phenotype (i.e., extent of skin and ophthalmologic involvement). Thus, two former classifications (based on skin and ophthalmologic findings and/or mode of inheritance) are confusing and no longer valid. This is partly due to phenotypic heterogeneity in different races despite having the same genetic variants. The authors recommend that these terms no longer be used.

- **"Brown" OCA**, described initially in Nigeria and Ghana and considered a separate entity based on early family studies, is now known to be part of the phenotypic continuum of *OCA2*-related OCA, which encompasses "classic" OCA (yellow/blond hair, creamy-tan skin, and blue/hazel irides) and more pigmented phenotypes like "brown" OCA [King et al 1985, Manga et al 2001].
- **Autosomal recessive ocular albinism (AROA)**. Individuals with near-normal skin and hair pigmentation, ocular hypopigmentation, and variants in OCA-related genes have been classified as AROA. In a cohort of individuals with suspected AROA, genetic testing revealed a significant proportion of individuals had hypomorphic *TYR* variants [Hutton & Spritz 2008] (see Table 2). Variants in *OCA2* and *TYRP1* have also been reported to cause AROA [Hutton & Spritz 2008].

## 2. Genetic Causes of Oculocutaneous Albinism and Ocular Albinism

Table 2 and Table 3 provide information about the genes that cause oculocutaneous albinism (OCA) and ocular albinism (OA):

- Table 2 summarizes genes known to be associated with nonsyndromic OCA and OA. All nonsyndromic OCA is inherited in an autosomal recessive manner. OA (which is always nonsyndromic) is inherited in an X-linked manner.
- Table 3 summarizes genes known to be associated with syndromic OCA.

**Table 2.** Nonsyndromic Oculocutaneous Albinism and Ocular Albinism by Gene

Gene <sup>1, 2</sup>	Disorder	% of All OCA	Comments
<i>TYR</i>	OCA1 (OMIM 606933)	42%	<p>OCA1 is broadly divided into OCA1A &amp; OCA1B:</p> <ul style="list-style-type: none"> <li>• OCA1A: absence or complete inactivity of TYR enzyme; severe reduction of retinal, iris, &amp; skin pigmentation</li> <li>• OCA1B: reduced TYR enzyme activity (due to hypomorphic <i>TYR</i> variants); variable amounts of pigmentation, incl near normal cutaneous &amp; hair pigment</li> </ul>
<i>OCA2</i>	OCA2 (OMIM 611409)	28%	<ul style="list-style-type: none"> <li>• Phenotypic spectrum incl "brown" OCA.<sup>3</sup></li> <li>• <i>OCA2</i> &amp; <i>TYRP1</i> pathogenic variants are the most common causes of albinism in sub-Saharan Africa.</li> </ul>
<i>TYRP1</i>	OCA3 (OMIM 115501)	2.1%	<ul style="list-style-type: none"> <li>• Phenotype (previously described as "rufous" albinism) is characterized by red-bronze skin color, ginger-red hair, &amp; blue or brown irides.</li> <li>• OCA3 is more common in African populations than in other populations (e.g., South Asian, European).</li> </ul>

Table 2. continued from previous page.

Gene <sup>1, 2</sup>	Disorder	% of All OCA	Comments
<i>SLC45A2</i> ( <i>MATP</i> )	OCA4	11%	<ul style="list-style-type: none"> <li>• Most common OCA in Japan</li> <li>• Few affected persons have cutaneous &amp; ocular hypopigmentation; most have normal visual acuity &amp; foveal structure. <sup>4</sup></li> </ul>
<i>SLC24A5</i>	OCA6 (OMIM 609802)	3%	<ul style="list-style-type: none"> <li>• Ocular features overlap w/other forms of OCA.</li> <li>• Typically, skin is hypopigmented w/ability to tan in some persons.</li> <li>• Hair color can range from white to brown.</li> </ul>
<i>LRMDA</i> ( <i>C10orf11</i> )	OCA7 (OMIM 614537)	<1%	<ul style="list-style-type: none"> <li>• Only a few affected persons have been reported.</li> <li>• Significant phenotypic overlap exists w/other forms of OCA.</li> </ul>
<i>DCT</i> ( <i>TYRP2</i> )	OCA8 (OMIM 191275)	<1%	Rare; assoc w/mild hair & skin hypopigmentation
<i>GPR143</i> ( <i>OA1</i> )	OA1 (OMIM 300808)	7%	<ul style="list-style-type: none"> <li>• Clinically, only ocular hypopigmentation is present. However, the ocular phenotype of OA &amp; OCA overlap.</li> <li>• In heterozygous females (i.e., carriers), "mud-splattered" fundus has been described due to interspersed regions of pigmentation.</li> </ul>

OA = ocular albinism; OCA = oculocutaneous albinism

1. Where applicable, former gene symbols are listed in parenthesis after the current HGNC-approved gene symbol.

2. Genes are ordered by frequency of causation of OCA [Lasseaux et al 2018]; however, these are based on predominantly European populations. Variants in *OCA2* and *TYRP1* are more common in sub-Saharan Africa. *SLC45A2* variants are more common in Japan.

3. "Brown" OCA, described initially in Nigeria and Ghana and considered a separate entity based on early family studies, is now known to be part of the phenotypic continuum of *OCA2*-related OCA (see Nomenclature).

4. Kruijt et al [2021]

Table 3. Syndromic Oculocutaneous Albinism: Genes and Distinguishing Clinical Features

Genes	Syndrome <sup>1</sup>	% of All OCA	Ocular & Cutaneous Features	Other Clinical Features
<i>AP3B1</i> <i>AP3D1</i> <i>BLOC1S3</i> <i>BLOC1S5</i> <i>BLOC1S6</i> <i>DTNBP1</i> <i>HPS1</i> <i>HPS3</i> <i>HPS4</i> <i>HPS5</i> <i>HPS6</i>	Hermansky-Pudlak syndrome (HPS)	4%	<ul style="list-style-type: none"> <li>• Nearly all children w/HPS-related albinism have infantile nystagmus.</li> <li>• Hair color ranges from white to brown.</li> <li>• Skin color is generally at least a shade lighter than that of other family members.</li> <li>• Only grades 3 &amp; 4 foveal hypoplasia have been observed w/reduced visual acuity.</li> </ul>	<ul style="list-style-type: none"> <li>• Bleeding diathesis</li> <li>• In some persons, pulmonary fibrosis, granulomatous colitis, or immunodeficiency</li> </ul>
<i>LYST</i>	Chediak-Higashi syndrome	<1%	OCA features are less severe & are hence referred to as "partial" OCA.	Immunodeficiency & bleeding diathesis



Table 3. continued from previous page.

Genes	Syndrome <sup>1</sup>	% of All OCA	Ocular & Cutaneous Features	Other Clinical Features
<i>MLPH</i> <i>MYO5A</i> <i>RAB27A</i>	Griscelli syndrome (GS) (OMIM <a href="#">PS214450</a> )	<1%	<ul style="list-style-type: none"> <li>• Skin hypopigmentation w/ characteristic silvery-gray hair</li> <li>• Ocular features are variable.</li> </ul>	<p>The 3 subtypes are:</p> <ul style="list-style-type: none"> <li>• GS1: + neurologic deficits but no immunologic dysfunction</li> <li>• GS2: ± neurologic deficits; + immunologic dysfunction</li> <li>• GS3: no neurologic or immunologic deficits</li> </ul>

1. Syndromes listed in Table 3 are inherited in an autosomal recessive manner.

**Waardenburg syndrome** is an auditory-pigmentary syndrome with sensorineural hearing loss, neurologic deficits in some affected individuals, and variable hypopigmentation of hair, skin, and eyes. It is debated whether Waardenburg syndrome should be classified as a syndromic form of OCA, since all characteristic ocular features seen in OCA may not be present. See [Waardenburg Syndrome Type I](#).

### 3. Differential Diagnosis of Ocular Findings in Oculocutaneous Albinism and Ocular Albinism

**Table 4.** Disorders with Ophthalmologic Findings Overlapping Those of Nonsyndromic Oculocutaneous Albinism and Ocular Albinism

Gene(s)	Disorder	MOI	Key Features / Comment
<b>X-linked disorders</b>			
<i>CACNA1F</i> <i>NYX</i>	<a href="#">X-linked congenital stationary night blindness (CSNB)</a>	XL	Non-progressive reduced visual acuity; refractive error, most typically myopia, ranging from low (-0.25 diopters [D] to -4.75 D) to high (≥-10.00 D), but occasionally hyperopia; nystagmus; strabismus; defective dark adaptation; normal color vision; normal fundus exam
<i>FRMD7</i>	<a href="#">FRMD7-related infantile nystagmus</a>	XL	Infantile nystagmus in 1st 6 mos of life; no cutaneous or ocular hypopigmentation; typically normal foveal morphology or low-grade foveal hypoplasia
<i>OPN1LW</i> <i>OPN1MW</i>	Blue cone monochromacy (OMIM <a href="#">303700</a> )	XL	Similar features to achromatopsia but less severe; reduced visual acuity; nystagmus; myopia; color vision defects; increased sensitivity to light (photophobia)
<i>RS1</i>	<a href="#">X-linked congenital retinoschisis</a>	XL	Symmetric bilateral macular involvement w/onset in 1st decade of life (in some males as early as age 3 mos)
<b>Autosomal dominant &amp; autosomal recessive disorders</b>			
<i>ATF6</i> <i>CNGA3</i> <i>CNGB3</i> <i>GNAT2</i> <i>PDE6C</i> <i>PDE6H</i>	<a href="#">Achromatopsia</a>	AR	Reduced visual acuity; nystagmus; photophobia; hyperopia; small central scotoma; eccentric fixation; reduced or complete loss of color discrimination

Table 4. continued from previous page.

Gene(s)	Disorder	MOI	Key Features / Comment
~24 known genes incl: <i>CEP290</i> <i>CRB1</i> <i>GUCY2D</i> <i>IMPDH1</i> <i>RDH12</i> <i>RPE65</i> <i>RPGRIP1</i> <sup>1</sup>	Leber congenital amaurosis	AD AR	Severe & progressive visual impairment from birth or 1st few months of life; roving eye movements or nystagmus; poor pupillary light responses; oculodigital sign; <sup>2</sup> undetectable or severely abnormal full-field ERG
<i>GNAT1</i> <i>GNB3</i> <i>GPR179</i> <i>GRM6</i> <i>GUCY2D</i> <i>LRIT3</i> <i>PDE6B</i> <i>RHO</i> <i>SLC24A1</i> <i>TRPM1</i>	Autosomal congenital stationary night blindness (OMIM PS310500)	AD AR	Same features as X-linked CSNB; AD form tends to be milder.
<i>PAX6</i>	<i>PAX6</i> -related aniridia	AD	Isolated aniridia; infantile nystagmus; foveal hypoplasia
<i>SLC38A8</i>	FHONDA (OMIM 609218)	AR	Foveal hypoplasia, nystagmus, optic nerve decussation defects ± anterior segment dysgenesis; cutaneous & ocular hypopigmentation not present

AD = autosomal dominant; AR = autosomal recessive; ERG = electroretinogram; MOI = mode of inheritance; XL = X-linked  
 1. To date, variants in 24 genes account for 70%-80% of individuals with Leber congenital amaurosis / early-onset severe retinal dystrophy. More commonly involved genes are listed in Table 4 (see [Leber Congenital Amaurosis / Early-Onset Severe Retinal Dystrophy Overview](#)).

2. Oculodigital sign refers to poking, rubbing, and/or pressing of the eyes.

## 4. Evaluation Strategies to Identify the Genetic Cause of Oculocutaneous Albinism or Ocular Albinism in a Proband

Establishing a specific genetic cause of oculocutaneous albinism (OCA) or ocular albinism (OA) in a proband:

- Can aid in discussions of prognosis (which are beyond the scope of this *GeneReview*) and genetic counseling;
- Usually involves a medical history, physical examination, laboratory testing, family history, and genomic/genetic testing;
- Can influence treatments and surveillance of disease, particularly in syndromic forms of OCA due to implications to systemic health.

### Medical History

Individuals with OCA often present with infantile nystagmus, poor vision, and hypopigmentation (see Clinical Characteristics). Photophobia may be present.

Identifying manifestations suggestive of syndromic forms of OCA is important, as management differs between nonsyndromic OCA (see Table 2) and syndromic forms of OCA (see Table 3). Syndromic OCA is suggested when findings such as the following are present:

- Immune dysfunction

- Bleeding diathesis, including easy bruising, epistaxis, and prolonged bleeding after minor procedures or surgery
- Neurologic deficits such as developmental delay / intellectual disability and seizures
- Pulmonary fibrosis and granulomatous colitis

## Physical Examination and Clinic-Based Investigations

Detailed ophthalmologic evaluation should include refraction, best corrected visual acuity, ocular motility (strabismus and nystagmus characteristics), measurement of anomalous head posture, slit lamp examination and/or optical coherence tomography (OCT) to detect iris transillumination defects (TIDs), assessment of fundus hypopigmentation, characterization of foveal morphology using OCT, and optic nerve misrouting using visual evoked potentials (VEPs) (see Clinical Characteristics, Eyes/Vision).

Examining parents of children with OCA can also be helpful, as they may exhibit subclinical features such as low grades of iris TIDs, fundus hypopigmentation, and foveal hypoplasia [Kuht et al 2022b]. This is particularly useful when there is diagnostic uncertainty and/or limited phenotype information can be obtained from an uncooperative young child presenting with infantile nystagmus.

Similarly, unaffected female carriers of *GPR143* variants / X-linked OA can have iris TIDs, a "mud-splattered" fundus appearance, and foveal hypoplasia [Charles et al 1993, Khan et al 2018].

Due to the shared ocular and cutaneous phenotypic characteristics, differentiating between syndromic and nonsyndromic OCA can be challenging (see Clinical Characteristics).

## Family History

A three-generation family history should be taken, with attention to relatives with manifestations of OCA or OA. Note that relevant findings can be documented through direct examination and/or review of medical records, including results of molecular genetic testing. A family history consistent with X-linked inheritance (e.g., no male-to-male transmission) may be helpful in differentiating nonsyndromic *GPR143*-related OA (an X-linked disorder) from OCA.

## Molecular Genetic Testing

Molecular genetic testing approaches can include a combination of targeted testing (multigene panel and chromosomal microarray to detect recurrent deletions) and comprehensive genomic testing (exome sequencing or genome sequencing). Gene-targeted testing (see Option 1) requires the clinician to hypothesize which gene(s) are likely involved, whereas genomic testing (see Option 2) does not.

### Option 1

**A multigene panel** that includes some or all of the genes listed in Tables 2 and 3 is most likely to identify the genetic cause of the condition while limiting identification of variants of uncertain significance and pathogenic variants in genes that do not explain the underlying phenotype. Notes: (1) The genes included in the panel and the diagnostic sensitivity of the testing used for each gene vary by laboratory and are likely to change over time. (2) Some multigene panels may include genes not associated with the condition discussed in this *GeneReview*. Of note, given the rarity of some of the genes associated with OCA, some panels may not include all the genes mentioned in this overview. (3) In some laboratories, panel options may include a custom laboratory-designed panel and/or custom phenotype-focused exome analysis that includes genes specified by the clinician. (4) Methods used in a panel may include sequence analysis, deletion/duplication analysis, and/or other non-sequencing-based tests.

For an introduction to multigene panels click [here](#). More detailed information for clinicians ordering genetic tests can be found [here](#).

**Chromosomal microarray analysis (CMA)** using oligonucleotide or SNP arrays to detect large deletions/duplications that cannot be detected by sequence analysis should be considered in OCA, as several large recurrent deletions have been identified.

Note: (1) The most common *OCA2* pathogenic variant in African and African American populations is a recurrent 2.7-kb deletion spanning exon 7 of the gene. The 2.7-kb deletion is less common in the US African American population, but has been identified in the Puerto Rican population. (2) Other larger deletions including *OCA2* have been reported [Kedda et al 1994, Spritz et al 1995, Stevens et al 1995, Durham-Pierre et al 1996, Puri et al 1997, Stevens et al 1997, Kerr et al 2000, Santiago Borrero et al 2006].

For an introduction to CMA click [here](#). More detailed information for clinicians ordering genetic tests can be found [here](#).

## Option 2

**Comprehensive genomic testing** (which does not require the clinician to determine which gene[s] are likely involved) may be considered. **Exome sequencing** is most commonly used; **genome sequencing** is also possible.

For an introduction to comprehensive genomic testing click [here](#). More detailed information for clinicians ordering genomic testing can be found [here](#).

## 5. Genetic Counseling

*Genetic counseling is the process of providing individuals and families with information on the nature, mode(s) of inheritance, and implications of genetic disorders to help them make informed medical and personal decisions. The following section deals with genetic risk assessment and the use of family history and genetic testing to clarify genetic status for family members; it is not meant to address all personal, cultural, or ethical issues that may arise or to substitute for consultation with a genetics professional. —ED.*

### Mode of Inheritance

Nonsyndromic oculocutaneous albinism (OCA) caused by pathogenic variants in *TYR*, *OCA2*, *TYRP1*, *SLC45A2*, *SLC24A5*, *LRMDA (C10orf11)*, or *DCT (TYRP2)* is inherited in an autosomal recessive manner.

Ocular albinism (OA) caused by pathogenic variants in *GPR143 (OA1)* is inherited in an X-linked manner.

If an individual has a specific syndrome associated with OCA (e.g., [Hermansky-Pudlak syndrome](#) or [Chediak-Higashi syndrome](#) [see Table 3]), genetic counseling for that condition is indicated.

### Autosomal Recessive Inheritance – Risk to Family Members

#### Parents of a proband

- The parents of an affected child are presumed to be heterozygous for an OCA-causing pathogenic variant.
- If a molecular diagnosis has been established in the proband, molecular genetic testing is recommended for the parents of the proband to confirm that both parents are heterozygous for an OCA-causing pathogenic variant and to allow reliable recurrence risk assessment.
- If a pathogenic variant is detected in only one parent and parental identity testing has confirmed biological maternity and paternity, it is possible that one of the pathogenic variants identified in the proband occurred as a *de novo* event in the proband or as a postzygotic *de novo* event in a mosaic parent

[Jónsson et al 2017]. If the proband appears to have homozygous pathogenic variants (i.e., the same two pathogenic variants), additional possibilities to consider include:

- A single- or multiexon deletion in the proband that was not detected by sequence analysis and that resulted in the artifactual appearance of homozygosity;
- Uniparental isodisomy for the parental chromosome with the pathogenic variant that resulted in homozygosity for the pathogenic variant in the proband.
- Heterozygotes (carriers) are asymptomatic and are not at risk of developing the disorder.

### Sibs of a proband

- If both parents are known to be heterozygous for an OCA-causing pathogenic variant, each sib of an affected individual has at conception a 25% chance of being affected, a 50% chance of being an asymptomatic carrier, and a 25% chance of inheriting neither of the familial pathogenic variants.
- Heterozygotes (carriers) are asymptomatic and are not at risk of developing the disorder.

**Offspring of a proband.** The offspring of an individual with autosomal recessive OCA are obligate heterozygotes (carriers) for an OCA-causing pathogenic variant.

**Other family members.** Each sib of the proband's parents is at a 50% risk of being a carrier of an OCA-causing pathogenic variant.

**Carrier detection.** Carrier testing for at-risk relatives requires prior identification of the OCA-causing pathogenic variants in the family.

## X-Linked Inheritance – Risk to Family Members

### Parents of a male proband

- The father of an affected male will not have the disorder nor will he be hemizygous for the *GPR143* pathogenic variant; therefore, he does not require further evaluation/testing.
- In a family with more than one affected individual, the mother of an affected male is an obligate heterozygote. Note: If a woman has more than one affected child and no other affected relatives and if the familial pathogenic variant cannot be detected in her leukocyte DNA, she most likely has germline mosaicism.
- If a male is the only affected family member (i.e., a simplex case), the mother may be a heterozygote, the affected male may have a *de novo* pathogenic variant (in which case the mother is not a heterozygote), or the mother may have somatic/germline mosaicism.
- Molecular genetic testing of the mother is recommended to confirm her genetic status and to allow reliable recurrence risk assessment.

**Sibs of a male proband.** The risk to sibs depends on the genetic status of the mother:

- If the mother of the proband has a *GPR143* pathogenic variant, the chance of transmitting it in each pregnancy is 50%.
  - Males who inherit the pathogenic variant will be affected;
  - Females who inherit the pathogenic variant will be heterozygotes (i.e., carriers). Heterozygotes are usually not affected, although they can exhibit iris transillumination defects, a "mud-splattered" fundus appearance, and foveal hypoplasia [Charles et al 1993, Khan et al 2018].
- If the proband represents a simplex case and if the pathogenic variant cannot be detected in the leukocyte DNA of the mother, the risk to sibs is presumed to be low but greater than that of the general population because of the possibility of maternal germline mosaicism.

**Offspring of a male proband.** Affected males transmit the *GPR143* pathogenic variant to all of their daughters and none of their sons.

**Other family members.** The maternal aunts and maternal cousins of a male proband may be at risk of having a *GPR143* pathogenic variant.

Note: Molecular genetic testing may be able to identify the family member in whom a *de novo* pathogenic variant arose, information that could help determine genetic risk status of the extended family.

**Heterozygote detection.** Identification of female heterozygotes requires prior identification of the *GPR143* pathogenic variants in the family.

Note: Females who are heterozygotes (carriers) for this X-linked disorder will be heterozygotes and will usually not be affected, although they can exhibit iris transillumination defects, a "mud-splattered" fundus appearance, and foveal hypoplasia [Charles et al 1993, Khan et al 2018].

## Related Genetic Counseling Issues

### Family planning

- The optimal time for determination of genetic risk and discussion of the availability of prenatal/preimplantation genetic testing is before pregnancy.
- It is appropriate to offer genetic counseling (including discussion of potential risks to offspring and reproductive options) to young adults who are affected, are carriers, or are at risk of being carriers.

**DNA banking.** Because it is likely that testing methodology and our understanding of genes, pathogenic mechanisms, and diseases will improve in the future, consideration should be given to banking DNA from probands in whom a molecular diagnosis has not been confirmed (i.e., the causative pathogenic mechanism is unknown). For more information, see Huang et al [2022].

## Prenatal Testing and Preimplantation Genetic Testing

Once the OCA- or OA-causing pathogenic variant(s) have been identified in an affected family member, prenatal and preimplantation genetic testing are possible.

Differences in perspective may exist among medical professionals and within families regarding the use of prenatal testing. While most centers would consider use of prenatal testing to be a personal decision, discussion of these issues may be helpful.

## Resources

*GeneReviews staff has selected the following disease-specific and/or umbrella support organizations and/or registries for the benefit of individuals with this disorder and their families. GeneReviews is not responsible for the information provided by other organizations. For information on selection criteria, click [here](#).*

- **Global Albinism Alliance**  
**Email:** [info@albinismalliance.org](mailto:info@albinismalliance.org)  
[www.albinismalliance.org](http://www.albinismalliance.org)
- **National Organization for Albinism and Hypopigmentation (NOAH)**  
**Phone:** 800-473-2310 (US and Canada); 603-887-2310  
**Fax:** 603-887-6049



**Email:** [info@albinism.org](mailto:info@albinism.org)

[www.albinism.org](http://www.albinism.org)

- **American Nystagmus Network, Inc.**

[www.nystagmus.org](http://www.nystagmus.org)

- **Nystagmus Network**

United Kingdom

**Phone:** 44 1427 718093

**Email:** [info@nystagmusnet.org](mailto:info@nystagmusnet.org)

[www.nystagmusnetwork.org](http://www.nystagmusnetwork.org)

- **eyeGENE – National Ophthalmic Disease Genotyping Network Registry**

**Phone:** 301-435-3032

**Email:** [eyeGENEinfo@nei.nih.gov](mailto:eyeGENEinfo@nei.nih.gov)

<https://eyegene.nih.gov/>

## 6. Management

At present, no curative treatments are available for albinism.

Supportive treatments are aimed at optimizing vision, managing clinical manifestations (e.g., nystagmus), and reducing risks of complications of cutaneous albinism (e.g., skin cancer).

### Eyes/Vision

**Refractive errors and optimizing visual acuity.** Correction of refractive errors found in most individuals with albinism (either hyperopia or myopia and astigmatism) with spectacles or (when age appropriate) contact lenses can optimize visual acuity.

Because anisometric and ametropic amblyopia may develop in children with albinism, prompt correction of refractive errors in children to reduce risk for amblyopia is essential. If amblyopia is present following a refractive adaptation period of 16-18 weeks, occlusion therapy should commence.

Optical coherence tomography is useful in characterizing retinal development based on foveal hypoplasia grades (see Figure 1) [Thomas et al 2011b]. If there is a mismatch between the measured visual acuity and expected visual potential (based on the grade of foveal hypoplasia), other causes of reduced vision should be investigated and, if identified, treated accordingly.

Low vision aids may be useful in some individuals with albinism; these are typically issued following full refractive correction. Magnification apparatuses such as telescopes and near magnifiers may be used in individuals with significantly reduced visual acuity [Liu et al 2021].

**Management of nystagmus, strabismus, and anomalous head posture (AHP).** Vision of individuals with albinism can be improved by treatments that aim to reduce the intensity of the nystagmus, lengthen the foveation periods in the null zone (i.e., the brief period of time during nystagmus when the eyes are relatively still and visual information is captured by the fovea), or correct AHP by moving the null zone into primary position.

- **AHP** can have a significant effect on quality of life, causing neck issues, headache, and cosmetic issues. When AHP prevents children with low visual acuity from looking through their glasses, they are at risk of developing amblyopia. The Anderson-Kestenbaum procedure, the standard surgical approach for AHP, is generally performed after age two years.
- **Infantile nystagmus.** In studying the effect of gabapentin or memantine on visual function in 16 individuals with infantile nystagmus, McLean et al [2007] reported significantly improved visual acuity in individuals with idiopathic infantile nystagmus; however, the change in those with a secondary cause of nystagmus (e.g., albinism) was not statistically significant. Nonetheless, nystagmus intensity and foveation improved on eye movement recordings after medication in all individuals.

The evidence for the use of contact lenses to improve characteristics of nystagmus is unclear.

**Reducing glare.** Dark glasses or transition lenses may be helpful, but many individuals with albinism prefer to go without the tint because of the reduction in vision from the dark lenses.

A hat with a brim may be helpful to reduce overhead glare and, importantly, provide some sun protection for the face.

Other approaches to alleviate glare described in the literature with either limited success or complications arising from the intervention include surgical implants or various designs of modified contact lenses. Because the evidence level is restricted to case reports, these interventions are not recommended.

## Skin

Individuals with cutaneous albinism are encouraged to have complete skin examinations at least yearly to identify evidence of sun damage or early signs of skin cancer. At these visits, education regarding methods of sun protection is stressed, including the following:

- Wearing sun-protective clothing (wide-brimmed hats, long-sleeve shirts, and long pants) with at least a sun protection factor (SPF) of 15
- Application of sunscreens, and avoidance of midday sun exposure if possible [Guan et al 2021, Tsai & Chien 2022]
  - The general recommendation is application of sunscreen (which is at least SPF 15) every two hours to exposed skin. Although sunscreen with a higher SPF can be applied less often, adhering to a regimen of every two hours is still recommended. Of note, SPF levels above 30 tend to provide little additional protection.
  - Sunscreen comes in two different options based on the mechanism of sun protection: chemical blockers (e.g., oxybenzone, avobenzone) and physical blockers (e.g., titanium oxide, zinc oxide). In general, although the efficacy of these two options is relatively the same, use of chemical blockers is becoming restricted because of their effects on hormone-related biology and toxicity to coral reefs.
  - In addition to prevention of skin cancers, sun avoidance and use of sunscreen can also prevent early signs of sun damage and solar aging.

In most circumstances, especially when the parents do not have albinism, children with albinism are referred to a pediatric dermatologist at a young age to ensure that parents and family members are properly educated regarding sun protection.

It is problematic for individuals with albinism to self-monitor their skin. Whereas skin cancers such as squamous cell carcinoma and basal cell carcinoma are clinically the same in individuals with normal pigmentation and in individuals with albinism, melanoma is different.

Melanoma, the most dangerous of all skin cancers, is clinically diagnosed based on changes in pigmentation patterns [Tsao et al 2015]. In individuals with normal skin pigmentation, clinicians and the individuals

themselves monitor pigmented lesions for changes in symmetry, color, border, and lesion diameter to identify those suspicious for melanoma that require a biopsy for pathologic confirmation. In contrast, in individuals with albinism, melanomas lack pigment, making traditional methods for early diagnosis very difficult. For these reasons, yearly total body skin examinations by a trained dermatologist are highly recommended. A low threshold for skin biopsy is important. Treatment of skin cancer in individuals with albinism is the same as the general population.

## Educational Management

The following information represents typical management recommendations for children of school age with educational issues related to decreased visual acuity.

**Ages 0-3 years.** Referral to an early intervention program is recommended for access to special educators and sensory impairment specialists. In the US, early intervention is a federally funded program available in all states that provides in-home services to target individual therapy needs.

**Ages 3-5 years.** In the US, assessment of low vision needs and developmental assessment is recommended before entering school. Before placement, an evaluation is made to determine needed services and therapies and an individualized education plan (IEP) is developed for those who qualify based on established motor, language, social, or cognitive delay. The early intervention program typically assists with this transition. Developmental preschool is center based; for children too medically unstable to attend, home-based services are provided.

**All ages.** Consultation with a developmental pediatrician is recommended to ensure the involvement of appropriate community, state, and educational agencies (US) and to support parents in maximizing quality of life. Some issues to consider:

- IEP services:
  - An IEP provides specially designed instruction and related services to children who qualify.
  - IEP services will be reviewed annually to determine whether any changes are needed.
  - Special education law requires that children participating in an IEP be in the least restrictive environment feasible at school and included in general education as much as possible, when and where appropriate.
  - Vision and hearing consultants should be a part of the child's IEP team to support access to academic material.
  - PT, OT, and speech services will be provided in the IEP to the extent that the need affects the child's access to academic material. Beyond that, private supportive therapies based on the affected individual's needs may be considered. Specific recommendations regarding type of therapy can be made by a developmental pediatrician.
  - As a child enters the teen years, a transition plan should be discussed and incorporated in the IEP. For those receiving IEP services, the public school district is required to provide services until age 21.
- A 504 plan (Section 504: a US federal statute that prohibits discrimination based on disability) can be considered for those who require accommodations or modifications such as front-of-class seating, assistive technology devices, use of magnifiers, classroom scribes, extra time between classes, modified assignments, and enlarged text.
- Developmental Disabilities Administration (DDA) enrollment is recommended. DDA is a US public agency that provides services and support to qualified individuals. Eligibility differs by state but is typically determined by diagnosis and/or associated cognitive/adaptive disabilities.
- Families with limited income and resources may also qualify for supplemental security income (SSI) for their child with a disability.

## Surveillance

**Eyes/vision.** For children younger than age 16 years, the following evaluations are recommended annually:

- Ophthalmologic examination (including assessment of refractive errors; strabismus and/or anomalous head posture; and the need for filter glasses)
- Assessment of psychosocial needs and support
- Assessment of educational needs and support

For adults, the following evaluations are recommended:

- Ophthalmologic examinations as needed
- Review in a low vision clinic as needed

**Skin.** An annual to biennial skin examination is recommended to assess for evidence of sun-related skin damage and/or precancerous or cancerous lesions, especially in areas of high-intensity or prolonged sunlight exposure.

## Agents/Circumstances to Avoid

Prolonged unprotected sun exposure should be avoided.

## Chapter Notes

### Author Notes

Mervyn Thomas's [web page](#)

Jonathan Zippin's [web page](#)

Brian Brooks's [web page](#)

## Acknowledgments

The authors thank the patients, families, and support groups that volunteer their time and engage in research to further our understanding of albinism. The authors thank their research teams, including the Ulverscroft Eye Unit (University of Leicester, UK), Zippin Lab (Weill Cornell Medical College of Cornell University, USA), and the National Eye Institute (NIH, USA).

MT gratefully acknowledges the support from the National Institute for Health Research (CL-2017-11-003), Medical Research Council, Wellcome Trust, Fight for Sight, Ulverscroft Foundation, and the Academy of Medical Sciences.

JZ gratefully acknowledges the support from the National Institute of Arthritis, Musculoskeletal and Skin Diseases (R01-AR077664).

BB gratefully acknowledges the support from the Intramural Program at the National Eye Institute, National Institutes of Health.

## Revision History

- 13 April 2023 (bp) Review posted live
- 30 November 2022 (mt) Original submission

## References

### Literature Cited

- Abadi RV, Bjerre A. Motor and sensory characteristics of infantile nystagmus. *Br J Ophthalmol.* 2002;86:1152–60. PubMed PMID: 12234898.
- Adams DR, Menezes S, Jauregui R, Valivullah ZM, Power B, Abraham M, Jeffrey BG, Garced A, Alur RP, Cunningham D, Wiggs E, Merideth MA, Chiang PW, Bernstein S, Ito S, Wakamatsu K, Jack RM, Introne WJ, Gahl WA, Brooks BP. One-year pilot study on the effects of nitisinone on melanin in patients with OCA-1B. *JCI Insight.* 2019;4:e124387. PubMed PMID: 30674731.
- Anshelevich EE, Mosojane KI, Kenosi L, Nkomazana O, Williams VL. Factors affecting quality of life for people living with albinism in Botswana. *Dermatol Clin.* 2021;39:129–45. PubMed PMID: 33228856.
- Brodsky MC, Fray KJ. Positive angle kappa: a sign of albinism in patients with congenital nystagmus. *Am J Ophthalmol.* 2004;137:625–9. PubMed PMID: 15059699.
- Charles SJ, Green JS, Grant JW, Yates JR, Moore AT. Clinical features of affected males with X linked ocular albinism. *Br J Ophthalmol.* 1993;77:222–7. PubMed PMID: 8494858.
- Chong GT, Farsiu S, Freedman SF, Sarin N, Koreishi AF, Izatt JA, Toth CA. Abnormal foveal morphology in ocular albinism imaged with spectral-domain optical coherence tomography. *Arch Ophthalmol.* 2009;127:37–44. PubMed PMID: 19139336.
- Durham-Pierre D, King RA, Naber JM, Laken S, Brilliant MH. Estimation of carrier frequency of a 2.7 kb deletion allele of the P gene associated with OCA2 in African-Americans. *Hum Mutat.* 1996;7:370–3. PubMed PMID: 8723691.
- Franklin A, Lund P, Bradbury-Jones C, Taylor J. Children with albinism in African regions: their rights to "being" and "doing". *BMC Int Health Hum Rights.* 2018;18:2. PubMed PMID: 29329540.
- Guan LL, Lim HW, Mohammad TF. Sunscreens and photoaging: a review of current literature. *Am J Clin Dermatol.* 2021;22:819–28. PubMed PMID: 34387824.
- Hoffmann MB, Lorenz B, Morland AB, Schmidtborn LC. Misrouting of the optic nerves in albinism: estimation of the extent with visual evoked potentials. *Invest Ophthalmol Vis Sci.* 2005;46:3892–8. PubMed PMID: 16186379.
- Huang SJ, Amendola LM, Sternen DL. Variation among DNA banking consent forms: points for clinicians to bank on. *J Community Genet.* 2022;13:389–97. PubMed PMID: 35834113.
- Hutton SM, Spritz RA. A comprehensive genetic study of autosomal recessive ocular albinism in Caucasian patients. *Invest Ophthalmol Vis Sci.* 2008;49:868–72. PubMed PMID: 18326704.
- Jónsson H, Sulem P, Kehr B, Kristmundsdottir S, Zink F, Hjartarson E, Hardarson MT, Hjorleifsson KE, Eggertsson HP, Gudjonsson SA, Ward LD, Arnadottir GA, Helgason EA, Helgason H, Gylfason A, Jonasdottir A, Jonasdottir A, Rafnar T, Frigge M, Stacey SN, Th Magnusson O, Thorsteinsdottir U, Masson G, Kong A, Halldorsson BV, Helgason A, Gudbjartsson DF, Stefansson K. Parental influence on human germline de novo mutations in 1,548 trios from Iceland. *Nature.* 2017;549:519–22. PubMed PMID: 28959963.
- Kedda MA, Stevens G, Manga P, Viljoen C, Jenkins T, Ramsay M. The tyrosinase-positive oculocutaneous albinism gene shows locus homogeneity on chromosome 15q11-q13 and evidence of multiple mutations in southern African negroids. *Am J Hum Genet.* 1994;54:1078–84. PubMed PMID: 8198130.
- Kerr R, Stevens G, Manga P, Salm S, John P, Haw T, Ramsay M. Identification of P gene mutations in individuals with oculocutaneous albinism in sub-Saharan Africa. *Hum Mutat.* 2000;15:166–72. PubMed PMID: 10649493.

- Khan KN, Lord EC, Arno G, Islam F, Carss KJ, Raymond F, Toomes C, Ali M, Inglehearn CF, Webster AR, Moore AT, Poulter JA, Michaelides M. Detailed retinal imaging in carriers of ocular albinism. *Retina*. 2018;38:620–8. PubMed PMID: 28234808.
- King RA, Lewis RA, Townsend D, Zelickson A, Olds DP, Brumbaugh J. Brown oculocutaneous albinism. Clinical, ophthalmological, and biochemical characterization. *Ophthalmology*. 1985;92:1496–505. PubMed PMID: 3935994.
- Kruijt CC, de Wit GC, Bergen AA, Florijn RJ, Schalijs-Delfos NE, van Genderen MM. The phenotypic spectrum of albinism. *Ophthalmology*. 2018;125:1953–60. PubMed PMID: 30098354.
- Kruijt CC, de Wit GC, Talsma HE, Schalijs-Delfos NE, van Genderen MM. The detection of misrouting in albinism: evaluation of different VEP procedures in a heterogeneous cohort. *Invest Ophthalmol Vis Sci*. 2019;60:3963–9. PubMed PMID: 31560370.
- Kruijt CC, Gradstein L, Bergen AA, Florijn RJ, Arveiler B, Lasseaux E, Zanlonghi X, Bagdonaite-Bejarano L, Fulton AB, Yahalom C, Blumenfeld A, Perez Y, Birk OS, de Wit GC, Schalijs-Delfos NE, van Genderen MM. The phenotypic and mutational spectrum of the FHONDA syndrome and oculocutaneous albinism: similarities and differences. *Invest Ophthalmol Vis Sci*. 2022;63:19.
- Kruijt CC, Schalijs-Delfos NE, de Wit GC, Florijn RJ, van Genderen MM. Evident hypopigmentation without other ocular deficits in Dutch patients with oculocutaneous albinism type 4. *Sci Rep*. 2021;11:11572. PubMed PMID: 34078970.
- Krutmann J, Schalka S, Watson REB, Wei L, Morita A. Daily photoprotection to prevent photoaging. *Photodermatol Photoimmunol Photomed*. 2021;37:482–9. PubMed PMID: 33896049.
- Kuht HJ, Han J, Maconachie GDE, Park SE, Lee ST, McLean R, Sheth V, Hisaund M, Dawar B, Sylvius N, Mahmood U, Proudlock FA, Gottlob I, Lim HT, Thomas MG. SLC38A8 mutations result in arrested retinal development with loss of cone photoreceptor specialization. *Hum Mol Genet*. 2020;29:2989–3002. PubMed PMID: 32744312.
- Kuht HJ, Maconachie GDE, Han J, Kessel L, van Genderen MM, McLean RJ, Hisaund M, Tu Z, Hertle RW, Gronskov K, Bai D, Wei A, Li W, Jiao Y, Smirnov V, Choi JH, Tobin MD, Sheth V, Purohit R, Dawar B, Girach A, Strul S, May L, Chen FK, Heath Jeffery RC, Aamir A, Sano R, Jin J, Brooks BP, Kohl S, Arveiler B, Montoliu L, Engle EC, Proudlock FA, Nishad G, Pani P, Varma G, Gottlob I, Thomas MG. Genotypic and phenotypic spectrum of foveal hypoplasia: a multicenter study. *Ophthalmology*. 2022a;129:708–18. PubMed PMID: 35157951.
- Kuht HJ, Thomas MG, McLean RJ, Sheth V, Proudlock FA, Gottlob I. Abnormal foveal morphology in carriers of oculocutaneous albinism. *Br J Ophthalmol*. 2022b. Epub ahead of print.
- Kumar A, Gottlob I, McLean RJ, Thomas S, Thomas MG, Proudlock FA. Clinical and oculomotor characteristics of albinism compared to FRMD7 associated infantile nystagmus. *Invest Ophthalmol Vis Sci*. 2011;52:2306–13. PubMed PMID: 21220551.
- Lasseaux E, Plaisant C, Michaud V, Pennamen P, Trimouille A, Gaston L, Monfermé S, Lacombe D, Rooryck C, Morice-Picard F, Arveiler B. Molecular characterization of a series of 990 index patients with albinism. *Pigment Cell Melanoma Res*. 2018;31:466–74. PubMed PMID: 29345414.
- Liu S, Kuht HJ, Moon EH, Maconachie GDE, Thomas MG. Current and emerging treatments for albinism. *Surv Ophthalmol*. 2021;66:362–77. PubMed PMID: 33129801.
- Ma EZ, Zhou AE, Hoegler KM, Khachemoune A. Oculocutaneous albinism: epidemiology, genetics, skin manifestation, and psychosocial issues. *Arch Dermatol Res*. 2023;315:107–16. PubMed PMID: 35217926.
- Manga P, Kromberg J, Turner A, Jenkins T, Ramsay M. In Southern Africa, brown oculocutaneous albinism (BOCA) maps to the OCA2 locus on chromosome 15q: P-gene mutations identified. *Am J Hum Genet*. 2001;68:782–7. PubMed PMID: 11179026.



- Marçon CR, Maia M. Albinism: epidemiology, genetics, cutaneous characterization, psychosocial factors. *An Bras Dermatol*. 2019;94:503–20. PubMed PMID: 31777350.
- McLean R, Proudlock F, Thomas S, Degg C, Gottlob I. Congenital nystagmus: randomized, controlled, double-masked trial of memantine/gabapentin. *Ann Neurol*. 2007;61:130–8. PubMed PMID: 17279539.
- Mohammad S, Gottlob I, Kumar A, Thomas M, Degg C, Sheth V, Proudlock FA. The functional significance of foveal abnormalities in albinism measured using spectral-domain optical coherence tomography. *Ophthalmology*. 2011;118:1645–52. PubMed PMID: 21570122.
- Mohammad S, Gottlob I, Sheth V, Pilat A, Lee H, Pollheimer E, Proudlock FA. Characterization of abnormal optic nerve head morphology in albinism using optical coherence tomography. *Invest Ophthalmol Vis Sci*. 2015;56:4611–8. PubMed PMID: 26200501.
- Nakkazi E. People with albinism in Africa: contending with skin cancer. *Lancet*. 2019;394:553–4. PubMed PMID: 31423986.
- Puri N, Durban-Pierre D, Aquaron R, Lund PM, King RA, Brilliant MH. Type 2 oculocutaneous albinism (OCA2) in Zimbabwe and Cameroon: distribution of the 2.7-kb deletion allele of the P gene. *Hum Genet*. 1997;100:651–6. PubMed PMID: 9341887.
- Rufai SR, Thomas MG, Purohit R, Bunce C, Lee H, Proudlock FA, Gottlob I. Can structural grading of foveal hypoplasia predict future vision in infantile nystagmus? A longitudinal study. *Ophthalmology*. 2020;127:492–500. PubMed PMID: 31937464.
- Santiago Borrero PJ, Rodriguez-Perez Y, Renta JY, Izquierdo NJ, Del Fierro L, Munoz D, Molina NL, Ramirez S, Pagan-Mercado G, Ortiz I, Rivera-Caragol E, Spritz RA, Cadilla CL. Genetic testing for oculocutaneous albinism type 1 and 2 and Hermansky-Pudlak syndrome type 1 and 3 mutations in Puerto Rico. *J Invest Dermatol*. 2006;126:85–90. PubMed PMID: 16417222.
- Schatz MP, Pollock SC. 1994. Optic disc morphology in albinism. North American Neuro-Ophthalmology Society meeting, Durango, CO, February 27-March 3.
- Schmitz B, Schaefer T, Krick CM, Reith W, Backens M, Käsmann-Kellner B. Configuration of the optic chiasm in humans with albinism as revealed by magnetic resonance imaging. *Invest Ophthalmol Vis Sci*. 2003;44:16–21. PubMed PMID: 12506050.
- Sheth V, Gottlob I, Mohammad S, McLean RJ, Maconachie GD, Kumar A, Degg C, Proudlock FA. Diagnostic potential of iris cross-sectional imaging in albinism using optical coherence tomography. *Ophthalmology*. 2013;120:2082–90. PubMed PMID: 23725737.
- Sjödell L, Sjöström A, Abrahamsson M. Transillumination of iris and subnormal visual acuity--ocular albinism? *Br J Ophthalmol*. 1996;80:617–23. PubMed PMID: 8795373.
- Spritz RA, Fukai K, Holmes SA, Luande J. Frequent intragenic deletion of the P gene in Tanzanian patients with type II oculocutaneous albinism (OCA2). *Am J Hum Genet*. 1995;56:1320–3. PubMed PMID: 7762554.
- Stevens G, Ramsay M, Jenkins T. Oculocutaneous albinism (OCA2) in sub-Saharan Africa: distribution of the common 2.7-kb P gene deletion mutation. *Hum Genet*. 1997;99:523–7. PubMed PMID: 9099845.
- Stevens G, van Beukering J, Jenkins T, Ramsay M. An intragenic deletion of the P gene is the common mutation causing tyrosinase-positive oculocutaneous albinism in southern African Negroids. *Am J Hum Genet*. 1995;56:586–91. PubMed PMID: 7887411.
- Summers CG, Knobloch WH, Witkop CJ Jr, King RA. Hermansky-Pudlak syndrome. Ophthalmic findings. *Ophthalmology*. 1988;95:545–54. PubMed PMID: 3174014.
- Thomas MG, Kumar A, Kohl S, Proudlock FA, Gottlob I. High-resolution in vivo imaging in achromatopsia. *Ophthalmology*. 2011a;118:882–7. PubMed PMID: 21211844.

- Thomas MG, Kumar A, Mohammad S, Proudlock FA, Engle EC, Andrews C, Chan WM, Thomas S, Gottlob I. Structural grading of foveal hypoplasia using spectral-domain optical coherence tomography a predictor of visual acuity? *Ophthalmology*. 2011b;118:1653–60. PubMed PMID: 21529956.
- Tsai J, Chien AL. Photoprotection for Skin of Color. *Am J Clin Dermatol*. 2022;23:195–205. PubMed PMID: 35044638.
- Tsao H, Olazagasti JM, Cordero KM, Brewer JD, Taylor SC, Bordeaux JS, Chren MM, Sober AJ, Tegeler C, Bhushan R, Begolka WS, et al. Early detection of melanoma: reviewing the ABCDEs. *J Am Acad Dermatol*. 2015;72:717–23. PubMed PMID: 25698455.
- Wildsoet CF, Oswald PJ, Clark S. Albinism: its implications for refractive development. *Invest Ophthalmol Vis Sci*. 2000;41:1–7. PubMed PMID: 10634592.
- Wilk MA, Wilk BM, Langlo CS, Cooper RF, Carroll J. Evaluating outer segment length as a surrogate measure of peak foveal cone density. *Vision Res*. 2017;130:57–66. PubMed PMID: 27887888.
- Yahalom C, Tzur V, Blumenfeld A, Greifner G, Eli D, Rosenmann A, Glanzer S, Anteby I. Refractive profile in oculocutaneous albinism and its correlation with final visual outcome. *Br J Ophthalmol*. 2012;96:537–9. PubMed PMID: 22133989.

## License

GeneReviews® chapters are owned by the University of Washington. Permission is hereby granted to reproduce, distribute, and translate copies of content materials for noncommercial research purposes only, provided that (i) credit for source (<http://www.genereviews.org/>) and copyright (© 1993-2024 University of Washington) are included with each copy; (ii) a link to the original material is provided whenever the material is published elsewhere on the Web; and (iii) reproducers, distributors, and/or translators comply with the [GeneReviews® Copyright Notice and Usage Disclaimer](#). No further modifications are allowed. For clarity, excerpts of GeneReviews chapters for use in lab reports and clinic notes are a permitted use.

For more information, see the [GeneReviews® Copyright Notice and Usage Disclaimer](#).

For questions regarding permissions or whether a specified use is allowed, contact: [admasst@uw.edu](mailto:admasst@uw.edu).