U.S. National Library of Medicine
National Center for Biotechnology Information

NLM Citation: Superti-Furga A, Unger S. Chondrodysplasia with Congenital Joint Dislocations, *CHST3*-Related. 2011 Sep 1 [Updated 2024 Aug 1]. In: Adam MP, Feldman J, Mirzaa GM, et al., editors. GeneReviews® [Internet]. Seattle (WA): University of Washington, Seattle; 1993-2024.
Bookshelf URL: https://www.ncbi.nlm.nih.gov/books/

Chondrodysplasia with Congenital Joint Dislocations, *CHST3*-Related

Synonyms: CHST3 Deficiency, *CHST3*-Related Skeletal Dysplasia, Recessive Larsen Syndrome

Andrea Superti-Furga, MD[1] and Sheila Unger, MD[2]

Created: September 1, 2011; Updated: August 1, 2024.

Summary

Clinical characteristics

Chondrodysplasia with congenital joint dislocations, *CHST3*-related (CDCJD-*CHST3*) is characterized by short stature of prenatal onset, joint dislocations (knees, hips, radial heads), clubfeet, and limitation of range of motion that can involve all large joints. Kyphosis and occasionally scoliosis with slight shortening of the trunk develop in childhood. Minor heart valve dysplasia has been described in several persons. Intellect and vision are normal.

Diagnosis/testing

The diagnosis of CDCJD-*CHST3* is established in a proband with characteristic clinical and radiographic features and biallelic pathogenic variants in *CHST3* identified by molecular genetic testing.

Management

Treatment of manifestations: Surgical correction of the abnormal joints is the only treatment modality; however, surgical correction is often only partially successful and multiple procedures are needed. Physical therapy has not been effective. Treatment of cardiac manifestations as needed per cardiologist; treatment of dental anomalies as needed per dentist.

Surveillance: Clinical joint and spine evaluation with orthopedist with experience in skeletal dysplasia; radiographs as recommended per orthopedist; if normal at the time of diagnosis, echocardiogram should be repeated per cardiologist or every five years; follow up with dentist annually or as needed.

Agents/circumstances to avoid: Activities with a high impact on joints (e.g., jogging) and obesity.

Author Affiliations: 1 Professor, Division of Genetic Medicine, University of Lausanne; Genetica AG, Lausanne, Switzerland; Email: asuperti@unil.ch. 2 Genetica AG, Lausanne, Switzerland; Email: s.unger@genetica.ch.

Copyright © 1993-2024, University of Washington, Seattle. GeneReviews is a registered trademark of the University of Washington, Seattle. All rights reserved.

Genetic counseling

CDCJD-*CHST3* is inherited in an autosomal recessive manner. If both parents are known to be heterozygous for a *CHST3* pathogenic variant, each sib of an affected individual has a 25% chance at conception of being affected, a 50% chance of being an asymptomatic carrier, and a 25% chance of being unaffected and not a carrier. Once the *CHST3* pathogenic variants have been identified in an affected family member, carrier testing for at-risk family members and prenatal/preimplantation genetic testing for a pregnancy at increased risk are possible.

Diagnosis

Suggestive Findings

Chondrodysplasia with congenital joint dislocations, *CHST3*-related (CDCJD-*CHST3*) **should be suspected** in individuals with the following clinical radiographic features and family history.

Clinical features

- Joint dislocations at birth (knees, hips, radial heads) with short stature (See Figure 1.)
- Clubfeet
- Limitation of range of motion that can involve all large joints
- Development of kyphosis and occasionally scoliosis with slight shortening of the trunk in childhood

Radiographic features

- Progressive spondyloepiphyseal dysplasia with joint anomalies
  - Generalized mild epiphyseal dysplasia (small epiphyses)
  - Delayed ossification of the capital femoral epiphyses and femoral necks
  - Coxa valga (increase in the angle formed between the head and neck of the femur and the shaft of the femur)
- Spinal abnormalities
  - Conspicuous increase in interpediculate distance from T12 to L1 or L2 (See Figure 2.)
  - Notching of the vertebral bodies, similar in appearance to coronal clefts (See Figure 3.)
- Normal thumbs (not spatulate)
- Normal or (more rarely) slightly advanced bone age (especially carpal)

Family history is consistent with autosomal recessive inheritance (e.g., affected sibs and/or parental consanguinity). Absence of a known family history does not preclude the diagnosis.

Establishing the Diagnosis

The diagnosis of CDCJD-*CHST3* **is established** in a proband with suggestive findings and biallelic pathogenic (or likely pathogenic) variants in *CHST3* identified by molecular genetic testing (see Table 1).

Note: (1) Per ACMG/AMP variant interpretation guidelines, the terms "pathogenic variant" and "likely pathogenic variant" are synonymous in a clinical setting, meaning that both are considered diagnostic and can be used for clinical decision making [Richards et al 2015]. Reference to "pathogenic variants" in this *GeneReview* is understood to include likely pathogenic variants. (2) Identification of biallelic *CHST3* variants of uncertain significance (or of one known *CHST3* pathogenic variant and one *CHST3* variant of uncertain significance) does not establish or rule out the diagnosis.

Molecular genetic testing approaches can include a combination of **gene-targeted testing** (single gene testing, multigene panel) and **comprehensive genomic testing** (exome sequencing, genome sequencing). Gene-targeted

Figure 1. A newborn with chondrodysplasia with congenital joint dislocations, *CHST3*-related. Note the bilateral dislocation of the knees and radial heads.

testing requires that the clinician determine which gene(s) are likely involved (see Option 1), whereas comprehensive genomic testing does not (see Option 2).

Option 1

Single-gene testing. Sequence analysis of *CHST3* is performed first to detect missense, nonsense, and splice site variants and small intragenic deletions/insertions. Note: Depending on the sequencing method used, single-exon, multiexon, or whole-gene deletions/duplications may not be detected. If only one or no variant is detected by the sequencing method used, the next step is to perform gene-targeted deletion/duplication analysis to detect exon and whole-gene deletions or duplications.

A skeletal dysplasia or skeletal dysplasia with multiple dislocations multigene panel that includes *CHST3* and other genes of interest (see Differential Diagnosis) may be considered to identify the genetic cause of the condition while limiting identification of variants of uncertain significance and pathogenic variants in genes that do not explain the underlying phenotype. Note: (1) The genes included in the panel and the diagnostic sensitivity of the testing used for each gene vary by laboratory and are likely to change over time. (2) Some multigene panels may include genes not associated with the condition discussed in this *GeneReview*. (3) In some laboratories, panel options may include a custom laboratory-designed panel and/or custom phenotype-focused exome analysis that includes genes specified by the clinician. (4) Methods used in a panel may include sequence analysis, deletion/duplication analysis, and/or other non-sequencing-based tests.

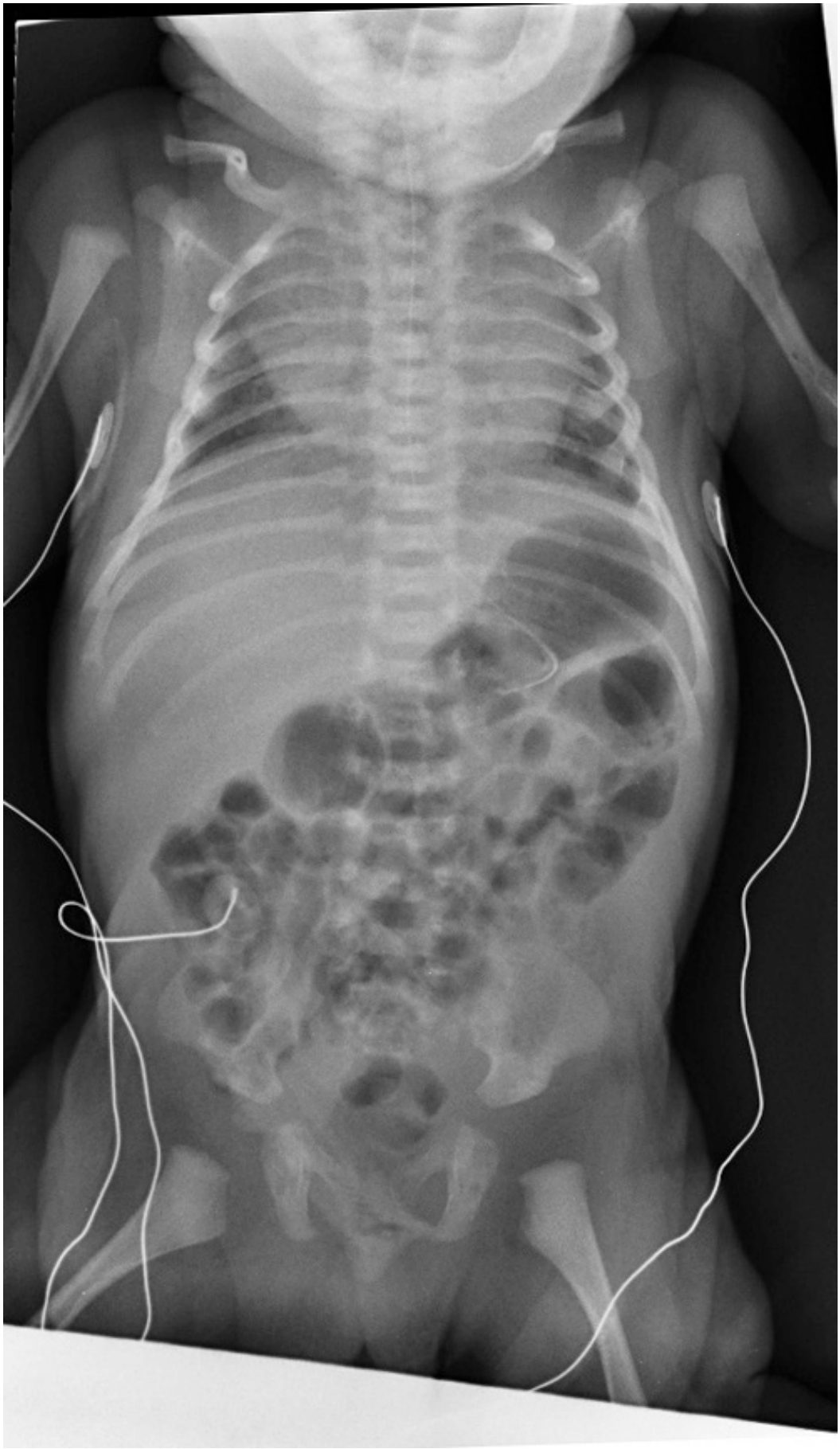

Figure 2. An individual with chondrodysplasia with congenital joint dislocations, *CHST3*-related. Note the conspicuous increase in

interpediculate distance from T12 to L1. Also appreciable is the bilateral hip subluxation.

Figure 3. An individual with chondrodysplasia with congenital joint dislocations, *CHST3*-related. Mild platyspondyly is observed. Note also the coronal clefts throughout the lumbar region.

For an introduction to multigene panels click here. More detailed information for clinicians ordering genetic tests can be found here.

Option 2

Comprehensive genomic testing does not require the clinician to determine which gene is likely involved. **Exome sequencing** is most commonly used; **genome sequencing** is also possible. To date, the majority of *CHST3* pathogenic variants reported (e.g., missense, nonsense) are within the coding region and are likely to be identified on exome sequencing.

For an introduction to comprehensive genomic testing click here. More detailed information for clinicians ordering genomic testing can be found here.

Table 1. Molecular Genetic Testing Used in Chondrodysplasia with Congenital Joint Dislocations, *CHST3*-Related

Gene [1]	Method	Proportion of Pathogenic Variants [2] Identified by Method
CHST3	Sequence analysis [3]	>99%
	Gene-targeted deletion/duplication analysis [4]	1 reported [5]

1. See Table A. Genes and Databases for chromosome locus and protein.
2. See Molecular Genetics for information on variants in this gene.
3. Sequence analysis detects variants that are benign, likely benign, of uncertain significance, likely pathogenic, or pathogenic. Variants may include missense, nonsense, and splice site variants and small intragenic deletions/insertions; typically, exon or whole-gene deletions/duplications are not detected. For issues to consider in interpretation of sequence analysis results, click here.
4. Gene-targeted deletion/duplication analysis detects intragenic deletions or duplications. Methods used may include a range of techniques such as quantitative PCR, long-range PCR, multiplex ligation-dependent probe amplification (MLPA), and a gene-targeted microarray designed to detect single-exon deletions or duplications. Exome and genome sequencing may be able to detect deletions/duplications using breakpoint detection or read depth; however, sensitivity can be lower than gene-targeted deletion/duplication analysis.
5. Ranza et al [2017]

Biochemical Testing

Cultured fibroblasts can be used to determine proteoglycan sulfation (i.e., sulfotransferase activity). The fibroblasts are incubated with radioactive sulfate [^{35}S] and chondroitin. In all individuals with CHST3 deficiency studied thus far, the incorporation of sulfate at the C6 position was dramatically decreased while incorporation at the C4 position was within normal levels [Hermanns et al 2008, van Roij et al 2008]. This test requires a skin biopsy and a specialist laboratory and thus is more invasive and less widely available than molecular genetic testing. Biochemical testing can be useful in those individuals in which pathogenic variants are not identified or variants of uncertain significance have been detected. The diminished sulfation at carbon 6 of proteoglycans offers unambiguous evidence of CHST3 deficiency.

Clinical Characteristics

Clinical Description

Most children with chondrodysplasia with congenital joint dislocations, *CHST3*-related (CDCJD-*CHST3*) are identified at birth as having a generalized skeletal disorder. The features of this disorder are generally limited to the skeleton and joints and are progressive in nature.

Occasionally, short stature and knee dislocations are seen on prenatal ultrasound examination [Unger et al 2010]. The prenatal presentation may be that of arthrogryposis [Muys et al 2017].

At birth, affected infants are noted to have short stature (birth length: 39-44 cm) and joint dislocations; the large majority have bilateral knee luxation or subluxation. The radial heads and hips are the next most commonly affected joints. Clubfeet are also frequently seen. Despite the congenital joint dislocations, the overall phenotype is one of restricted movement, and many children undergo multiple corrective procedures with only limited success [Rajab et al 2004, Unger et al 2010, Searle et al 2014].

In a large family reported from Oman, the adult heights ranged from 110 cm to 130 cm [Rajab et al 2004], while in a large Pakistani family the mean adult height was 84 cm [Waryah et al 2016]. A review article included information on three adults with heights of 117 cm, 121 cm, and 134.5 cm [Unger et al 2010]. Adult height

appears to be severely affected in all individuals with CDCJD-*CHST3*, but with some intrafamilial variability and large interfamilial variability.

Many adults develop arthritic-type changes. They also develop spinal kyphosis, frequently in the cervical spine, and (rarely) scoliosis.

Cardiac manifestations. Minor heart valve dysplasia with valvular insufficiency has been described in multiple reports, including one in the kindred from Oman [Hall 1997, Rajab et al 2004, Tuysuz et al 2009, Otaify et al 2023, Singh et al 2024]. There are occasional reports of structural cardiac malformations such as atrial septal defect, but it is not yet clear if *CHST3* pathogenic variants are causally linked [Otaify et al 2023].

Tooth anomalies (microdontia, delayed eruption) have been reported in the large Omani kindred as well as several individuals from Egypt [Rajab et al 2004, Otaify et al 2023].

Intellect, vision, and hearing is usually normal [Unger et al 2010, Singh et al 2024]. However, in a large Pakistani kindred, at least six affected individuals also had mixed hearing loss; thus, this may be an associated feature [Waryah et al 2016]. One additional individual of Pakistani origin was reported to have mild bilateral hearing loss on audiometry but no clinical signs of hearing impairment [Kausar et al 2022].

Other. Sagittal craniosynostosis has been reported in a single individual [Searle et al 2014], while "sclerosis of sutures" was reported in three unrelated individuals [Srivastava et al 2017].

Genotype-Phenotype Correlations

No genotype-phenotype correlations have been observed. The phenotype reported thus far has been strikingly homogeneous regardless of type of *CHST3* pathogenic variant [Unger et al 2010]. Persons with homozygous pathogenic missense variants are no less severely affected than those with nonsense variants.

Nomenclature

In 1950, Dr LJ Larsen described autosomal dominant Larsen syndrome, now known to be caused by pathogenic variants in *FLNB*. Larsen syndrome is characterized by multiple joint dislocations, dysmorphic facial features, spatulate thumbs, and accelerated carpal ossification (see *FLNB*-Related Disorders). Following the delineation of autosomal dominant Larsen syndrome, several reports of "autosomal recessive Larsen syndrome" and other similar disorders were published. By careful reevaluation of affected individuals and through recruitment of individuals with autosomal recessive Larsen syndrome, several investigators showed that, in fact, all the various reports of autosomal recessive Larsen syndrome, humerospinal dysostosis, and spondyloepiphyseal dysplasia (SED), Omani type could be attributed to CHST3 deficiency and that the different names had arisen from the part of the phenotype the various authors had emphasized [Hermanns et al 2008, Unger et al 2010]; that is, they were describing the same condition from different viewpoints.

- Humerospinal dysostosis was described by Kozlowski et al [1974] in two brothers with joint dislocations and radiographic abnormalities (bifid humeri and coronal clefts). Because the brothers were reported to be half-sibs, autosomal dominant inheritance was suspected and no link was made to autosomal recessive Larsen syndrome.
- Mégarbané and Ghanem [2004] described "a newly recognized chondrodysplasia with joint dislocations." Although they made the link to humerospinal dysostosis, they rejected that diagnosis because the evidence strongly suggested autosomal recessive inheritance.
- Rajab et al [2004] described a large family originating from Oman with what they termed "a new recessive type of SED with progressive spinal involvement." The same group went on to demonstrate that the disorder was caused by CHST3 deficiency and renamed the disorder SED, Omani type [Thiele et al 2004].

The name "chondrodysplasia with congenital joint dislocations, *CHST3*-related (CDCJD-*CHST3*)" has been proposed as an unbiased and inclusive designation for this disorder and is the current designation used in the Nosology of Genetic Skeletal Disorders [Unger et al 2023]. However, an argument could also be made for retaining the name "autosomal recessive Larsen syndrome," as the joint dislocations are the presenting feature and "Larsen syndrome" is usually the first diagnosis considered; thus, the continued use of this designation is open to debate. The term "recessive Larsen syndrome" is more appropriate for CDCJD-*CHST3* than for the *B4GALT7*-associated linkeropathy, as bilateral knee dislocation at birth is much more common in CHST3 deficiency than in B4GALT7 deficiency.

Prevalence

No firm data regarding the prevalence of CDCJD-*CHST3* are available. More than 100 probands (including familial recurrences) have been reported, with many of these individuals from consanguineous families.

Genetically Related (Allelic) Disorders

No phenotypes other than those discussed in this *GeneReview* are known to be associated with germline pathogenic variants in *CHST3*.

Differential Diagnosis

A summary of key differentiating clinical and radiographic features for chondrodysplasias with multiple dislocations is available in Ranza et al [2017]. Selected genes of interest in the differential diagnosis are listed in Table 2.

Table 2. Genes of Interest in the Differential Diagnosis of Chondrodysplasia with Congenital Joint Dislocations, *CHST3*-Related

<table>
<tr><th rowspan="2">Gene</th><th rowspan="2">Disorder [1]</th><th rowspan="2">MOI</th><th colspan="2">Features of Disorder</th></tr>
<tr><th>Overlapping w/ CDCJD-CHST3</th><th>Distinguishing from CDCJD-CHST3</th></tr>
<tr><td>B3GALT6</td><td>SEMD w/joint laxity (Beighton type), B3GALT6-related (Ehlers-Danlos syndrome, spondylodysplastic type 2) (OMIM 271640)</td><td>AR</td><td rowspan="3">• Prenatal-onset short stature
• Joint dislocations</td><td rowspan="2">• Advanced bone age
• Lacks characteristic CDCJD-CHST3 spine findings</td></tr>
<tr><td>B4GALT7</td><td>Ehlers-Danlos syndrome, spondylodysplastic type 1, B4GALT7-related (OMIM 130070) [2]</td><td>AR</td></tr>
<tr><td>B3GAT3</td><td>Multiple joint dislocations, B3GAT3-related (OMIM 245600)</td><td>AR</td><td>• Osteoporosis & fractures in some
• Distinctive facial features w/ protuberant eyes</td></tr>
<tr><td>CANT1</td><td>Desbuquois dysplasia (w/accessory ossification center in digit 2), CANT1-related (OMIM 251450)</td><td>AR</td><td>• Prenatal-onset short stature
• Joint dislocations
• Multiple coronal clefts on lateral spine radiograph</td><td>• Distinctive facial features (marked midface hypoplasia, prominent eyes)
• Advanced bone age</td></tr>
<tr><td>CSGALNACT1</td><td>Skeletal dysplasia w/joint laxity & advanced bone age, CSGALNACT1-related (OMIM 618870)</td><td>AR</td><td>• Prenatal-onset short stature
• Joint laxity</td><td>Joint laxity is prominent but persons may not have dislocations.</td></tr>
</table>

Table 2. continued from previous page.

Gene	Disorder [1]	MOI	Features of Disorder	
			Overlapping w/ CDCJD-*CHST3*	Distinguishing from CDCJD-*CHST3*
EXOC6B	SEMD w/joint laxity, *EXOC6B*-related	AR	• Multiple joint dislocations • Scoliosis & kyphosis	• Normal birth length • Very delayed proximal carpal ossification
FLNB	Larsen syndrome, *FLNB*-related (See *FLNB*-Related Disorders.)	AD	Multiple dislocations	• Normal birth length • Distinctive facial features w/↑ incidence of cleft palate • Advanced bone age
KIF22	SEMD w/joint laxity (Hall type or leptodactylic type), *KIF22*-related (OMIM 603546)	AD		Distinctive facial features
SLC10A7	Skeletal dysplasia w/joint dislocations & amelogenesis imperfecta, *SLC10A7*-related (OMIM 618363)	AR	• Prenatal-onset short stature • Multiple dislocations	• Amelogenesis • Advanced carpal ossification
SLC26A2	Diastrophic dysplasia, *SLC26A2*-related	AR	• Short limbs • Clubfeet • Joint stiffness / limited mobility	• Hitchhiker thumb • Lacks characteristic CDCJD-*CHST3* spine findings
XYLT1	Baratela-Scott syndrome, *XYLT1*-related (OMIM 615777)	AR	• Prenatal-onset short stature • Joint dislocations • Multiple coronal clefts on lateral spine radiograph	• Distinctive facial features (marked midface hypoplasia, prominent eyes) • Advanced bone age

AD = autosomal dominant; AR = autosomal recessive; MOI = mode of inheritance; SEMD = spondyloepimetaphyseal dysplasia
1. Disorder terminology is based on the 2023 revision of the Nosology of Genetic Skeletal Disorders [Unger et al 2023].
2. The La Réunion variant of recessive Larsen syndrome is caused by a specific *B4GALT7* pathogenic variant [Cartault et al 2015].

Management

No clinical practice guidelines for chondrodysplasia with congenital joint dislocations, *CHST3*-related (CDCJD-*CHST3*) have been published. In the absence of published guidelines, the following recommendations are based on the authors' personal experience managing individuals with this disorder.

Evaluations Following Initial Diagnosis

To establish the extent of disease in an individual diagnosed with CDCJD-*CHST3*, the evaluations summarized in Table 3 (if not performed as part of the evaluation that led to the diagnosis) are recommended.

Table 3. Chondrodysplasia with Congenital Joint Dislocations, *CHST3*-Related: Recommended Evaluations Following Initial Diagnosis

System/Concern	Evaluation	Comment
Skeletal	• Orthopedic referral • Referral to specialized skeletal dysplasia clinic if available • Radiographs per orthopedist	
Cardiac	Echocardiogram	

Table 3. continued from previous page.

System/Concern	Evaluation	Comment
Genetic counseling	By genetics professionals [1]	To obtain a pedigree & inform affected persons & their families re nature, MOI, & implications of CDCJD-*CHST3* to facilitate medical & personal decision making

MOI = mode of inheritance
1. Medical geneticist, certified genetic counselor, certified advanced genetic nurse

Treatment of Manifestations

Supportive care to improve quality of life, maximize function, and reduce complications is recommended. This ideally involves multidisciplinary care by specialists in relevant fields (see Table 4).

Table 4. Chondrodysplasia with Congenital Joint Dislocations, *CHST3*-Related: Treatment of Manifestations

Manifestation/ Concern	Treatment	Considerations/Other
Skeletal	Treatment for joint & spine manifestations per orthopedist w/experience in skeletal dysplasia	• Surgical correction is often only partially successful for joint dislocations & most persons have had multiple procedures by adulthood [Unger et al 2010]. • Physical therapy has not been demonstrated to be effective in this disorder.
Cardiac	Treatment of cardiac disease per cardiologist & cardiothoracic surgeon	
Dental	Treatment of dental manifestations per dentist & orthodontist	

Surveillance

To monitor existing manifestations, the individual's response to supportive care, and the emergence of new manifestations, the evaluations summarized in Table 5 are recommended.

Table 5. Chondrodysplasia with Congenital Joint Dislocations, *CHST3*-Related: Recommended Surveillance

System/Concern	Evaluation	Frequency
Skeletal	• Clinical joint & spine eval w/orthopedist w/experience in skeletal dysplasia • Radiographs as recommended by orthopedist	Individualized depending on progression or stability of findings
Cardiac	Follow-up echocardiogram	Frequency per cardiologist or approximately every 5 yrs
Dental	Follow-up eval w/dentist	Annually or as needed

Agents/Circumstances to Avoid

Activities with a high impact on joints (e.g., jogging) should be avoided.

Obesity, which places an excessive load on the large weight-bearing joints, should be avoided.

Evaluation of Relatives at Risk

See Genetic Counseling for issues related to testing of at-risk relatives for genetic counseling purposes.

Therapies Under Investigation

Search ClinicalTrials.gov in the US and EU Clinical Trials Register in Europe for information on clinical studies for a wide range of diseases and conditions. Note: There may not be clinical trials for this disorder.

Genetic Counseling

Genetic counseling is the process of providing individuals and families with information on the nature, mode(s) of inheritance, and implications of genetic disorders to help them make informed medical and personal decisions. The following section deals with genetic risk assessment and the use of family history and genetic testing to clarify genetic status for family members; it is not meant to address all personal, cultural, or ethical issues that may arise or to substitute for consultation with a genetics professional. —ED.

Mode of Inheritance

Chondrodysplasia with congenital joint dislocations, *CHST3*-related (CDCJD-*CHST3*) is inherited in an autosomal recessive manner.

Risk to Family Members

Parents of a proband

- The parents of an affected child are presumed to be heterozygous for a *CHST3* pathogenic variant.
- Molecular genetic testing is recommended for the parents of the proband to confirm that both parents are heterozygous for a *CHST3* pathogenic variant and to allow reliable recurrence risk assessment.
- If a pathogenic variant is detected in only one parent and parental identity testing has confirmed biological maternity and paternity, it is possible that one of the pathogenic variants identified in the proband occurred as a *de novo* event in the proband or as a postzygotic *de novo* event in a mosaic parent [Jónsson et al 2017]. If the proband appears to have homozygous pathogenic variants (i.e., the same two pathogenic variants), additional possibilities to consider include:
  - A single- or multiexon deletion in the proband that was not detected by sequence analysis and that resulted in the artifactual appearance of homozygosity;
  - Uniparental isodisomy for the parental chromosome with the pathogenic variant that resulted in homozygosity for the pathogenic variant in the proband.
- Heterozygotes (carriers) are asymptomatic. There is no evidence that they are at increased risk for degenerative joint disease.

Sibs of a proband

- If both parents are known to be heterozygous for a *CHST3* pathogenic variant, each sib of an affected individual has at conception a 25% chance of being affected, a 50% chance of being an asymptomatic carrier, and a 25% chance of being unaffected and not a carrier.
- Heterozygotes (carriers) are asymptomatic and are not at risk of developing CDCJD-*CHST3*.

Offspring of a proband. Unless an affected individual's reproductive partner also has CDCJD-*CHST3* or is a carrier, offspring will be obligate heterozygotes (carriers) for a pathogenic variant in *CHST3*.

Other family members. Each sib of the proband's parents is at 50% risk of being a carrier of a *CHST3* pathogenic variant.

Carrier Detection

Carrier testing for at-risk relatives requires prior identification of the *CHST3* pathogenic variants in the family.

Related Genetic Counseling Issues

Family planning

- The optimal time for determination of genetic risk and discussion of the availability of prenatal/preimplantation genetic testing is before pregnancy.
- It is appropriate to offer genetic counseling (including discussion of potential risks to offspring and reproductive options) to young adults who are affected, are carriers, or are at risk of being carriers.
- Carrier testing should be considered for the reproductive partners of known carriers and for the reproductive partners of individuals affected with CDCJD-*CHST3*, particularly if consanguinity is likely and/or both partners are of the same ancestry. A founder variant has been identified in the Amish community (see Table 6).

Prenatal Testing and Preimplantation Genetic Testing

Once the *CHST3* pathogenic variants have been identified in an affected family member, prenatal and preimplantation genetic testing for CDCJD-*CHST3* is possible.

Differences in perspective may exist among medical professionals and within families regarding the use of prenatal and preimplantation genetic testing. While most centers would consider use of prenatal and preimplantation genetic testing to be a personal decision, discussion of these issues may be helpful.

Resources

GeneReviews staff has selected the following disease-specific and/or umbrella support organizations and/or registries for the benefit of individuals with this disorder and their families. GeneReviews is not responsible for the information provided by other organizations. For information on selection criteria, click here.

- **UCLA International Skeletal Dysplasia Registry (ISDR)**
  Phone: 310-825-8998
  International Skeletal Dysplasia Registry

Molecular Genetics

Information in the Molecular Genetics and OMIM tables may differ from that elsewhere in the GeneReview: tables may contain more recent information. —ED.

Table A. Chondrodysplasia with Congenital Joint Dislocations, CHST3-Related: Genes and Databases

Gene	Chromosome Locus	Protein	Locus-Specific Databases	HGMD	ClinVar
CHST3	10q22.1	Carbohydrate sulfotransferase 3	CHST3 @ LOVD	CHST3	CHST3

Data are compiled from the following standard references: gene from HGNC; chromosome locus from OMIM; protein from UniProt. For a description of databases (Locus Specific, HGMD, ClinVar) to which links are provided, click here.

Table B. OMIM Entries for Chondrodysplasia with Congenital Joint Dislocations, CHST3-Related (View All in OMIM)

143095	SPONDYLOEPIPHYSEAL DYSPLASIA WITH CONGENITAL JOINT DISLOCATIONS; SEDCJD
603799	CARBOHYDRATE SULFOTRANSFERASE 3; CHST3

Molecular Pathogenesis

CHST3 encodes carbohydrate sulfotransferase 3, the enzyme responsible for the transfer of sulfate from PAPS to position 6 of N-acetyl galactosamine. Proper sulfation of the chondroitin sulfate proteoglycans is essential for normal cartilage structure.

Sulfation studies as well as the nature of the known pathogenic variants and the mode of inheritance suggest that the pathogenesis of the disorder results from decreased/absent catalytic activity of the enzyme. No hot spots have been identified, but the majority of known pathogenic variants are clustered in the sulfotransferase domain.

Mechanism of disease causation. Loss of function

Table 6. *CHST3* Pathogenic Variants Referenced in This *GeneReview*

Reference Sequences	DNA Nucleotide Change	Predicted Protein Change	Comment [Reference]
NM_004273.5 NP_004264.2	c.1298C>T	p.Pro433Leu	Founder variant in Amish community [Puffenberger 2021]

Variants listed in the table have been provided by the authors. *GeneReviews* staff have not independently verified the classification of variants.
GeneReviews follows the standard naming conventions of the Human Genome Variation Society (varnomen.hgvs.org). See Quick Reference for an explanation of nomenclature.

Chapter Notes

Revision History

- 1 August 2024 (sw) Comprehensive update posted live
- 31 January 2019 (sw) Comprehensive update posted live
- 1 September 2011 (me) Review posted live
- 28 March 2011 (asf) Original submission

References

Literature Cited

Cartault F, Munier P, Jacquemont M-L, Vellayoudom J, Doray B, Payet C, Randrianaivo H, Laville J-M, Munnich A, Cormier-Daire V. Expanding the clinical spectrum of B4GALT7 deficiency: homozygous p.R270C mutation with founder effect causes Larsen of Reunion Island syndrome. Eur J Hum Genet. 2015;23:49–53. PubMed PMID: 24755949.

Hall BD. Humero-spinal dysostosis: report of the fourth case with emphasis on generalized skeletal involvement, abnormal craniofacial features, and mitral valve thickening. J Pediatr Orthop B. 1997;6:11–4. PubMed PMID: 9039660.

Hermanns P, Unger S, Rossi A, Perez-Aytes A, Cortina H, Bonafé L, Boccone L, Setzu V, Dutoit M, Sangiorgi L, Pecora F, Reicherter K, Nishimura G, Spranger J, Zabel B, Superti-Furga A. Congenital joint dislocations caused by carbohydrate sulfotransferase 3 deficiency in recessive Larsen syndrome and humero-spinal dysostosis. Am J Hum Genet. 2008;82:1368–74. PubMed PMID: 18513679.

Jónsson H, Sulem P, Kehr B, Kristmundsdottir S, Zink F, Hjartarson E, Hardarson MT, Hjorleifsson KE, Eggertsson HP, Gudjonsson SA, Ward LD, Arnadottir GA, Helgason EA, Helgason H, Gylfason A, Jonasdottir A, Jonasdottir A, Rafnar T, Frigge M, Stacey SN, Th Magnusson O, Thorsteinsdottir U, Masson G,

Kong A, Halldorsson BV, Helgason A, Gudbjartsson DF, Stefansson K. Parental influence on human germline de novo mutations in 1,548 trios from Iceland. Nature. 2017;549:519-22. PubMed PMID: 28959963.

Kausar M, Ain NU, Hayat F, Fatima H, Azim S, Ullah H, Mushtaq M, Khalid S, Hussain S, Naz S, Janjua J, Amjad SB, Baig RM, Makitie O, Qamar R, Ikegawa S, Gen N, Khor CC, Foo JN, Siddiqi S. Biallelic variants in CHST3 cause Spondyloepiphyseal dysplasia with joint dislocations in three Pakistani kindreds. BMC Musculoskelet Disord. 2022;23:818. PubMed PMID: 36042462.

Kozlowski KS, Celermajer JM, Tink AR. Humero-spinal dysostosis with congenital heart disease. Am J Dis Child. 1974;127:407–10. PubMed PMID: 4814886.

Mégarbané A, Ghanem I. A newly recognized chondrodysplasia with multiple dislocations. Am J Med Genet A. 2004;130A:107–9. PubMed PMID: 15368507.

Muys J, Blaumeiser B, Jacquemyn Y, Janssens K. Prenatal homozygosity mapping detects a novel mutation in CHST3 in a fetus with skeletal dysplasia and joint dislocations. Clin Case Rep. 2017;5:440–5. PubMed PMID: 28396765.

Otaify GA, Elhossini RM, Abdel-Ghafar SF, Sayed IM, Abdel-Salam GMH, Aglan MS, Abdel-Hamid MS. CHST3-related skeletal dysplasia in 14 patients: identification of 8 novel variants and further expansion of the phenotypic spectrum. : Am J Med Genet A. 2023;191:2100-12. PubMed PMID: 37183573.

Puffenberger EG. Mendelian disease research in the Plain populations of Lancaster County, Pennsylvania. Am J Med Genet A. 2021;185:3322-33. PubMed PMID: 34532947.

Rajab A, Kunze J, Mundlos S. Spondyloepiphyseal dysplasia Omani type: a new recessive type of SED with progressive spinal involvement. Am J Med Genet A. 2004;126A:413–9. PubMed PMID: 15098240.

Ranza E, Huber C, Levin N, Baujat G, Boyle-Feysot C, Nitschke P, Masson C, Alanay Y, Al-Gazali L, Bitoun P, Boute O, Campeau P, Coubes C, McEntagart M, Elcioglu N, Faivre L, Gezdirici A, Johnson D, Mihci E, Nur BG, Perrin L, Quelin C, Terhal P, Tuysuz B, Cormier-Daire V. Chondrodysplasia with multiple dislocations: comprehensive study of a series of 30 cases. Clin Genet. 2017;91:868–80. PubMed PMID: 28229453.

Richards S, Aziz N, Bale S, Bick D, Das S, Gastier-Foster J, Grody WW, Hegde M, Lyon E, Spector E, Voelkerding K, Rehm HL; ACMG Laboratory Quality Assurance Committee. Standards and guidelines for the interpretation of sequence variants: a joint consensus recommendation of the American College of Medical Genetics and Genomics and the Association for Molecular Pathology. Genet Med. 2015;17:405-24. PubMed PMID: 25741868.

Searle C, Jewell R, Kraft J, Stoebe P, Chumas P, Titheradge H, Kraus A, Gencik M, Hobson E. Craniosynostosis: a previously unreported association with CHST3-related skeletal dysplasia (autosomal recessive Larsen syndrome). Clin Dysmorphol. 2014;23:12–5. PubMed PMID: 24300290.

Singh S, Jacob P, Patil SJ, Muranjan M, Shah H, Girisha KM, Bhavani GS. Indian patients with CHST3-related chondrodysplasia with congenital joint dislocations: Am J Med Genet A. 2024; 194:e63422 PubMed PMID: 37876363.

Srivastava P, Pandey H, Agarwal D, Mandal K, Phadke SR. Spondyloepiphyseal dysplasia Omani type: CHST3 mutation spectrum and phenotypes in three Indian families. Am J Med Genet A. 2017;173:163–8. PubMed PMID: 27753269.

Thiele H, Sakano M, Kitagawa H, Sugahara K, Rajab A, Höhne W, Ritter H, Leschik G, Nürnberg P, Mundlos S. Loss of chondroitin 6-O-sulfotransferase-1 function results in severe human chondrodysplasia with progressive spinal involvement. Proc Natl Acad Sci U S A. 2004;101:10155–60. PubMed PMID: 15215498.

Tuysuz B, Mizumoto S, Sugahara K, Celebi A, Mundlos S, Turkmen S. Omani-type spondyloepiphyseal dysplasia with cardiac involvement caused by a missense mutation in CHST3. Clin Genet. 2009;75:375–83. PubMed PMID: 19320654.

Unger S, Ferreira CR, Mortier GR, Ali H, Bertola DR, Calder A, Cohn DH, Cormier-Daire V, Girisha KM, Hall C, Krakow D, Makitie O, Mundlos S, Nishimura G, Robertson SP, Savarirayan R, Sillence D, Simon M, Sutton VR, Warman ML, Superti-Furga A. Nosology of genetic skeletal disorders: 2023 revision. Am J Med Genet A. 2023;191:1164-209. PubMed PMID: 36779427.

Unger S, Lausch E, Rossi A, Mégarbané A, Sillence D, Alcausin M, Aytes A, Mendoza-Londono R, Nampoothiri S, Afroze B, Hall B, Lo IF, Lam ST, Hoefele J, Rost I, Wakeling E, Mangold E, Godbole K, Vatanavicharn N, Franco LM, Chandler K, Hollander S, Velten T, Reicherter K, Spranger J, Robertson S, Bonafé L, Zabel B, Superti-Furga A. Phenotypic features of carbohydrate sulfotransferase 3 (CHST3) deficiency in 24 patients: congenital dislocations and vertebral changes as principal diagnostic features. Am J Med Genet A. 2010;152A:2543–9. PubMed PMID: 20830804.

van Roij MH, Mizumoto S, Yamada S, Morgan T, Tan-Sindhunata MB, Meijers-Heijboer H, Verbeke JI, Markie D, Sugahara K, Robertson SP. Spondyloepiphyseal dysplasia, Omani type: further definition of the phenotype. Am J Med Genet A. 2008;146A:2376–84. PubMed PMID: 18698629.

Waryah AM, Shahzad M, Shaikh H, Sheikh SA, Channa NA, Hufnagel RB, Makhdoom A, Riazuddin S, Ahmed ZM. A novel CHST3 allele associated with spondyloepiphyseal dysplasia and hearing loss in Pakistani kindred. Clin Genet. 2016;90:90–5. PubMed PMID: 26572954.

License

GeneReviews® chapters are owned by the University of Washington. Permission is hereby granted to reproduce, distribute, and translate copies of content materials for noncommercial research purposes only, provided that (i) credit for source (http://www.genereviews.org/) and copyright (© 1993-2024 University of Washington) are included with each copy; (ii) a link to the original material is provided whenever the material is published elsewhere on the Web; and (iii) reproducers, distributors, and/or translators comply with the GeneReviews® Copyright Notice and Usage Disclaimer. No further modifications are allowed. For clarity, excerpts of GeneReviews chapters for use in lab reports and clinic notes are a permitted use.

For more information, see the GeneReviews® Copyright Notice and Usage Disclaimer.

For questions regarding permissions or whether a specified use is allowed, contact: admasst@uw.edu.